

## Surgical Treatment of Craniofacial Fibrous Dysplasia in Adults

Christian A. Bowers, M.D., Philipp Taussky, M.D., and William T. Couldwell, M.D., Ph.D.

Department of Neurosurgery, Clinical Neurosciences Center, University of Utah, Salt Lake City,  
Utah

**Corresponding author:** William T. Couldwell, M.D., Ph.D.

Department of Neurosurgery

University of Utah

175 N. Medical Drive East

Salt Lake City, UT 84132

Phone: 801-581-6908

Fax: 801-581-4138

Email: [neuropub@hsc.utah.edu](mailto:neuropub@hsc.utah.edu)

## Abstract

Craniofacial fibrous dysplasia is a rare disorder that may require neurosurgical expertise for definitive management; however, surgical management of FD in adult patients is uncommon. Although other therapies have been shown to slow progression, the only definitive cure for adult craniofacial FD is complete resection with subsequent reconstruction. The authors review the biological, epidemiologic, clinical, genetic, and radiographic characteristics of adult FD, with an emphasis on surgical management of FD. They present a small series of three adult patients with complex FD that highlights the surgical complexity required in some adult patients with FD. Because of the complex nature of these adult polyostotic craniofacial cases, the authors used neurosurgical techniques specific to the different surgical indications, including a transsphenoidal approach for resection of sphenoidal sinus FD, a transmaxillary approach to decompress the maxillary branch of the trigeminal nerve with widening of the foramen rotundum, and complete calvarial craniectomy with cranioplasty reconstruction. These cases exemplify the diverse range of skull-base techniques required in the spectrum of surgical management of adult FD and demonstrate that novel variations on standard neurosurgical approaches to the skull base can provide successful outcomes with minimal complications in adults with complex craniofacial FD.

**Running Title:** Surgery for complex craniofacial fibrous dysplasia

**Keywords:** craniofacial; fibrous dysplasia; surgical treatment

## Introduction

Fibrous dysplasia (FD) is a progressive, benign bone disorder in which normal cancellous bone is replaced by fibro-osseous tissue that is composed of poorly organized woven bone [12]. This abnormal bone is produced by functionally impaired osteoblasts that are unable to produce normal cancellous bone and instead produce disorganized abnormal woven bone that can progressively enlarge [6]. This progressive growth can cause swelling, cosmetic deformity, and pain. Chemotherapy and radiation are not effective treatments, and radiation predisposes patients to higher rates of malignant transformation [15,18]. The only definitive cure for craniofacial FD is complete resection with subsequent reconstruction [17]. Surgical management of craniofacial FD in children has been well described throughout the years; however, treatment of FD in adults has been less well documented. Depending on the location of the FD lesion, care of these patients may be handled by any of multiple different specialists, including neurosurgeons, ophthalmologists, otolaryngologists, plastic surgeons, and oral maxillofacial surgeons. With the many different specialists involved in treating FD, there are no definitively accepted universal treatment guidelines. We present and discuss our experience in complex adult craniofacial FD cases to highlight the potential surgical complexity and surgical strategies used in cases of adult craniofacial FD.

## Case Descriptions

### *Case 1*

A 40-year-old man with a complicated history of skull base FD, including 3 previous skull base resections, most recently 10 years earlier, presented for evaluation. Repeat imaging showed that his FD lesion had progressed marginally over the previous 10 years. The

ophthalmologist noted that the patient's right eye vision was largely unchanged for the previous 20 years, although he was blind in his left eye. He had previously undergone optic nerve decompression. He was monitored conservatively by the ophthalmologist for the next 8 years until he demonstrated increasing visual field deficit and loss of visual acuity. He also complained of worsened nasal obstruction that made it difficult for him to breathe, especially when sleeping (Figure 1). The patient was referred to our department for surgical evaluation.

Because of the patient's dual symptoms of increasing visual deficit and nasal obstruction, the decision was made to undertake a two-stage procedure for treatment of symptoms. The first phase consisted of a transnasal approach and removal of the intranasal, medial maxillary, and sphenoid FD. This was thought to be the best approach to ensure the greatest relief of his nasal obstruction and difficulty breathing. Surgery was performed using stereotactic image guidance to avoid injury to the carotid artery (Stealth; Medtronic, Minneapolis, MN). Two days later, the patient underwent the definitive FD surgery via a right frontotemporal craniotomy, and the optic nerve was decompressed intra- and extradurally. This also involved removal of much of the superior and lateral involved bone of the right orbit.

Postoperatively, the patient's vision improved slightly; however, one year later, his difficulty breathing from his right nostril persisted, and he underwent a more extensive resection of his endonasal FD as far posteriorly and superiorly as the sphenoid sinus. This resection was performed using a transsphenoidal approach for removal of recurrent sphenoidal sinus FD at the same time. After this surgery, the patient's breathing returned to normal, and he has been stable for the four years since the operation. Follow-up imaging has demonstrated no further progression of his involved bone.

### *Case 2*

A 21-year-old woman with a one-year history of multiple sinus infections treated with antibiotic medications had a non-contrasted head computed tomography (CT) scan after a mild head trauma and a complaint of headaches. The CT scan showed a sphenoid mass consistent with FD. Magnetic resonance (MR) imaging performed 6 months later showed interval growth of the lesion, and the patient also reported some peripheral vision loss in her right eye. She was referred for neurosurgical consultation at that time.

On examination, the patient had a temporal field cut in her right eye. She underwent bifrontal craniotomy with bilateral intradural anterior clinoidectomy, bilateral optic nerve decompression, and frontal sinus cranialization. The patient did well postoperatively, but over the course of the next year she developed right-sided pain and paresthesias in the distribution of the maxillary branch of the trigeminal nerve. Neuroimaging demonstrated some mild growth of the FD lesion. To treat her V2 facial pain, we performed a transmaxillary approach to the pterygopalatine fossa. The maxillary branch of the trigeminal nerve was traced back to the foramen rotundum and was decompressed along its entire course, and the foramen rotundum was widened (Figure 2). The patient did well postoperatively, with resolution of her symptoms. Three years later, the patient had a recurrent right-sided field cut that developed during a pregnancy. Neuroimaging demonstrated the first documented case of acute cystic degeneration occurring during a pregnancy.[2] After the patient delivered, she was taken to the operating room for a revision bifrontal craniotomy and bilateral optic nerve decompression, which resulted in a complete resolution of her symptoms.

### *Case 3*

A 42-year-old man presented with known FD and progressively increasing headaches that were refractory to medical management. This was an extreme case of childhood FD, but the patient was not treated as an adolescent because of the extent of disease and risks of surgery. The patient had suffered cosmetically from an obvious skull deformity since the age of 12 years. At the time of presentation, the severity of his refractory headaches had increased. Funduscopic examination demonstrated some blurring of his optic discs. It was determined that the likely source of headaches and raised intracranial pressure was severe skull thickening resulting in diminution of the supratentorial cranial volume. The patient's disease was diffuse enough that almost the entire supratentorial calvaria was involved, with particular thickening of the frontal bones bilaterally (Figure 3A–C). To treat this extensive involvement, the patient underwent a complete calvarial craniectomy, including an orbital rim osteotomy. Given the thickness of the frontal region, the involved bone was reduced in thickness by extensive drilling and removed by use of a craniotome. A complete craniectomy of the frontal, parietal, temporal, and superior occipital bones was done (Figure 3D). This procedure was complicated by extensive blood loss (3 L). A custom implant cranioplasty (Medpor; Porex Corporation, Fairburn, Georgia) was performed as a second-stage procedure three weeks later. The patient subsequently had no further headaches and had an excellent cosmetic result (Figure 4).

## Discussion

### *Biology, Epidemiology, Clinical Behavior, and Medical Treatment*

FD is an uncommon disease that comprises 2.5% of all bone tumors and 7.5% of all benign bone neoplasms [18]. FD can occur in any bone of the body and occurs in monostotic (one bone) or polyostotic (>1 bone) forms, with the monostotic form occurring in 70% of cases

throughout the body [1]. In contrast, the polyostotic form comprises 71–91% of cases of craniofacial FD [6]. The skull and facial bones are affected in approximately 10% of monostotic cases and 50–100% of polyostotic FD cases. Skull FD can affect any bone in the skull, but it most commonly affects the frontal bones, followed by the sphenoid, parietal, ethmoid, temporal, frontal, and occipital bones [15,18].

Polyostotic FD may be part of Jaffe-Lichtenstein Syndrome (JLS) or McCune-Albright syndrome (MAS); JLS consists of café-au-lait lesions and polyostotic FD, while MAS combines the JLS features with hyperfunctioning endocrinopathies [6]. Monostotic craniofacial FD growth usually stops in adolescence whereas polyostotic craniofacial FD (including MAS variants) often continue growing past adolescence [10]. Polyostotic FD growth that continues past adolescence typically stops at some point, unless it is a MAS variant, in which case growth may continue indefinitely [7]. One source of confusion regarding growth rates of polyostotic craniofacial FD is that in previous reports, MAS variants with their continual growth that does not arrest, may have been classified with the non-MAS polyostotic patients that typically have growth arrest after adolescence [7]. Thus, overall growth rates and the period at which growth arrest occurs in polyostotic craniofacial FD may have been falsely overstated in the older literature [10].

The presenting symptom in craniofacial FD is usually painless mass growth but other potential symptoms include proptosis, facial pain, vertigo, facial asymmetry, cranial nerve dysfunction, sinus infections/inflammation, headache, visual or auditory impairment, visual disturbances, and other variable symptoms depending on which bones the craniofacial FD is affecting [6,18]. Kelly et al. [8] showed that, for all types of FD, adult patients experience pain as a symptom more commonly than pediatric patients do, although patients with craniofacial FD experienced pain <50% of the time. The 20% of patients who took bisphosphonates experienced

75% improvement in symptoms [8,13]; however, the literature overall is mixed on the effectiveness of bisphosphonates since the patient populations are usually heterogenous. The development of definitive guidelines will require further studies including only adult craniofacial FD patients. The same question of effectiveness is true with regards to oral pain medication for painful craniofacial FD; nonsteroidal anti-inflammatory medications combined with narcotics have been tried in some patients, but no clear conclusions have been drawn [13]. Malignant transformation is exceedingly rare (0.05%) and is usually associated with prior radiation, but when it occurs, the pathology is usually osteosarcoma, fibrosarcoma, or chondrosarcoma [1,6]..

### *Genetics*

The genetic cause of FD is a non-inherited mutation of a protein product of the *GNAS1* gene, whose abnormal protein product leads to an uninhibited stimulatory G protein signaling cascade through inhibition of the cell's natural self-regulating inhibitory mechanism [12]. This cell signaling alteration leads to a cytokine overproduction, especially of IL-6, which causes increased osteoclast gathering and bone resorption [9]. This same mechanism also leads to abnormal signaling that causes the poorly made woven bone to be resorbed with increased frequency and subsequently re-mineralized in a weaker fashion [6]. Novel genetic studies have provided genetic evidence behind the long-noted clinical observation that eventually most FD lesions stop growing [11]. These studies have shown that as FD lesions age, more of their mutated stem cells fail to regenerate and their previous offspring die by apoptosis [11]. This leads to normal bone cells increasing in population and allows for more normal skeleton to be produced [11]. This explains why lesions typically stop progressing with puberty.



### *Adult vs. Pediatric Craniofacial FD*

The biggest difference between adult and pediatric craniofacial FD is that the clinical course in adult patients is harder to predict. Growth arrest, which occurs in most patients, for all types of fibrous dysplasia is thought to occur around 15 years of age [7]. Since most patients with monostotic craniofacial FD reach growth arrest before adulthood, less is known about growth cessation in symptomatic adult craniofacial FD patients [10]. In fact, one study highlighted that 90% of patients with polyostotic and MAS craniofacial FD presented by the age of 3.4 years, and no cases were reported after age 10 [7,8]. Since polyostotic and MAS craniofacial FD can continue to grow for some period into adulthood before growth arrest occurs, symptomatic adult patients will be more likely to benefit from aggressive surgery than their pediatric counterparts who may be best managed by conservative measures or less invasive surgeries such as bone shaving until growth arrest occurs during adolescence [10]. Much of the literature containing series of craniofacial FD patients consists combined pediatric and adult craniofacial FD cases [5,7,10,14,17,18] and in only a couple instances are the patients listed individually [15,19], so it is difficult to gather a large size of data only on adult craniofacial FD cases.

### *Radiology*

Craniofacial FD has a variety of radiological manifestations, but the three key characteristics seen on CT imaging are the classic expanded “ground glass” bone (the most common), homogeneously dense bone, or cystic bone [3]. In FD, the CT appearance is related to the age of the lesion, with the younger lesions appearing more radiolucent and a mixed radiolucent/radiopaque image seen in more mature lesions. The classic “ground-glass”

appearance is seen with established lesions [6]. Usually the diagnosis is straightforward with CT imaging; however, MRI imaging is often initially obtained with skull-based lesions, and FD of the skull base can be a much more difficult diagnosis because the appearance can be similar to that of a skull base tumor [3]. The T1 and T2 MRI signals can be variable, but the T1 signal is usually of low to intermediate intensity [3]. The signal variability is based on the ratio of fibrous tissue to mineralized bone [3]. Fibrous tissue is well-vascularized and will avidly enhance when contrast is administered [3]. FD cases with low T1 and T2 signal intensities that avidly enhance with gadolinium are easier to diagnose on MRI [3]. The less conspicuous MRI features in diagnosing FD are intermediate T1 signal intensity with high T2 signal intensity [3]. These more difficult radiological presentations can be clarified by comparing with subsequent CT imaging.

### *Surgical Treatment*

Although specialists in many fields may be involved in the care of patients with craniofacial FD, no definitive treatment guidelines have been described. In part this may result from the heterogeneous presentations of affected patients. Because complete resection with subsequent reconstruction is the only definitive treatment for craniofacial FD [17], neurosurgeons are often involved in the management of the most complex craniofacial cases where the skull base is involved. The primary surgical indications are relief of pain, decompression of symptomatic optic neuropathy, and to correct undesirable cosmesis [14,18]. A large cross-sectional analysis of a case-control cohort demonstrated that prophylactic optic nerve decompression should not be performed based strictly on the radiographic measurements of the degree of FD because optic nerve encasement did not correlate with clinical vision loss [12]. Prophylactic optic nerve decompression is not without significant complication rates, and it

should be avoided unless another primary anterior skull base lesion requires surgery and provides the opportunity to simultaneously perform the decompression [16]. In cases in which there is documented vision loss, therapeutic optic nerve decompression does not guarantee vision improvement but is indicated in an attempt to stop further optic nerve compression and damage [16]. Various surgical options have been employed with craniofacial FD, including partial resection, wide excision, total resection, newer minimally invasive approaches, or shaving/debulking [12]. Surgical treatment is dictated by the size and location of the lesion in addition to other factors [10,12]. More aggressive resection and reconstruction may be warranted earlier in polyostotic FD since growth arrest typically occurs at a later age [10]. Even with resection and reconstruction, the largest published study of surgically treated craniofacial FD showed a 13.7% recurrence rate, with a direct relationship between surgical margin and recurrence [14,18].

Surgical strategies can include a large frontal craniotomy for frontal/ocular disease, nasal approaches for ethmoid/maxillary/ocular disease, and subcranial approaches for sphenoid/skull base disease [18]. Endoscopic techniques have also been successfully employed for maxillary, nasal, sphenoid, clival and ocular FD involvement [18]. When patients present with involvement of multiple areas or symptoms of vision impairment or compressive cranial neuropathy, as in our patients, the complexity of the cases may require the surgeon to undertake unique surgical strategies.

Patient 1 had the common FD surgical indication of worsening vision caused by optic nerve compression; however, this patient also had severe involvement of the nasopharynx and paranasal sinuses, which caused him extreme difficulty breathing. In addition to a frontotemporal craniotomy for decompression of the optic nerve for progressive visual decline, two subsequent

surgeries were required to remove bulky FD from the nasopharynx and the ethmoid and sphenoid sinuses, which allowed the patient to resume breathing without difficulty. This particular patient had three surgeries performed by our team and three done more than 20 years earlier, which demonstrates how difficult it can be to manage extremely complex cases of FD.

Patient 2 also required multiple surgeries to treat a complex presentation of her disease. Initially, she had surgery for standard optic nerve decompression for visual deterioration from FD compression. She then presented with a new complaint of right maxillary (V2) nerve pain. Her pain was refractory to over-the-counter pain medications. To address this, the patient underwent a transmaxillary approach to the central skull base with a maxillary (V2) decompression and widening of the foramen rotundum to relieve FD maxillary compression. This approach has been previously described by the senior author for other indications[4].

The third patient reported herein underwent complete supratentorial calvarial removal of extensive FD with subsequent cranial vault reconstruction, which resulted in increasing his supratentorial cranial volume and relieving the increased intracranial pressure that had been causing his headaches. The surgical indication was progressive headaches, which is a common symptom of craniofacial FD [18], but headaches in this case resulted from increased intracranial pressure. Although this is a large and complex surgery, it provided a definitive treatment of the patient's medically refractory headaches. It is important to note that this procedure was complicated by significant blood loss (3 L). Removal of the bone required extensive thinning with a drill; the thickness of the bone exceeded the depth of the craniotome and thus a conventional drill was used for thinning. Bleeding from these cases is constant, and monopolar cautery is used to help reduce this; however, with the extent of this disease, this amount of blood loss was inevitable. Profuse bleeding was encountered as well when the calvarial bone was

stripped from the dura, and the dura was immediately covered with collagen sponge to reduce this.

### **Conclusion**

Craniofacial FD is an entity that is treated by a variety of different specialists, and consequently uniform treatment strategies have not been established. Generally, surgical indications include symptomatic optic nerve compression, undesirable cosmetic features, pain, and other cranial neuropathy. Neurosurgeons are often called upon to treat FD that requires complex skull base and other cranial surgeries and must be innovative and adaptive in tailoring the best surgical treatment to relieve the patient's symptoms. Our examples of complex adult craniofacial FD cases and review of unusual surgical techniques in craniofacial FD management demonstrate how complex craniofacial FD may require innovative and complex surgical management.

### **Acknowledgments**

We thank Kristin Kraus, M.Sc., for editorial assistance and Jennie Swensen, M.A., for illustrations.

## References

1. Atalar M, Ozum U (2010) Monostotic fibrous dysplasia of the clivus: imaging findings. *Turk Neurosurg* 20:77-81
2. Bowers CA, Altay T, Shah L, Couldwell WT (2012) Pregnancy-induced Cystic Degeneration of Fibrous Dysplasia. *Can J Neurol Sci* 39:828-829
3. Chong VF, Khoo JB, Fan YF (2002) Fibrous dysplasia involving the base of the skull. *AJR Am J Roentgenol* 178:717-720
4. Couldwell WT, Sabit I, Weiss MH, Giannotta SL, Rice D (1997) Transmaxillary approach to the anterior cavernous sinus: a microanatomic study. *Neurosurgery* 40:1307-1311
5. Davies ML, Macpherson P (1991) Fibrous dysplasia of the skull: disease activity in relation to age. *Br J Radiol* 64:576-579
6. Feller L, Wood NH, Khammissa RA, Lemmer J, Raubenheimer EJ (2009) The nature of fibrous dysplasia. *Head Face Med* 5:22
7. Hart ES, Kelly MH, Brillante B, Chen CC, Ziran N, Lee JS, Feuillan P, Leet AI, Kushner H, Robey PG, Collins MT (2007) Onset, progression, and plateau of skeletal lesions in fibrous dysplasia and the relationship to functional outcome. *J Bone Miner Res* 22:1468-1474
8. Kelly MH, Brillante B, Collins MT (2008) Pain in fibrous dysplasia of bone: age-related changes and the anatomical distribution of skeletal lesions. *Osteoporos Int* 19:57-63
9. Kos M, Luczak K, Godzinski J, Klempous J (2004) Treatment of monostotic fibrous dysplasia with pamidronate. *J Craniomaxillofac Surg* 32:10-15
10. Kusano T, Hirabayashi S, Eguchi T, Sugawara Y (2009) Treatment strategies for fibrous dysplasia. *J Craniofac Surg* 20:768-770

11. Kuznetsov SA, Cherman N, Riminucci M, Collins MT, Robey PG, Bianco P (2008) Age-dependent demise of GNAS-mutated skeletal stem cells and "normalization" of fibrous dysplasia of bone. *J Bone Miner Res* 23:1731-1740
12. Lee JS, FitzGibbon E, Butman JA, Dufresne CR, Kushner H, Wientroub S, Robey PG, Collins MT (2002) Normal vision despite narrowing of the optic canal in fibrous dysplasia. *N Engl J Med* 347:1670-1676
13. Lee JS, FitzGibbon EJ, Chen YR, Kim HJ, Lustig LR, Akintoye SO, Collins MT, Kaban LB (2012) Clinical guidelines for the management of craniofacial fibrous dysplasia. *Orphanet J Rare Dis* 7 Suppl 1:S2
14. Lei P, Bai H, Wang Y, Liu Q (2009) Surgical treatment of skull fibrous dysplasia. *Surg Neurol* 72 Suppl 1:S17-20
15. Lustig LR, Holliday MJ, McCarthy EF, Nager GT (2001) Fibrous dysplasia involving the skull base and temporal bone. *Arch Otolaryngol Head Neck Surg* 127:1239-1247
16. Tan YC, Yu CC, Chang CN, Ma L, Chen YR (2007) Optic nerve compression in craniofacial fibrous dysplasia: the role and indications for decompression. *Plast Reconstr Surg* 120:1957-1962
17. Valentini V, Cassoni A, Marianetti TM, Terenzi V, Fadda MT, Iannetti G (2009) Craniomaxillofacial fibrous dysplasia: conservative treatment or radical surgery? A retrospective study on 68 patients. *Plast Reconstr Surg* 123:653-660
18. Wei YT, Jiang S, Cen Y (2010) Fibrous dysplasia of skull. *J Craniofac Surg* 21:538-542
19. Yetiser S, Gonul E, Tosun F, Tasar M, Hidir Y (2006) Monostotic craniofacial fibrous dysplasia: the Turkish experience. *J Craniofac Surg* 17:62-67



Figure 1: Axial non-enhanced head CT (A), coronal T2-weighted (B) and T1-weighted MR imaging without (C) and with (D) contrast enhancement showing extensive fibrous dysplasia involving the central skull base and nasopharynx causing nasal obstruction.

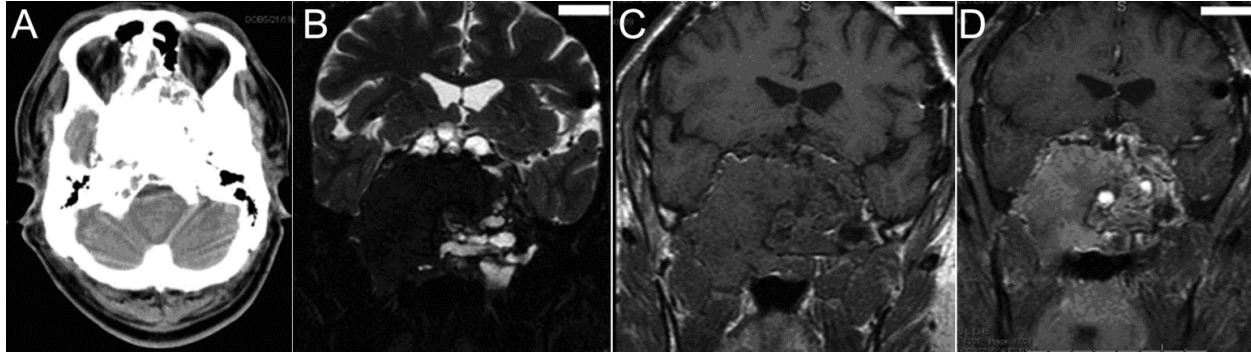


Figure 2: CT scans of young female patient with extensive sphenoid bone fibrous dysplasia. Note involvement of the entire sphenoid sinus (A). (B,C) CT scans obtained after transmaxillary approach for decompression of the right maxillary division of the trigeminal nerve for facial pain (arrow).

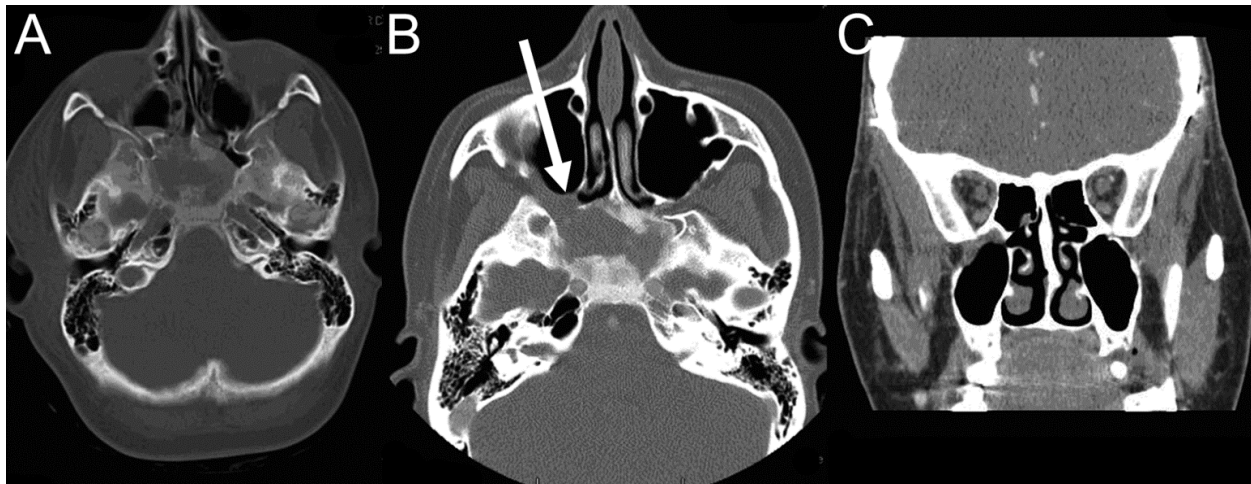


Figure 3: Preoperative axial magnetic resonance imaging of the brain with gadolinium enhancement (A) and axial noncontrasted computed tomography (bone windows) scan of the head (B) showing extensive frontal fibrous dysplasia. (C,D) Pre- and postoperative illustrations showing extensive involvement of the supratentorial calvaria before and complete calvarial



craniectomy and orbital rim osteotomy followed by calvarial reconstruction with custom cranioplasty.

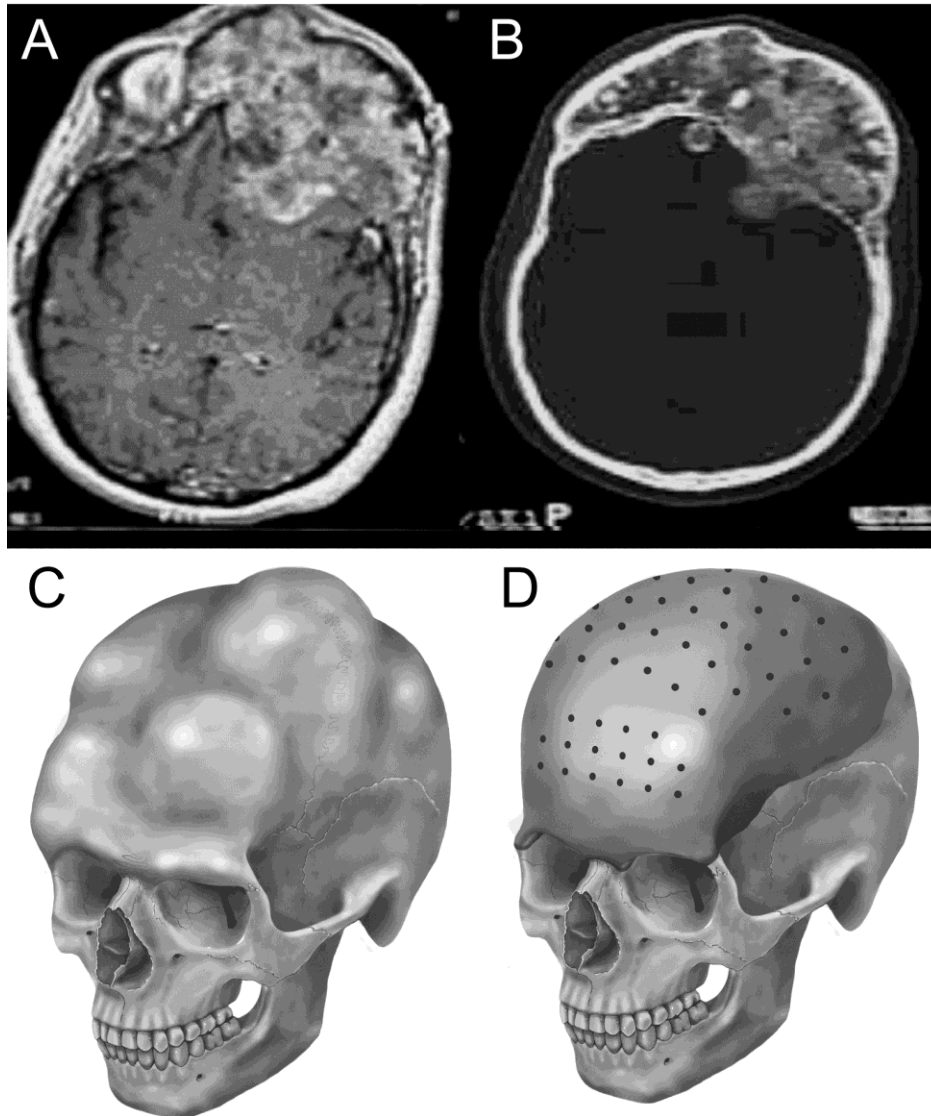


Figure 4. (A,B) Pre-operative operating room view of patient showing extensive involvement of the supratentorial calvaria. (C,D) Postoperative anterior and lateral photographs showing the calvarial reconstruction.

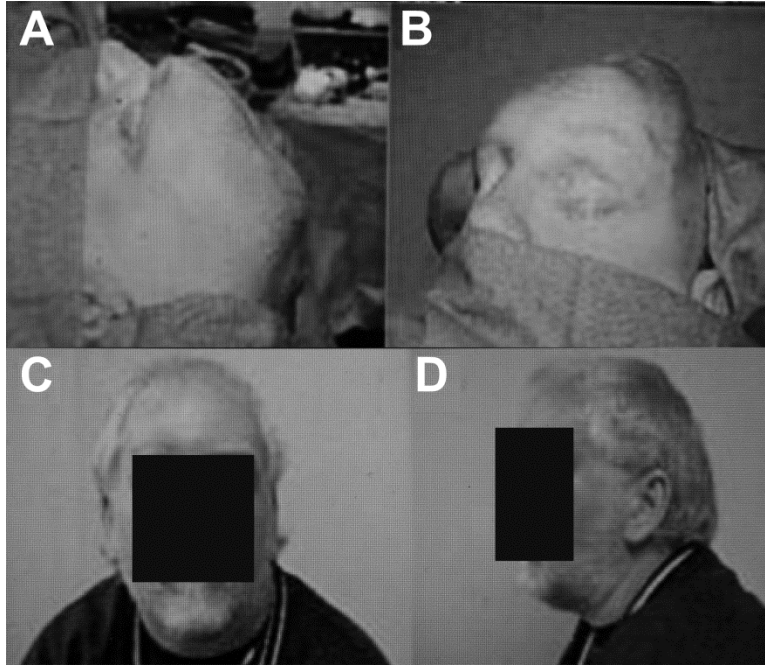

Table 1. Surgical data on three patients treated for complex craniofacial fibrous dysplasia

Case #	Sex	Age at presentation (years)	Surgical indications	Procedures
1	M	40	1. Nasal obstruction 2. Decreased visual field 3. Nasal obstruction	1. Trans-septal resection of intranasal, medial maxillary, and sphenoid fibrous dysplasia. 2. Frontal craniotomy for optic nerve decompression. 3. Endonasal and transsphenoidal resection of residual endonasal and sphenoid fibrous dysplasia.
2	F	21	1. Temporal visual field cut 2. Right facial pain (V2)	1. Bicoronal/bifrontal craniotomy, bilateral intradural anterior clinoidectomy, frontal sinus cranialization. 2. Fourteen months later, transmaxillary approach and foramen rotundum widening for V2 decompression
3	M	42	1. Headaches, raised intracranial pressure, and undesirable cosmesis	1. Complete calvarial craniectomy with staged custom cranioplasty