

# Pituitary gland metastasis from adenocarcinoma of the prostate

## Case report

WILLIAM T. COULDWELL, M.D., PARAKRAMA T. CHANDRASOMA, M.D., AND  
MARTIN H. WEISS, M.D.

*Department of Neurosurgery, University of Southern California School of Medicine, Los Angeles, California*

✓ A case of prostatic carcinoma metastasis to the pituitary gland is reported. The presentation and rarity of such a lesion is addressed. The literature review yielded only isolated case reports of symptomatic brain metastases unassociated with bone disease from adenocarcinoma of the prostate. The management options of such a lesion are discussed.

**KEY WORDS** • prostate • pituitary gland • adenocarcinoma • metastasis

**I**NTRACRANIAL metastasis from adenocarcinoma of the prostate is uncommon. Carcinoma of the prostate is the third leading cause of malignancy-related death in North American men. This malignancy has been found at autopsy in 70% of men over the age of 80 years,<sup>8</sup> and skeletal and pulmonary metastases predominate; intraparenchymal central nervous system metastases occur in only 0.6% to 4.4% of cases.<sup>5,6</sup> A case of prostate adenocarcinoma metastasis to the pituitary gland is presented. To our knowledge this is the first reported case of symptomatic pituitary metastasis unassociated with sellar osseous disease.

### Case Report

This 61-year-old right-handed man presented with a 2-month history of increasing bifrontal headache and peripheral visual loss. Ophthalmological evaluation revealed a marked bitemporal hemianopsia; subsequent computerized tomography (CT) and magnetic resonance imaging revealed a large sellar mass with suprasellar extension (Fig. 1). He was referred for neurosurgical evaluation. His medical history was remarkable for a transurethral resection of the prostate performed 2 years previously with reported benign pathology; the patient had no current urinary symptoms.

*Examination.* Physical examination disclosed a dense bitemporal hemianopsia, and a preoperative chest

x-ray film revealed extensive blastic lesions of multiple ribs, vertebrae, and the right humerus. Preoperative endocrine evaluation was normal, but the acid phosphatase level was noted to be markedly elevated at 209 U/liter (normal 1 to 8 U/liter). A preoperative diagnosis of metastatic carcinoma of the prostate was made; the relationship of the pituitary lesion to the prostatic primary site was uncertain. In consideration of the rarity of intracranial prostatic metastasis, it was believed that a primary pituitary process was not precluded.

*Operation.* In the face of a relentlessly progressive visual loss and the questionable pituitary pathology, the patient underwent urgent transsphenoidal craniotomy with resection of the sellar and suprasellar mass. Upon exposure of the sphenoid sinus and the sella, no evidence of bone or dural involvement by tumor was noted. A firm, white, rubbery lesion was encountered within the parenchyma of the pituitary extending into the suprasellar cistern. A gross total resection was accomplished. Pathological examination revealed adenocarcinoma compatible with a prostatic primary tumor (Fig. 2).

*Postoperative Course.* Postoperatively, the visual field defects improved markedly. The patient was discharged on the 6th postoperative day following bilateral orchiectomy for his Stage D metastatic disease. He is alive and neurologically asymptomatic 18 months following operation.

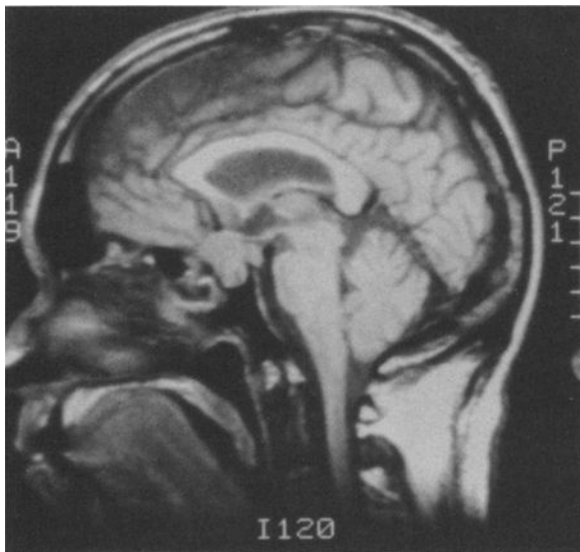


FIG. 1. Preoperative magnetic resonance image demonstrating a large sellar mass with suprasellar extension.

### Discussion

Classically, carcinoma of the prostate is associated with skeletal, pulmonary, and hepatic metastases.<sup>7</sup> Central nervous system involvement is most commonly secondary to epidural compression from overlying bone disease.<sup>9</sup> There are several potential modes of metastatic tumor spread: direct extension, lymphatic seeding, and vascular embolization (arterial and venous). The exact route involved in cerebral metastasis is at present controversial, and in fact may involve several mechanisms.

The paravertebral venous plexus has previously been elegantly demonstrated as a plausible route of metastatic spread of prostatic tumor.<sup>1</sup> During a Valsalva maneuver, blood flow is reversed from the inferior vena cava into the vertebral veins, and access is achieved to the skull base. In instances of transit through dural veins, subdural seeding is possible and contiguous spread through Virchow-Robin spaces allows intracerebral metastases to occur. Varkarakis, *et al.*,<sup>13</sup> however, invoked a multistep cascade process in the genesis of cerebral metastases, whereby pulmonary and bone involvement precede neural metastases. This has been advocated as the more common method of spread, supported clinically by the usual evidence of multiple-system involvement at the time of presentation of symptomatic cerebral metastasis. A contradiction is the solitary brain metastasis in the absence of other organ involvement, as reported by Smith, *et al.*<sup>12</sup>

While cerebral metastases are notably uncommon in prostatic carcinoma, initial presentation with brain metastasis is extremely rare.<sup>5,6,11</sup> The majority of these metastatic lesions are incidental findings at autopsy and are solitary;<sup>3</sup> antemortem diagnosis varies from 25% to 62.5% in different series. It is of interest that the average age of patients suffering from metastatic lesions to the

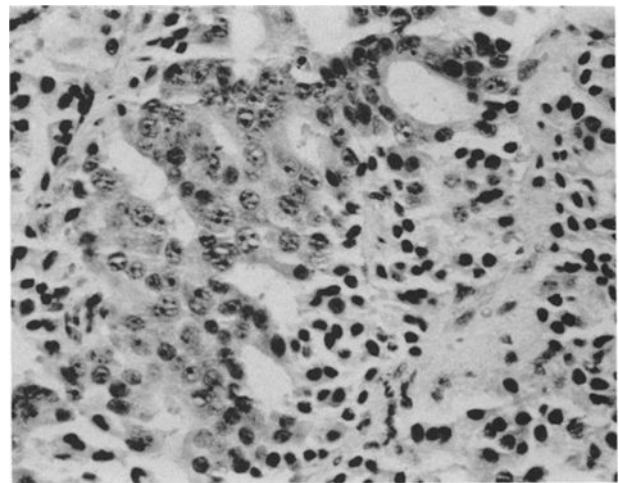


FIG. 2. Photomicrograph showing prostatic adenocarcinoma infiltrating the pituitary. The glandular structures that are lined by large columnar cells with nuclei containing prominent nucleoli contrast with the smaller pituitary cells with dark nuclei. H & E,  $\times 70$ .

cerebral parenchyma is younger than that of patients diagnosed with carcinoma of the prostate in general (59 vs. 70 years).<sup>10</sup> The basis for this disparity is speculative but it may be the result of a more clinically aggressive tumor in patients with cerebral metastases, supported pathophysiologically by poorly differentiated tumors found histologically, as in this patient and in other case reports.<sup>5,11</sup>

The literature usually reports a short period of survival in patients with brain metastases.<sup>4,5,14</sup> This is most likely a reflection of the extent of disease at the time of diagnosis; however, there are isolated reports of prolonged survival following surgical extirpation of the metastatic lesion.<sup>10-12</sup> External beam radiation therapy and hormonal manipulation may also prolong survival in selected patients.<sup>2,10</sup> The present case supports the general consensus that neurosurgical intervention may be of symptomatic benefit and may possibly prolong life in selected patients with carcinoma of the prostate.

### References

1. Batson OV: The function of the vertebral veins and their role in the spread of metastases. *Ann Surg* 112:138-149, 1940
2. Baumann MA, Holoye, PY, Choi H: Adenocarcinoma of the prostate presenting as brain metastasis. *Cancer* 54: 1723-1725, 1984
3. Campbell JR, Godsall JW, Bloch S: Neurological complications in prostatic carcinoma. *Prostate* 2:417-423, 1981
4. Castaldo JE, Bernat JL, Meier FA, et al: Intracranial metastases due to prostatic carcinoma. *Cancer* 52: 1739-1747, 1983
5. Catane R, Kaufman J, West C, et al: Brain metastases from prostatic carcinoma. *Cancer* 38:2583-2587, 1976
6. Chung TS, Thannikkary C: Carcinoma of the prostate

- with brain metastasis. **J Surg Oncol** 33:103-105, 1986
7. Elkin M, Mueller HP: Metastases from cancer of the prostate. Autopsy and roentgenological findings. **Cancer** 7:1246-1248, 1954
  8. Franks LM: Latent carcinoma of the prostate. **J Pathol Bacteriol** 68:603-621, 1954
  9. Klein LA: Prostatic carcinoma. **N Engl J Med** 300:824-833, 1979
  10. Lynes WL, Bostwick DG, Freiha FS, et al: Parenchymal brain metastases from adenocarcinoma of the prostate. **Urology** 28:280-287, 1986
  11. Rao KG: Carcinoma of prostate presenting as intracranial tumor with multiple cranial nerve palsies. **Urology** 19:433-435, 1982
  12. Smith VC, Kasdon DL, Hardy RC: Metastatic brain tumor from the prostate: two unusual cases. **Surg Neurol** 14:189-191, 1980
  13. Varkarakis MJ, Winterberger AR, Gaeta J, et al: Lung metastases in prostatic carcinoma. Clinical significance. **Urology** 3:447-452, 1974
  14. The Veterans Administration Cooperative Urologic Research Group: Factors in the prognosis of carcinoma of the prostate: a cooperative study. **J Urol** 100:59-65, 1968

---

Manuscript received August 30, 1988.

*Address reprint requests to:* Martin H. Weiss, M.D., Department of Neurosurgery, 1200 North State Street, Suite 5046, Los Angeles, California 90033.