

Emergent Aneurysm Clipping without Angiography in the Moribund Patient with Intracerebral Hemorrhage: The Use of Infusion Computed Tomography Scans

Peter D. Le Roux, M.D., Andrew T. Dailey, M.D.,
David W. Newell, M.D., M. Sean Grady, M.D.,
H. Richard Winn, M.D.

Department of Neurological Surgery, Harborview Medical Center and the
University of Washington, Seattle, Washington

THE AUTHORS REPORT their experience with 25 patients (mean age, 44.3 ± 12.1 years) with an intracerebral hematoma (ICH) from a ruptured aneurysm who were emergently operated on without angiography. Instead, preoperative high-resolution infusion computed tomography (CT) scans were used to identify the aneurysm causing the hemorrhage. In all patients, the preoperative Glasgow Coma Scale score was <5 and brain stem compression was evident. ICH was present in the frontal or temporal lobe and was often associated with intraventricular hemorrhage ($n=17$) and significant (>1 cm) midline shift ($n = 18$). Infusion CT scans correctly identified the aneurysm in all patients (middle cerebral artery, 18; posterior communicating artery, 2; carotid bifurcation, 3; anterior communicating artery, 2). Partial evacuation of the hematoma guided by infusion CT scan was usually required first to clip the aneurysm definitively using standard microvascular techniques. Intraoperative rupture occurred twice, and temporary clips were used on four occasions. Lobectomy ($n=8$), decompressive craniotomy ($n=15$), and ventriculostomy ($n=8$) were required to control cerebral swelling. All patients underwent postoperative angiography to confirm aneurysm obliteration. Eleven unruptured aneurysms were subsequently identified. Nine had been predicted by infusion scan. Twelve patients survived, eight of whom were only moderately disabled and were independent at 6-months' follow-up. Of the 13 patients who died, all except one died within 4 days of admission. The authors conclude that although angiographic verification before aneurysm surgery is preferable, in the moribund patient with intracerebral hemorrhage, infusion CT scanning provides sufficient information concerning vascular anatomy to allow rational emergency craniotomy and aneurysm clipping. (*Neurosurgery* 33:189-197, 1993)

Key words: Aneurysm, Computed tomography, Infusion computed tomography, Intracerebral hemorrhage, Outcome, Surgery

Aneurysm rupture causing coma (Hunt and Hess Grades IV and V) (12) is associated with high mortality (4, 8, 10, 14, 15). An intracerebral hematoma (ICH) may often be found in these patients and contributes significantly to the poor outcome (3-5, 16, 27). Although surgery has traditionally been reserved for patients with good clinical grades (Hunt and Hess Grades I-III), recent experience in the management of patients with subarachnoid hemorrhage (SAH) and a poor clinical grade suggests that aggressive therapy, including early surgery, may improve outcome (5, 17, 23, 27). However, the presence of a large aneurysmal ICH in a comatose patient who continues to deteriorate poses a surgical dilemma. Undoubtedly, primary brain impairment occurs at the time of the original SAH, but further injury results from the consequent ICH, resultant mass

effect, and intracranial hypertension. Prompt removal of the ICH and relief of intracranial pressure (ICP) can result in dramatic clinical improvement. Moreover, simultaneous clipping of the ruptured aneurysm at the time of clot removal appears to lead to better outcome and allows aggressive treatment of vasospasm (22, 26). Preoperative angiography clearly provides definitive vascular anatomy (11, 19, 21, 22, 25, 26), but angiography, even of a single vessel, may cause a life-threatening delay in the acutely unstable aneurysm patient.

We have reported previously our experience with acute surgery for aneurysm patients with poor clinical grades and our utilization of infusion CT scans (18, 27). In the present study, we report our 5-year experience with the management of 25 moribund Grade V SAH patients with ICH in whom preop-

erative angiography was not utilized. Instead of empiric exploration of the sylvian fissure and carotid cisterns, as has previously been suggested (6, 7), we now use infusion CT scanning, a technique more rapid than even single-vessel angiography. The technique was found to provide sufficient anatomic information to allow rapid, definitive surgery.

PATIENTS AND METHODS

Patient population

We evaluated all patients admitted to Harborview Medical Center from 1987 through 1991 who met the following criteria: 1) evidence of herniation or brain stem compression associated with ICH and 2) emergency aneurysm clipping without cerebral angiography. Twenty-five patients were identified.

Resuscitation

Harborview Medical Center is the major emergency, Level 1 referral center for Seattle, Washington, and the surrounding area. All patients with SAH were evaluated by the neurosurgery service in the emergency room. Aggressive resuscitation including intubation, ventilation, fluid resuscitation, and mannitol therapy was instituted in the field and continued in the emergency room.

Radiology

Once the patient was stabilized, immediate CT scans without contrast medium were obtained, followed by infusion CT scanning (GE 9800, General Electric Medical Systems, Milwaukee, WI). As previously described (18), patients were given a constant intravenous infusion of contrast (80–100 ml of sodium diatrizoate) while scans were obtained in the dynamic mode from the floor of the sella turcica to a point above the anterior communicating artery (± 15 – 25 1.5-mm slices). Images were photographed at intermediate windows (Level 80, 400 Hounsfield units) to allow distinction between blood and contrast material. In previous studies, this method has been demonstrated to detect 97% of aneurysms greater than 3 to 5 mm in size (18, 24). The scanning technique requires approximately 10 to 15 minutes to perform.

Surgery

All patients with both clinical and CT evidence of brain stem compression (despite maximal medical therapy) from aneurysmal ICH were taken directly to the operating room. Patients with aneurysmal ICH who were neurologically stable underwent angiography prior to surgery. A pterional craniotomy, significantly larger than the standard aneurysmal approach, was performed. The surgical approach was planned to allow complete evacuation of the hematoma and access to the circle of Willis. The aneurysm was approached using standard microvascular techniques, but because of increased ICP, bone reduction of the orbital roof and sphenoid wing was not attempted. After the dura was opened, clot distant from the aneurysm was partially removed to provide brain relaxation. Proximal vessels were then visualized. Hematoma evacuation was only completed after definitive obliteration of the aneu-

rysm. If cerebral swelling remained, a duraplasty was performed using temporal fascia, and the bone flap was not replaced. Magnification was used in all cases.

Postoperative care

Immediate postoperative CT scans were obtained for all patients and compared with preoperative studies to assess the extent of clot removal. All patients underwent four-vessel angiography within 24 hours of surgery. Patients were cared for in the Neurosurgery Intensive Care Unit with ICP monitoring and invasive hemodynamic monitoring. Daily transcranial Doppler studies, frequent CT scans, and single photon emission CT scanning supplemented the clinical evaluation. Each patient received dexamethasone, phenytoin, and nimodipine and hypervolemic, hypertensive fluid therapy. Intracranial hypertension (>20 mm Hg) was treated initially by medical means including sedation (morphine sulphate), paralysis (pancuronium), hyperventilation (P_{aCO_2} of 25–30 mm Hg), and mannitol, and then surgically, as extensive decompression had been performed at the initial operation. Transluminal angioplasty was utilized to treat symptomatic vasospasm when other means of therapy were ineffective.

Outcome

Outcome according to the Glasgow Outcome Scale described by Jennet and Bond (13) was assessed at a clinic visit at 6 months. The five Glasgow Outcome Scale categories are "good," "moderately disabled," "severely disabled," "vegetative," and "dead." Patients with a Glasgow Outcome Scale grade of "good" or "moderately disabled" are independent for all their needs and participate in a normal social life. To determine if there were any factors that correlated with outcome, we assessed a variety of clinical factors (age, Glasgow Coma Scale score, pupillary abnormalities); radiological features (size of ICH, intraventricular hemorrhage, shift); time to surgery; and postoperative findings (ICP, hematoma evacuation, vasospasm, infarction). Statistical comparison between groups was assessed with Student's unpaired *t* test or the Fischer exact test in the case of small observed numbers in any classification category. Bonferronian inequality was used to protect against the inflation of chance in the case of multiple associations.

RESULTS

Patients and clinical characteristics

In a 5-year period, 25 patients (18 women and 7 men) with both clinical and CT evidence of brain stem compression after ICH underwent emergent aneurysm clipping without angiography (Table 1). The mean age of the patients was 44.3 ± 12.1 years (range, 23–67 years). All patients were classified as Hunt and Hess Grade V (11). The Glasgow Coma Scale score at admission was 3 in 8 patients, 4 in 14 patients, and 5 in 3 patients. These latter three patients deteriorated and demonstrated extensor posturing while undergoing CT scan. Twelve patients were admitted with bilaterally fixed and dilated pupils, although other brain stem reflexes were present. The remaining patients all had dilated, nonreactive pupils ipsilateral to the

TABLE 1. Clinical and Radiographic Characteristics of Moribund Patients with Intracerebral Hemorrhage Who Underwent Aneurysm Surgery without Angiography

Patient	Age (yr)/Sex	GCS ^a	Findings of Preoperative Examination ^b	Findings of Admission CT Scan ^c	Findings of Infusion CT ^d	Time (hr) ^e	Surgery ^f	Outcome ^g
1	30/M	3	L pupil FD; corneals +; oc, ov-	L temporal ICH, 4 × 5 cm; severe IVH, >1 cm shift	L MCA, 8 mm	3	Hematoma evacuation, ventriculostomy, temporal lobectomy, decompressive craniotomy, intraoperative leak	Dead
2	40/F	3	R pupil FD; corneals, oc, ov+	R sylvian ICH, 4 × 4 cm; 8 mm shift	R MCA, 12 mm	6	Hematoma evacuation, ventriculostomy	Dead
3	33/F	3	B pupil FD; corneals -, oc, ov+	R frontotemporal ICH, 5 × 3 cm; moderate IVH, 7 mm shift	R MCA, 8 mm	7	Hematoma evacuation, temporal lobectomy, decompressive craniotomy, intraoperative rupture, temporary clip	Dead
4	42/F	4	R pupils FD; corneals, oc-, ov+	R frontal ICH, 4 × 5 cm; >1 cm shift	R MCA, 7 mm	5	Hematoma evacuation, decompressive craniotomy	Dead
5	49/M	3	B pupils FD; corneals -, oc, ov+	L frontal ICH, 3 × 5 cm; severe IVH, >1 cm shift	L ICA, 9 mm	5	Hematoma evacuation, decompressive craniotomy, ventriculostomy	Dead
6	25/M	4	B pupils FD; corneals +, oc-, ov-	L frontotemporal ICH, 6 × 3 cm; 5 mm shift	L ICA, 8 mm	4	Hematoma evacuation	Dead
7	37/F	4	B pupils FD; corneal +; oc-, ov-	L frontotemporal ICH, 8 × 4 cm; severe IVH, >1 cm shift	L MCA, 3 mm	3	Hematoma evacuation, decompressive craniotomy, ventriculostomy	Dead
8	57/F	3	L pupil FD; corneal, oc, ov+	L temporoparietal ICH, 6 × 5 cm; mild IVH, >1 cm shift	L MCA, 20 mm	8	Hematoma evacuation	Dead
9	46/F	5	R pupil FD; corneal, oc, ov+, L HP	R frontotemporal ICH, 7 × 6 cm; >1 cm shift	R MCA, 8 mm	6	Hematoma evacuation	Dead
10	62/F	5	B pupils FD; corneals, oc+, ov-	L frontotemporal ICH, 7 × 6 cm; moderate IVH, >1 cm shift	L ACoA, 11 mm	3.5	Hematoma evacuation, intraoperative rupture, temporary clip, anterior temporal lobectomy, decompressive craniotomy	Dead

^a GCS, Glasgow Coma Scale score at admission.

^b L, left; R, right; B, bilateral; FD, fixed and dilated; oc, oculocephalic reflex; ov, oculovestibular reflex; +, present; -, absent.

^c CT, computed tomography; ICH, intracerebral hemorrhage; IVH, intraventricular hemorrhage; SDH, subdural hematoma (all patients had subarachnoid hemorrhage).

^d Performed for location of aneurysm and size. MCA, middle cerebral artery; ICA, internal carotid artery; ACoA, anterior communicating artery; PCoA, posterior communicating artery.

^e Time from onset of symptoms to skin incision.

^f All patients had their symptomatic aneurysm clipped.

^g Glasgow Outcome Score at 6 months.

TABLE 1. Continued

Patient	Age (yr)/Sex	GCS ^a	Findings of Preoperative Examination ^b	Findings of Admission CT Scan ^c	Findings of Infusion CT ^d	Times (hr) ^e	Surgery ^f	Outcome ^g
11	51/F	4	B pupils FD; corneal +; oc-, ov+	L temporal ICH, 5 × 6 cm, mild IVH, >1 cm shift	L MCA, 18 mm	4.5	Hematoma evacuation, intraoperative leak, decompressive craniotomy	Dead
12	30/M	4	B pupils FD; corneal, oc, ov-	L temporal ICH, 6 × 4 cm; severe IVH, >1 cm shift	L MCA, 8 mm	5	Hematoma evacuation, decompressive craniotomy, ventriculostomy	Dead
13	49/F	4	R pupil FD; corneal, oc, ov-	R frontal ICH, 4.5 × 8 cm; >1 cm shift, mild IVH	R MCA, 5 mm	4	Hematoma evacuation, temporary occlusion, frontal lobectomy, decompressive craniotomy, ventriculostomy	Dead
14	37/F	4	B pupils FD; corneal +; oc; ov-	L temporal ICH, 4 × 6 cm; >1 cm shift	L MCA, 15 mm	2.5	Hematoma evacuation, temporary clip, decompressive craniotomy	Vegetative
15	35/M	3	R pupil FD; corneals, oc-; ov+	R frontal ICH, 3 × 5 cm; severe IVH, 7 mm shift	R ACoA, 8 mm	4	Hematoma evacuation, ventriculostomy	Severe disability
16	30/F	4	B pupils FD; corneal +; oc; ov-	L temporal ICH, 5 × 6 cm; moderate IVH, 7 mm shift	L MCA, 12 mm	8	Hematoma evacuation	Severe disability
17	50/M	4	B pupils FD; corneal +; oc, ov+	R frontotemporal ICH, 6 × 8 cm; moderate IVH, >1 cm shift	R MCA, 8 mm	3	Hematoma evacuation; temporary occlusion, ventriculostomy	Severe disability
18	67/F	5	R pupil FD; L hemiplegia; corneals, oc-; ov+	R temporal ICH, 4 × 3 cm; 6 mm shift, R SDH	R PCoA, 14 mm	3.5	Hematoma evacuation, temporal lobectomy	Moderate disability
19	65/F	4	L pupil FD; R hemiplegia; corneals -, oc, ov+	L sylvian ICH, 5 × 3 cm; >1 cm shift, mild IVH	L MCA, 16 mm	5.5	Hematoma evacuation	Moderate disability
20	49/F	4	R pupil FD; corneals, oc, ov+	R frontal ICH, 5 × 3 cm; severe IVH, 8 mm shift	R ICA, 10 mm	4	Hematoma evacuation, temporal lobectomy, decompressive craniotomy	Moderate disability
21	54/F	3	R pupil FD; corneals, oc-; ov+	R temporal ICH, 3 × 5 cm; >1 cm shift	R MCA, 11 mm	7	Hematoma evacuation, temporal lobectomy, decompressive craniotomy	Moderate disability
22	52/F	4	R pupil FD; corneal +; oc+; ov-	R temporal ICH, 4.5 × 4 cm; mild IVH >1 cm shift	R MCA, 12 mm	6	Hematoma evacuation, anterior temporal lobectomy, delayed decompressive craniotomy	Moderate disability

TABLE 1. Continued

Patient	Age (yr)/Sex	GCS ^a	Findings of Preoperative Examination ^b	Findings of Admission CT Scan ^c	Findings of Infusion CT ^d	Times (hr) ^e	Surgery ^f	Outcome ^g
23	47/M	4	R pupil FD; corneal, oc+; ov-	R frontotemporal ICH, 5 × 7 cm; >1 cm shift	R MCA, 15 mm	4.5	Hematoma evacuation, intraoperative leak, temporary occlusion, delayed decompressive craniotomy	Moderate disability
24	23/F	4	B pupils FD; corneal, oc-; ov+, R HP	L frontotemporal ICH; moderate IVH, >1 cm shift	L PCoA, 9 mm	4	Hematoma evacuation	Moderate disability
25	48/F	3	B pupils FD; corneal, oc-; ov+	L temporal ICH, 5 × 6 cm; mild IVH >1 cm shift	L MCA, 30 mm	3	Hematoma evacuation, rebleeding, secondary clipping, delayed decompressive craniotomy	Moderate disability

ICH at admission. After mannitol treatment, the pupil contralateral to the ICH became reactive in six of the patients exhibiting bilaterally fixed pupils. Improvement in motor function, however, was not observed. Despite maximal medical therapy, no other patients demonstrated signs of clinical improvement before surgery.

Radiological characteristics

On CT scans, subarachnoid hemorrhage and obliteration of the perimesencephalic cisterns were present in all cases. Intraventricular hemorrhage occurred in 17 patients. Intracerebral hematomas were located in the temporal/sylvian ($n = 11$), temporoparietal ($n = 1$), frontal ($n = 5$), and frontotemporal ($n = 8$) regions. Each was greater than 4 cm in diameter. Midline shift of more than 1 cm was evident in 18 patients; the remaining patients had shift of more than 5 mm. The mean shift was 12.4 ± 4.3 mm.

Infusion CT scanning demonstrated the location of the aneurysm causing ICH in all patients, the hematoma showing an intimate relation to the aneurysm. Temporal or temporoparietal ICH resulted from aneurysms of the middle cerebral ($n = 11$) or posterior communicating ($n = 1$) arteries. Frontal hemorrhage was caused by aneurysms of the middle cerebral ($n = 2$), anterior communicating ($n = 1$), or internal carotid ($n = 2$) arteries. Frontotemporal ICH followed rupture of aneurysms of the middle cerebral ($n = 5$), internal carotid ($n = 1$), posterior communicating ($n = 1$), or anterior communicating ($n = 1$) arteries (Fig. 1). The mean aneurysm size was 11.4 ± 5.6 mm (range, 3–30 mm). Ongoing hemorrhage from the aneurysm and enlargement of the ICH were seen in four patients. Nine asymptomatic aneurysms were identified.

Surgery

Patients with aneurysmal ICH and ongoing brain stem compression were taken directly to surgery after infusion CT. The mean time from the onset of symptoms to skin incision was 4.8 ± 1.6 hours (range, 2.5–8 hours). The infusion CT scan took less than 15 minutes to perform in all patients. Large craniot-

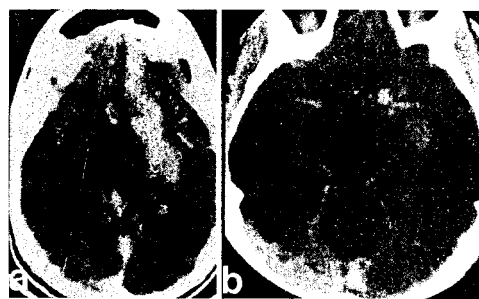


FIGURE 1. *a*, Preoperative CT scan demonstrating a left frontotemporal intracerebral hemorrhage. *b*, Infusion CT scan revealing an aneurysm of the carotid bifurcation (arrow) responsible for the hemorrhage. The M1 and A1 segments are visible (arrowheads).

omies were created. Partial evacuation of the hematoma (away from the aneurysm) was performed initially to visualize proximal vessels. Massive hemorrhage from aneurysm rupture during hematoma evacuation occurred twice (Patients 3 and 10). Control was established with suction, tamponade, and temporary clipping. Three minor leaks occurred during dissection of the aneurysm neck (Patients 1, 11, 23). Aneurysms were definitively clipped (confirmed by dome puncture) in all cases. Once the aneurysm had been obliterated, the remaining hematoma was evacuated. Cerebral swelling was controlled by lobectomy ($n = 8$), decompressive craniotomy ($n = 12$), and ventriculostomy ($n = 8$). Six patients underwent both lobectomy and decompressive craniotomy.

Postoperative course

Immediate postoperative CT scans demonstrated ICH evacuation in all patients (>90% in 21 patients, 60–90% in 4 patients). The four patients with partial hematoma evacuation (60–90%) died. Infarction was evident in 12 patients (8 who later died, 2 who were severely disabled, and 2 who were

moderately disabled at follow-up). Single photon emission CT scanning confirmed a perfusion defect in these patients.

Four-vessel angiography (obtained within 24 hours of surgery in all cases) confirmed aneurysm obliteration in 24 cases without compromise of adjacent vessels by the clip. The patient (Case 25), whose aneurysm was not completely obliterated, had marked atherosclerosis in the neck of the aneurysm. She was returned to the operating room for definitive clipping after hemorrhaging again 2 days after surgery. Repetition of angiography showed aneurysm occlusion. Eleven asymptomatic, unruptured aneurysms were identified in seven patients. Infusion CT scan had predicted nine of these.

Intractable intracranial hypertension developed in three patients (Cases 3, 5, and 13), all of whom demonstrated infarction on postoperative scans obtained within 24 hours of surgery and later died. Mannitol therapy to control increased ICP was needed in another seven patients, including two who were moderately disabled at follow-up (Cases 20 and 24). Delayed decompressive craniectomy was performed in two patients (Cases 22 and 23) who developed cerebral swelling and increased ICP after an initial improvement. A third patient (Case 25) was returned to the operating room after a second hemorrhage and resultant increase in ICP for aneurysm clipping and decompressive craniectomy. These three patients were all moderately disabled at follow-up. Asymptomatic vasospasm (identified either by transcranial Doppler or by angiogram) was found in five patients. A single patient (Case 25) developed symptomatic vasospasm that responded to angioplasty.

Outcome

At the 6-month follow-up examination, eight patients were found to be moderately disabled and fully independent in all activities of daily living. All but one of these patients regained consciousness within 72 hours of surgery. Four other patients survived: one remains vegetative and three are severely disabled. Thirteen patients died, all except one (Case 13) within

4 days of admission. We were unable to demonstrate any statistical correlation between preoperative, operative, or postoperative factors and outcome, although failure to demonstrate neurological improvement soon after surgery was indicative of a bad outcome.

ILLUSTRATIVE CASES

Patient 3

A 33-year-old woman developed a severe headache followed by a generalized seizure and progressive decline in consciousness. At admission, her Glasgow Coma Scale score was 3, with triple flexion of the lower extremities. Both pupils were fixed and dilated; the left responded to mannitol therapy (1 g/kg). A CT scan of the head revealed a right frontotemporal ICH measuring 5 × 3 cm, with moderate intraventricular hemorrhage and 7 mm of midline shift (Fig. 2a). An aneurysm of the right middle cerebral artery measuring 8 mm in diameter was identified on the infusion CT scan (Fig. 2b). A large right frontotemporal craniotomy was performed. The brain was found to be extremely swollen when the dura was opened; hemorrhage came to the surface in the superior temporal gyrus 5 cm behind the temporal tip. Intraoperative aneurysm rupture occurred after partial evacuation of the ICH. Suction allowed identification of the M1 trunk, and after temporary clip application (occlusion time, 10 minutes), the aneurysm neck in the MCA bifurcation was dissected and clipped. Anterior temporal lobectomy and decompressive craniotomy were needed to control cerebral swelling. A postoperative CT scan showed extensive infarction in the right hemisphere (Fig. 2c); angiography confirmed aneurysm obliteration. The patient developed intractable intracranial hypertension and died 4 days after admission.

Patient 19

A 65-year-old woman collapsed at home. She was unresponsive when paramedical staff arrived and was intubated and transported to Harborview Medical Center. At arrival, she had a dilated, nonresponsive left pupil, was flaccid on her right side, and demonstrated decerebrate posturing of the left side. A CT scan revealed an ICH measuring 5 × 3 cm in the left perisylvian region with midline shift and a trapped

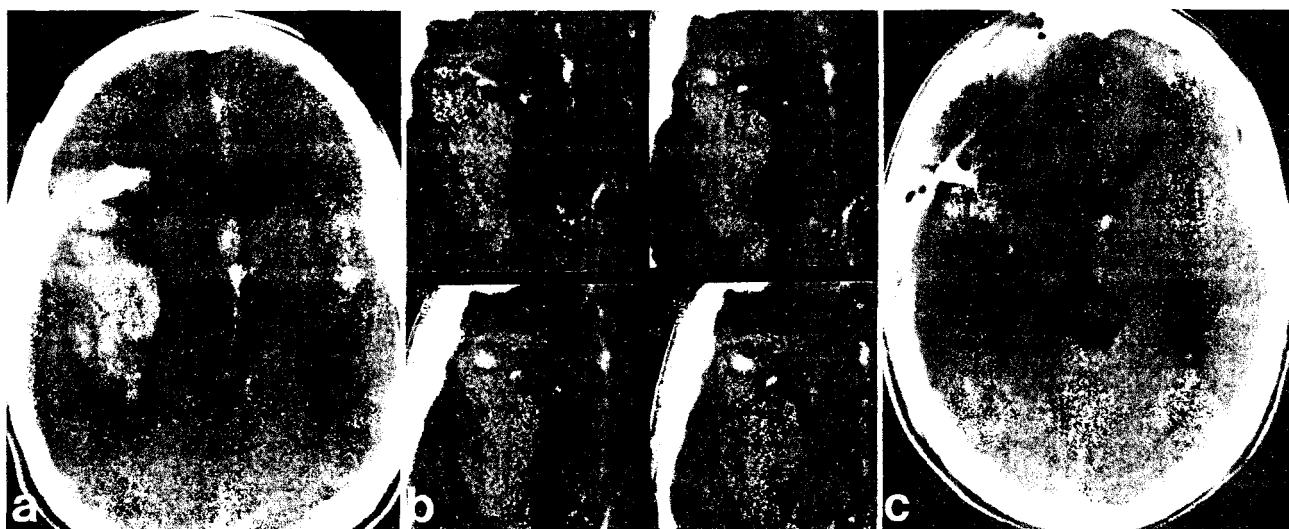


FIGURE 2. Case 3. a, Preoperative CT scan showing a large right frontotemporal intracerebral hemorrhage. b, Infusion CT scan demonstrating a small aneurysm of the right middle cerebral artery (arrow) and the M1 segment (arrowheads). c, Postoperative CT scan revealing extensive right hemisphere infarction.

right ventricle (Fig. 3a). A 1.6-cm aneurysm of the left middle cerebral artery was visible on the infusion CT scan (Fig. 3b). A large left frontotemporal craniotomy was performed. Partial evacuation of the hematoma through the sylvian fissure allowed identification of the dome of the aneurysm pointing laterally into the superior temporal gyrus. The sylvian fissure was split proximally and the M1 segment and middle cerebral artery trifurcation were delineated under the microscope before the aneurysm was clipped. The remaining ICH was evacuated (Fig. 3c). A postoperative angiogram showed obliteration of the aneurysm (Fig. 4). The patient recovered rapidly and at 6 months is independent, living at home, and socially active, but moderately disabled by mild expressive dysphasia. Her right hemiplegia completely resolved.

DISCUSSION

In this study, we report our 5-year experience with the management of 25 moribund, Grade V SAH patients with ICH in whom preoperative angiography was not utilized. Instead, infusion CT scanning, a technique more rapid than even single-vessel angiography, provided sufficient anatomic information to allow definitive hematoma evacuation and aneurysm clipping. Although all patients were moribund with evidence of brain stem compression, 12 survived, of whom 8 were moderately disabled and independent at follow-up.

The presence of coma, particularly when associated with ICH, significantly increases mortality after SAH (1, 3-5, 8, 9-11, 14-16, 19, 21, 25-27). In the first cooperative study, Locksley (16) noted that 90% of patients dying within 72 hours of SAH had ICH (16). In the subsequent cooperative study, level of consciousness was strongly associated with outcome: 72% of the patients in coma died, whereas 75% of those who were alert at admission had good outcomes (14). Adams et al. (1), after reviewing 1734 patients, suggested that the combination of coma and ICH on CT scan was the strongest predictor of poor outcome.

The optimal treatment of these patients with coma and aneurysmal ICH remains in question. Surgery for aneurysms has traditionally been reserved for patients with good clinical grades. Even in these patients, the presence of ICH can adversely affect outcome. Auer and colleagues (3, 4) found that more than 90% of patients classified as Grade I or II had a good outcome, whereas only 50% had a good outcome if ICH was

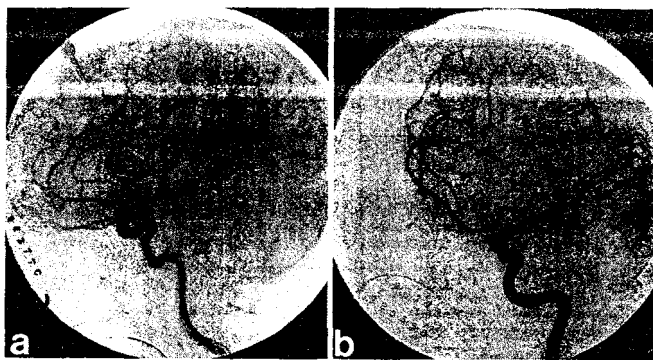


FIGURE 4. Case 19. Lateral (a) and oblique (b) postoperative subtraction angiograms demonstrating an occluded aneurysm in the middle cerebral artery trifurcation.

present. In a recent prospective study of 325 patients, Saveland et al. (23) reported similar findings. Only one prospective, randomized study, reported by Heiskanen et al. (11), has attempted to evaluate the management of aneurysmal ICH of all clinical grades. Fifteen patients were treated conservatively, resulting in 80% mortality. Fifteen patients underwent angiography and surgical treatment of whom 27% died. Mortality in the surgical group was doubled if consciousness was altered. Tapaninho et al. (25) reported 31 patients who underwent surgery for aneurysmal ICH after CT and angiography. Half of these patients died. However, all Grade V patients with evidence of brain stem compression died. Papo et al. (19) similarly found that all patients with extensor posturing and pupillary abnormalities died.

Apart from coma and herniation, two further factors appear to worsen outcome in aneurysmal ICH: a delay in surgery and inability to clip the aneurysm at the time of hematoma evacuation. Pasqualin et al. (21) reviewed 309 patients with aneurysmal ICH. Among 32 Grade IV patients, delayed surgery was associated with 79% mortality, whereas early surgery was associated with 44% mortality. A small reduction in mortality was observed in Grade V patients who did not demonstrate signs of main stem compression. Seventy-seven of these patients underwent surgery; mortality was 78% and 96% in those undergoing early or delayed surgery, respectively. Wheelock et al. (26), in a retrospective study of 132 patients from 11 centers, found that hematoma evacuation without aneurysm clipping was associated with 75% mortality, as compared with only 29% mortality when definitive aneurysm clipping was achieved at the same time as hematoma evacuation. Both studies, however, found that patients with large hematomas (>3 cm) and herniation did extremely poorly, and like others (4, 19, 21, 25, 26), advocated against surgical intervention in the moribund patient with brain stem compression or herniation from aneurysmal ICH.

By contrast, we and others (6, 7, 22) have postulated that while many of these patients are irreparably injured, some are moribund because of mass effect and so may benefit from immediate surgical treatment. Two recent reports have suggested that hematoma evacuation and aneurysm clipping without angiography are feasible in these patients and may prove

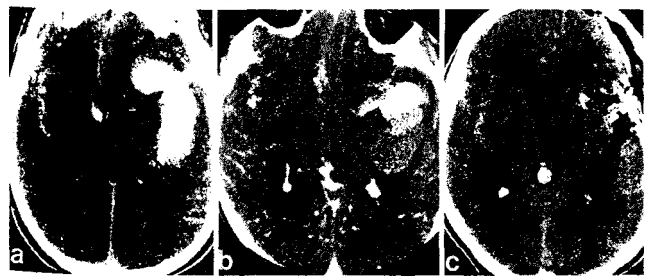


FIGURE 3. Case 19. a, Preoperative CT scan demonstrating a large left perisylvian intracerebral hematoma. b, Infusion CT scan showing a large aneurysm of the left middle cerebral artery in relation to the middle cerebral artery and branches (arrow). c, Postoperative CT scan demonstrating evacuation of the hematoma.

life saving (6, 7). Brandt et al. (7) treated four such patients after rupture of a middle cerebral artery aneurysm. Three survived with moderate disability. Batjer and Samson (6) similarly operated on four moribund patients, three with aneurysms of the middle cerebral artery and one with a carotid aneurysm. The three survivors were severely disabled. Both authors indicated that the patients' clinical condition precluded a delay for angiography before surgery. Aneurysms were either encountered during hematoma evacuation or suspected from the CT characteristics, which prompted empiric exploration of the sylvian fissure to clip the aneurysm.

Although the etiology of ICH can be predicted with a high degree of accuracy from CT characteristics, enough doubt often exists to warrant further investigation (22). Crompton (9) found that nearly 15% of cases of aneurysmal ICH coming to autopsy were in the external capsule. Pasqualin et al. (21) similarly found that aneurysmal ICH could involve the basal ganglia only. In addition, hypertensive ICH, which may be confused with aneurysmal ICH, can extend into the sylvian fissure. Middle cerebral artery aneurysms leading to temporal lobe ICH usually have the most typical CT characteristics, but account for only half the cases of aneurysmal ICH (9, 11, 19, 21, 25, 26). Moreover, they may rupture into the frontal lobe only, as occurred in two of our patients. We therefore routinely perform four-vessel angiography on patients with ICH suspected of harboring an aneurysm, provided they are neurologically stable. However, in the moribund patient who is deteriorating, even single-vessel angiography may create a life-threatening delay. Rather than empiric exploration of the sylvian vessels, we obtain infusion CT scans immediately after standard CT scans if an ICH is identified. Since the patient is already in the scanner, the infusion scan takes approximately 10 minutes to perform. The information obtained allows the patient to be taken directly to the operating room for hematoma evacuation and aneurysm clipping. Distinct advantages are offered: 1) an aneurysm is known to be present, which allows the surgical team, anesthesiologists, and operating room staff to plan accordingly; 2) the location of the aneurysm causing the ICH (and other aneurysms) is known; 3) hematoma evacuation can be directed to minimize inadvertent rupture of the aneurysm; and 4) a combination of axial images and coronal reconstruction provides useful anatomic information about the aneurysm and surrounding vessels.

Like others (5, 22), we were not able to demonstrate any preoperative clinical factors that predicted outcome. Surprisingly, two patients who by best estimates had bilaterally fixed and dilated pupils for 30 minutes before admission had a favorable outcome. Observation in the postoperative period, however, appears to provide prognostic information. With the exception of one patient, those who survived all regained consciousness within 72 hours. By contrast, those who died inevitably did so within 4 days. Based on natural history data (2) only 5% or fewer of Grade V patients survive. In the present study, even when severe brain stem compression was evident, 48% of the patients survived and 32% achieved an independent outcome, albeit with a persistent mild or moderate neurological finding. The described approach requires a significant commitment of resources, beginning with an efficient para-

medic service practicing in-the-field resuscitation and ultra-early referral to a center with an interest and expertise in acute aneurysm surgery. Postoperatively, intensive therapy during the acute and rehabilitation stages are required.

In summary, this report has demonstrated that definitive aneurysm clipping without benefit of angiography but facilitated by infusion CT scan is possible in the moribund patient with aneurysmal ICH, and may provide a reasonable chance of neurological recovery in this select group of aneurysm patients.

Received, October 9, 1992.

Accepted, February 26, 1993.

Reprint requests: Peter D. Le Roux, M.D., Department of Neurosurgery RI-20, University of Washington, Seattle, WA 98195.

REFERENCES

1. Adams HP, Kassell NF, Torner JC: Usefulness of computed tomography in predicting outcome after aneurysmal subarachnoid hemorrhage: A preliminary report of the cooperative aneurysm study. *Neurology* 35:1263-1267, 1989.
2. Alvord EC, Loeser JD, Bailey WL, Copass MK: Subarachnoid hemorrhage due to ruptured aneurysms: A simple method of estimating prognosis. *Arch Neurol* 27:273-284, 1972.
3. Auer L, Schneider G, Auer T: Computerized tomography and prognosis in early aneurysm surgery. *J Neurosurg* 65:217-221, 1986.
4. Auer L: Unfavorable outcome following early surgical repair of ruptured cerebral aneurysms: A critical review of 238 patients. *Surg Neurol* 35:152-158, 1991.
5. Bailes JE, Spetzler RF, Hadley MN, Baldwin ME: Management morbidity and mortality of poor grade aneurysm patients. *J Neurosurgery* 72:559-566, 1990.
6. Batjer HH, Samson DS: Emergent aneurysm surgery without cerebral angiography for the comatose patient. *Neurosurgery* 28: 283-287, 1991.
7. Brandt L, Sorenson B, Ljunggren B, Saveland H: Ruptured middle cerebral artery aneurysm with intracerebral hemorrhage in younger patients appearing moribund: Emergency operation? *Neurosurgery* 20:925-929, 1987.
8. Chyatte D, Forde N, Sundt T: Early versus late intracranial aneurysm surgery in subarachnoid hemorrhage. *J Neurosurg* 69:326-331, 1988.
9. Crompton MR: Intracerebral hematoma complicating ruptured cerebral berry aneurysm. *J Neurol Neurosurg Psychiatry* 25:378-386, 1962.
10. Disney L, Weir B, Petruk K: Effect on management mortality of a deliberate policy of early operation on supratentorial aneurysms. *Neurosurgery* 20:695-701, 1987.
11. Heiskanen O, Poranen A, Kuurne T, Valtonen S, Kaste M: Acute surgery for intracerebral hematomas caused by rupture of an intracranial arterial aneurysm. A prospective randomized study. *Acta Neurochir (Wien)* 90:81-83, 1988.
12. Hunt WE, Hess RM: Surgical risk related to time of intervention in the repair of intracranial aneurysms. *J Neurosurg* 24:14-19, 1968.
13. Jennet B, Bond M: Assessment of outcome after severe brain damage: A practical scale. *Lancet* 1:480-484, 1975.
14. Kassell NF, Torner JC, Haley C, Jane J, Adams HP, Kongable BSN: The international cooperative study on the timing of aneurysm surgery. Part 1: Overall management results. *J Neurosurg* 73:18-36, 1990.
15. Kassell NF, Torner JC, Jane J, Haley EC, Adams HP: The interna-

tional cooperative study on the timing of aneurysm surgery. Part 2: Surgical Results. *J Neurosurg* 73:37-47, 1990.

16. Locksley HB: Report of the cooperative study of intracranial aneurysms and subarachnoid hemorrhage. Section V. Part 1. Natural history of subarachnoid hemorrhage, intracranial aneurysms and arteriovenous malformations. Based on 6368 cases in the cooperative study. *J Neurosurg* 25:219-239, 1966.
17. Ljunggren B, Brandt L, Kagstrom E, Sundborg G: Results of early operation for ruptured aneurysms. *J Neurosurg* 54:473-479, 1981.
18. Newell DW, Le Roux PD, Dacey RG, Stimac GK, Winn HR: CT infusion scanning for the detection of cerebral aneurysms. *J Neurosurg* 71:175-179, 1989.
19. Papo I, Bodosi M, Dorci T: Intracerebral hematomas from aneurysm rupture: Their clinical significance. *Acta Neurochir (Wien)* 89:100-105, 1987.
20. Deleted in proof.
21. Pasqualin A, Bazzan A, Cavazzani P, Siconza R, Licata C, Da Pian R: Intracranial hematomas following aneurysmal rupture: Experience with 309 cases. *Surg Neurol* 25:6-17, 1986.
22. Samson D, Batjer HH: Intracerebral hematomas secondary to ruptured aneurysms and intracranial vascular malformations, in Kaufman HH (ed): *Intracerebral Hematomas*. New York, Raven Press, 1992, pp 75-84.
23. Saveland H, Hillman J, Brandt L, Edner G, Jakobsen KE, Algiers G: Overall outcome in aneurysmal subarachnoid hemorrhage. *J Neurosurg* 76:729-734, 1992.
24. Schmid UD, Steiger HJ, Huber P: Accuracy of high resolution computed tomography in direct diagnosis of cerebral aneurysms. *Neuroradiology* 29:152-159, 1987.
25. Tapaninaho A, Hernesniemi J, Vapalahti M: Emergency treatment of cerebral aneurysm with large hematomas. *Acta Neurochir (Wien)* 91:21-24, 1988.
26. Wheelock B, Weir B, Watts R, Mohr G, Khan M, Hunter M, Fewer D, Ferguson G, Durity F, Cochrane D, Benoit B: Timing of surgery for intracerebral hematomas due to aneurysm rupture. *J Neurosurg* 58:476-481, 1983.
27. Winn HR, Newell DW, Mayberg MR, Grady MS, Dacey RG, Eskridge J: Early surgical management of poor grade patients with intracranial aneurysms. *Clin Neurosurg* 36:289-298, 1990.

COMMENTS

The authors have provided a succinct presentation of a protocol for evaluation and management in this desperately ill group of patients. The value of infusion CT scans to confirm the source of hemorrhage is well demonstrated. The salvage rate they have achieved, particularly with one third of their patients

achieving an independent outcome, is good in comparison with the natural history, and supports their rapid and aggressive approach to these patients.

David G. Piepgras
Rochester, Minnesota

The authors have accomplished an aggressive and surprisingly successful management of a large series of comatose patients after subarachnoid and intraparenchymal hemorrhage. The authors have expanded a previously described principle of immediate craniotomy with empiric exploration of the appropriate subarachnoid space in lieu of angiography—a principle prompted by the significant time delay imposed by even single-vessel angiography. In its stead, they have performed infusion CT scanning, which clarified the site of the aneurysm in each patient with a time delay of only 10 to 15 minutes. That one third of their patients achieved an independent lifestyle despite moderate disability is a significant accomplishment. As the authors point out, the success of any acute surgical intervention in this form of cerebral vascular disease is dependent not only on an efficient hospital environment, but also on a well-equipped and well-educated paramedical service in the community and expeditious referral to a neurosurgical center. It is significant that the average interval between hemorrhage and skin incision was less than 5 hours.

The authors make several points that I believe are critical in the successful management of these patients. The aggressive use of decompressive lobectomy and craniectomy with dural patch grafting has proven in our experience to be extremely valuable. The impact of the acute hemorrhage results in substantial damage to the involved hemisphere that does not become manifest for 24 to 36 hours. A point is also made that the offending aneurysm must be clipped at the time of craniotomy, because of the loss of tamponading influence with evacuation of the hematoma. It is much less important and probably contraindicated in this setting to spend additional time securing unruptured lesions with inadequate diagnostic information due to the extremely low incidence of symptomatic vasospasm that could require hyperdynamic therapy.

H. Hunt Batjer
Dallas, Texas