

De novo fenestration of the optic nerve

Case illustration

PAUL A. HOUSE, M.D., AND WILLIAM T. COULDWELL, M.D., PH.D.

Department of Neurosurgery, University of Utah Health Sciences Center, Salt Lake City, Utah

KEY WORDS • optic nerve • fenestration • aneurysm

Fenestration of the optic nerve or chiasm due to the presence of an aneurysmal dilation of the internal carotid artery (ICA) has been described previously. In three of five cases reviewed recently, the optic nerve was penetrated by an ICA–ophthalmic artery aneurysm.³ Penetration of the optic nerve was due to a ruptured anterior communicating artery aneurysm or an aneurysm of the anterior wall of the ICA in the other cases published to date.^{2,4} Splitting of the optic nerve without the presence of a penetrating aneurysm has not been identified previously.

This 50-year-old woman was found to have multiple unruptured

aneurysms during an evaluation for refractory tinnitus and headaches. The patient harbored a complex 2-cm aneurysm of the left middle cerebral artery as well as an 8-mm aneurysm at the origin of the right posterior communicating artery. Each of the aneurysms was successfully obliterated with clip ligation during separate operations.

During surgery for the right-sided aneurysm, a unique structure of the medial left optic nerve and chiasm was identified (Fig. 1). The smaller portion of the optic nerve was dissected free of the investing arachnoid and was noted to course with the main portion of the nerve toward the optic canal. A cause of the split, such as a penetrating embryonic artery or osseous trabeculae, could not be identified.

Several mechanisms have been proposed to explain how an enlarging aneurysm might split the optic nerve. One mechanism would involve a congenital fenestration through which an aneurysm passes.⁴ Indeed, duplications of the optic canals have been identified in cadaveric specimens, indicating congenital optic nerve duplication is possible.¹ Nevertheless, because this case illustration is the first report we are aware of to demonstrate a de novo optic nerve fenestration, it would appear that congenital fenestrations are extremely rare.

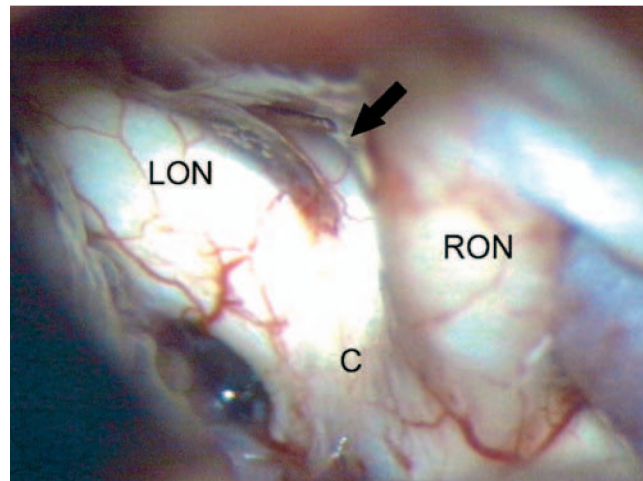


FIG. 1. Intraoperative photograph showing the left optic nerve (LON) and the right optic nerve (RON) joining in the chiasm (C). A unique third component (*arrow*) is seen joining the chiasm anteriorly. This nerve was dissected and found to course with the left optic nerve.

References

1. Choudhry R, Anand M, Choudhry S, Tuli A, Meenakshi A, Kalra A: Morphologic and imaging studies of duplicate optic canals in dry adult human skulls. *Surg Radiol Anat* 21:201–205, 1999
2. Date I, Akioka T, Ohmoto T: Penetration of the optic chiasm by a ruptured anterior communicating artery aneurysm. Case report. *J Neurosurg* 87:324–326, 1997
3. Jea A, Baskaya MK, Morcos JJ: Penetration of the optic nerve by an internal carotid artery-ophthalmic artery aneurysm: case report and literature review. *Neurosurgery* 53:996–1000, 2003
4. Kanamaru K, Ishida F, Taki W: Splitting and penetration of the optic nerve by an aneurysm arising from the anterior wall of internal carotid artery: case report. *J Neurol Neurosurg Psychiatry* 71:525–527, 2001

Manuscript received January 20, 2004; accepted in final form October 1, 2004.

Address reprint requests to: William T. Couldwell, M.D., Ph.D., Department of Neurosurgery, University of Utah, 3B-409 SOM, 30 North 1900 East, Salt Lake City, Utah 84132-2303. email: william.couldwell@hsc.utah.edu.