

Invasive Sinonasal Disease Due to *Scopulariopsis candida*: Case Report and Review of Scopulariopsosis

John D. Kriesel, Elisabeth E. Adderson,
W. M. Gooch III, and Andrew T. Pavia

From the Divisions of Infectious Diseases and Pediatric Infectious Diseases, and the Department of Pathology, The University of Utah School of Medicine, Salt Lake City, Utah

Sinonasal infection with fungi of the order Mucorales—termed *mucormycosis* or *zygomycosis*—is sometimes seen in immunosuppressed patients, including those with diabetic ketoacidosis and malignancy. We describe a case of invasive sinonasal infection with *Scopulariopsis candida* (not among the Mucorales organisms) in a 12-year-old girl who was being treated for non-Hodgkin's lymphoma. Only a few cases of invasive infection with *Scopulariopsis* species have been reported previously; five of six of these cases were associated with persistent or fatal disease. Our patient survived without undergoing radical surgical debridement and was treated with granulocyte colony-stimulating factor, amphotericin B, and itraconazole; chemotherapy was stopped. In vitro susceptibility testing of our patient's *Scopulariopsis* isolate showed that it was resistant to amphotericin B and that it was relatively susceptible to itraconazole and miconazole. The case described herein demonstrates the expanding spectrum of fungal organisms that may cause invasive sinonasal infection in immunocompromised hosts and the need for reliable antifungal susceptibility testing.

Since patients with malignancies are currently given intensive chemotherapy or undergo bone marrow transplantation, there are many patients today with profound and long-lasting immunosuppression [1]. Fungal infection of the sinuses and surrounding facial bones is a complication of immunosuppression that is difficult both to diagnose and to treat. We describe a case of invasive sinusitis with *Scopulariopsis candida* that mimicked mucormycosis (zygomycosis) in a 12-year-old immunocompromised girl who was treated with surgery and antifungal agents. To our knowledge, we report the first case of invasive scopulariopsis disease in an immunocompromised host that was successfully treated.

Case Report

A 12-year-old girl with non-Hodgkin's lymphoma presented on 28 December 1992 at the Primary Children's Medical Center, Salt Lake City, with a 1-week history of fever, myalgias, and swelling and tenderness of the right cheek. Her non-Hodgkin's lymphoma had been diagnosed at the same hospital in August 1992. Between August 1992 and December 1992, she had received chemotherapy four times. Her lymphoma went into remission, but in September 1992 she developed empyema and sinusitis and was treated with iv antibiotics. Sinusitis recurred in early December 1992, and

she was treated with peroral amoxicillin/clavulanate for 2 weeks. Both episodes of sinusitis followed periods of neutropenia; in both instances her condition improved with treatment.

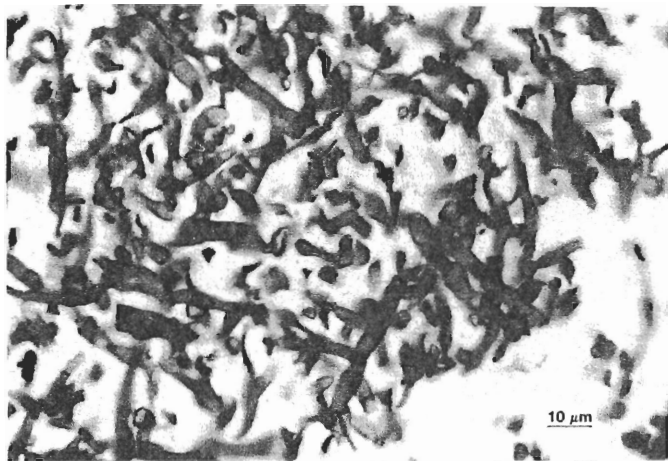
At the time of admission (28 December), no nasal drainage was noted. Her absolute neutrophil count was 100/ μ L. A computed tomogram showed opacified right frontal, ethmoidal, and maxillary sinuses with bony destruction involving the orbital floor and superior wall of the maxillary antrum. Immediate surgical drainage and debridement, including limited intranasal ethmoidectomy and maxillectomy, were performed. Necrosis of the medial maxilla and erosion of the nasal septum were noted. Pathological examination of specimens from the maxillary sinus showed large, tangled aggregates of fungal hyphae within fragments of devitalized bone. Because of extensive necrosis caused by abundant invasive forms of fungi, the presumptive diagnosis of mucormycosis (zygomycosis) was made (figure 1). Culture of five specimens from the maxillary sinus showed profuse growth of a tan, powdery mold that was identified by its morphological characteristics as *S. candida* (figure 2). Bacterial cultures of specimens from the maxillary sinus yielded *Staphylococcus aureus*, *Bacteroides oris*, α -hemolytic streptococci, and *Neisseria* species.

Therapy with amphotericin B (1.25 mg/[kg·d]) plus recombinant granulocyte colony-stimulating factor was begun immediately. Further cancer chemotherapy was withheld, and neutropenia resolved 1 week after admission. When the organism was identified as a *Scopulariopsis* species, itraconazole (500 mg/d in three divided doses) was added to the therapeutic regimen because of a concern about reported in vitro amphotericin B resistance. Coexistent bacterial sinusitis was treated with iv clindamycin for 3 weeks. Follow-up endo-

Received 7 July 1993; revised 14 January 1994.

Reprints or correspondence: Dr John D. Kriesel, Division of Infectious Diseases, The University of Utah School of Medicine, Room 4B-322, 50 North Medical Drive, Salt Lake City, Utah 84132.

Clinical Infectious Diseases 1994;19:317-9
© 1994 by The University of Chicago. All rights reserved.
1058-4838/94/1902-0022\$02.00



didia. Note the invasive, broad, branching septate hyphae (Grocott-Gomori methenamine-silver nitrate stain; original magnification, $\times 250$).

scopic sinus drainage and biopsy were performed twice at weekly intervals and again 5 months later. Amphotericin B therapy was stopped after a total dose of 3,000 mg was administered, and itraconazole therapy was continued for 6 months. At this time the patient is well and does not have progressive sinus disease or recurrent lymphoma. She has not received any more chemotherapy.

Discussion

Scopulariopsis species are saprobic, soil-inhabiting fungi related to *Penicillium* and *Paecilomyces* species; these organisms are hyaline (glassy) molds with septate hyphae. The word *scopula* is Greek for broom, which describes the striking shape of *Scopulariopsis* conidiophores (figure 2) [2]. Although the conidia of *Scopulariopsis brumptii* and *Scopulariopsis brevicaulis* are relatively rough-walled and truncate, isolated conidia of *S. candida* are characteristically smooth-walled and resemble simple yeasts. *Scopulariopsis* species are keratinophilic and a common cause of nail infection but only rarely cause deep-tissue infections [3].

The present report describes a case of invasive scopulargal forms in the pathological specimens and in cultures of maxillary sinus specimens strongly suggests that bacterial infection played a secondary role to *S. candida* in the course of infection. It is of interest that our patient's presentation mimicked the presentation typical of invasive rhinocerebral disease due to the nonseptate fungi of the order Mucorales, usually referred to as mucormycosis or zygomycosis. Infection with *Scopulariopsis* in immunocompromised patients

has resulted in disseminated infection and death or locally persistent infection at the time of autopsy despite aggressive therapy with amphotericin B (table 1) [2, 4-6]. To our knowledge, *S. candida* has not previously been identified in the literature as a cause of invasive infection, although prior reports have associated *S. brumptii* with hypersensitivity pneumonitis and brain abscess [6, 8] and *S. brevicaulis* with hyalohyphomycosis, nail infection, and keratitis [2, 3, 7].

In contrast with previously described patients with infections due to *Scopulariopsis* species, our patient survived without evidence of persistent disease. Her survival may be attributable in part to prompt local surgical debridement. Aggressive antimicrobial therapy with amphotericin B and itraconazole at relatively high doses also may have contributed to a prompt decrease in the underlying immunosuppression, which likely was the most important factor for controlling the scopulariopsis infection.

The role of fungal susceptibility testing in guiding therapy for deep mycoses has been controversial. Recently, a proposed standard for the in vitro susceptibility testing of yeasts and fungi was published [9]. However, methods for the susceptibility testing of filamentous fungi are just beginning to be standardized. The method employed for testing the *S. candida* isolate described in this report was a modification of the procedure of the National Committee for Clinical Laboratory Standards and was kindly performed by Dr. Michael Rinaldi (The University of Texas Health Sciences Center at San Antonio, Texas). As expected, both miconazole and

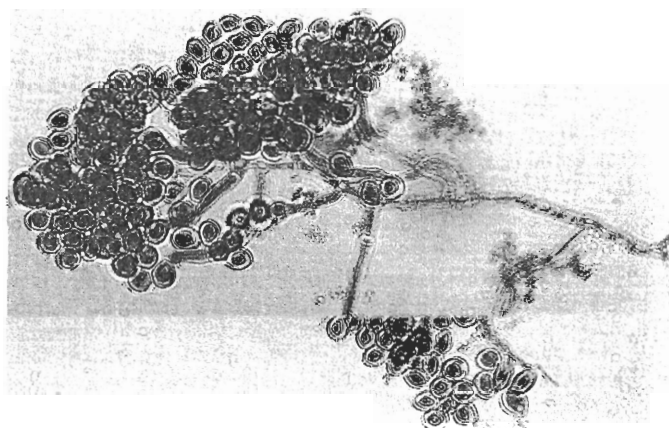


Figure 2. *Scopulariopsis candida* isolate from a patient with invasive sinonasal disease. This isolate was prepared by slide culture and staining with lactophenol aniline blue (original magnification, $\times 400$). Distinguishing features of this isolate include round, smooth conidia; septate hyphae; and broom-shaped conidiophores.

Table 1. Summary of data on seven cases of scopulariopsis infections reported in the literature (including the present report).

[Reference] patient age (y)	Isolate	Procedure or underlying disease	Site(s) of infection	Treatment	Outcome
[7] 26	<i>Scopulariopsis brevicaulis</i>	None	Cornea	Keratoplasty; intraocular, topical, and iv AmB; oral itraconazole	Cured
[5] 34	<i>Scopulariopsis</i> species	Acute leukemia	Lung	AmB (iv)	Died
[4] 17	<i>Scopulariopsis</i> species	Bone marrow transplant	Nasal septum, trachea, lungs, brain, blood	AmB (iv)	Died
[4] 28	<i>Scopulariopsis</i> species	Acute leukemia	Ear, mastoid (localized)	Local and iv AmB, oral Ket	Died
[2] 40	<i>S. brevicaulis</i>	Aplastic anemia	Great toe (localized)	AmB (iv)	Died
[6] 37	<i>Scopulariopsis brumptii</i>	Liver transplant	Brain	AmB (iv), miconazole (iv)	Died
[PR] 12	<i>Scopulariopsis candida</i>	Non-Hodgkin's lymphoma	Sinuses	AmB (iv), itraconazole (po), GCSF	Cured*

NOTE. AmB = amphotericin B; Ket = ketoconazole; PR = present report; and GCSF = granulocyte colony-stimulating factor.
* As of this writing.

itraconazole showed good inhibitory activity at 24 hours, but neither agent was found to be fungicidal (table 2). Measured serum levels of itraconazole (7.6 µg/mL) exceeded the MIC in vitro by about 400-fold. Amphotericin B showed surprisingly poor inhibitory and fungicidal activity, but since this drug was well tolerated by our patient and since previous reports suggested that cases of invasive scopulariopsis infection generally had a poor outcome, we elected to continue therapy with amphotericin B until a total dose of 3,000 mg was administered.

S. candida and *S. brevicaulis* as well as *Curvularia*, *Fusarium*, and *Bipolaris* species are now considered (like *Aspergillus* species and Zygomycetes) as causes of devastating invasive sinusitis in immunocompromised patients [1, 10]. *Scopulariopsis* species, like *Fusarium* and *Curvularia* species, are not reliably susceptible to amphotericin B in vitro. The emergence of these opportunistic fungi underscores the need to obtain adequate microbiological specimens from immunocompromised patients with sinusitis and to develop methods of reliably determining the in vitro susceptibilities to antifungal agents.

Table 2. Results of in vitro susceptibility testing of a *Scopulariopsis candida* isolate from a patient with invasive sinonasal disease.

Antifungal agent	MIC (µg/mL)		MFC (µg/mL)	
	24 h	48 h	24 h	48 h
Amphotericin B	1.16	4.62	9.24	>18.5
5-Fluorocytosine	>322
Fluconazole	>80
Miconazole	≤0.6	≤0.6	10	>20
Itraconazole	≤0.018	5.0	>10	...

NOTE. MFC = minimum fungicidal concentration; . = data not obtained.

Acknowledgments

The authors thank Dr. Michael Rinaldi for identifying the isolate and determining in vitro susceptibilities to antifungal agents, Helene Segal for preparing the slide culture, and Joe Marty for assisting with the photographs.

References

- Anaissie E, Bodey GP, Kantarjian H, et al. New spectrum of fungal infections in patients with cancer. *Rev Infect Dis* 1989;11:369-78.
- Phillips P, Wood WS, Phillips G, Rinaldi MG. Invasive hyalohyphomycosis caused by *Scopulariopsis brevicaulis* in a patient undergoing allogeneic bone marrow transplant. *Diagn Microbiol Infect Dis* 1989;12:429-32.
- Summerbell RC, Kane J, Krajden S. Onchomycosis, tinea pedis and tinea manuum caused by non-dermatophytic filamentous fungi. *Mycoses* 1989;32:609-19.
- Neglia JP, Hurd DD, Ferrieri P, Snover DC. Invasive *Scopulariopsis* in the immunocompromised host. *Am J Med* 1987;83:1163-6.
- Wheat LJ, Bartlett M, Ciccarelli M, Smith JW. Opportunistic *Scopulariopsis* pneumonia in an immunocompromised host. *South Med J* 1984;77:1608-9.
- Patel R, Gustaferra CA, Krom RA, Weisner RH, Roberts GD, Paya CV. Deep *Scopulariopsis* in the immunocompromised host [abstract no 76]. In: Final program and abstracts of the 31st annual meeting of the Infectious Diseases Society of America (New Orleans). Washington, DC: IDSA, 1993.
- Ragge NK, Hart JC, Easty DL, Tyers AG. A case of fungal keratitis caused by *Scopulariopsis brevicaulis*: treatment with antifungal agents and penetrating keratoplasty. *Br J Ophthalmol* 1990;74:561-2.
- Griehle HG, Rippon JW, Maliwan N, Daun V. Scopulariopsis and hypersensitivity pneumonitis in an addict. *Ann Intern Med* 1975;83:326-9.
- Galgiani JN, Bartlett MS, Espinel-Ingroff A, et al. National Committee for Clinical Laboratory Standards. Reference method for broth dilution antifungal susceptibility testing of yeasts: proposed standard. NCCLS document M27-P. Villanova, Pennsylvania: National Committee for Clinical Laboratory Standards, 1992.
- Morrison VA, Weisdorf DJ. *Alternaria*: a sinonasal pathogen of immunocompromised hosts. *Clin Infect Dis* 1993;16:265-70.