

## The Role of Thoracoscopic Spinal Surgery in the Management of Pyogenic Vertebral Osteomyelitis

Thomas Mückley, MD,\* Tanja Schütz, MD,\* Meic H. Schmidt, MD,† Michael Potulski, MD,\*  
Volker Bühren, MD,\* and Rudolf Beisse, MD\*

**Study Design.** Case report, operative technique.

**Objectives.** Vertebral osteomyelitis is frequently associated with elderly and debilitated patients who have significant medical comorbidities. If surgical debridement is contemplated, an open anterior approach like a thoracotomy can be associated with significant complications in this patient population. Thus, patients with vertebral osteomyelitis who need surgery may benefit from minimal invasive techniques that avoid the complications of more extensive open approaches. We performed thoracoscopic spinal surgery in patients with pyogenic vertebral osteomyelitis, attempting to reduce the morbidity attributable to standard open thoracotomy surgery.

**Methods.** The technique and results of minimally invasive thoracoscopic spinal surgery for pyogenic vertebral osteomyelitis in three patients, including radical debridement and anterior spinal reconstruction, are presented.

**Results.** Radical debridement and anterior spinal reconstruction are feasible *via* endoscopic approach. Standard thoracotomy or thoracoabdominal approaches associated with high morbidity can be avoided, even for fusion across multiple levels. Conversion to open technique was not necessary in this study. There was no recurrence of infection or loss of reduction during the follow-up period. Operative time and blood loss of endoscopic technique were comparable to open technique.

**Conclusions.** The cases clearly demonstrate the feasibility and efficacy of thoracoscopic spinal surgery in the management of pyogenic vertebral osteomyelitis. Debridement, decompression of the spinal canal, interbody fusion, and anterior spinal fixation can be performed *via* endoscopic approach. [Key words: thoracoscopic spinal surgery, minimally invasive technique, vertebral osteomyelitis, anterior spinal reconstruction] **Spine** 2004;29:E227–E233

Vertebral osteomyelitis accounts for approximately 2% to 4% of all cases of bone infection.<sup>1,2</sup> However, the incidence of vertebral osteomyelitis has been on the rise over the last decades.<sup>3–5</sup> This has been attributed to the increasing number of immunocompromised patients, intravenous drug abusers, the aging of the population, and

the recurrence of tuberculosis in industrialized countries.<sup>5–8</sup>

Treatment concepts of vertebral osteomyelitis are evolving, and spinal surgery is increasingly recognized as an important component.<sup>9,10</sup> Many uncomplicated cases may be successfully treated nonsurgically by spinal immobilization and antibiotics.<sup>11,12</sup> Disadvantages of nonsurgical therapy are prolonged immobilization and associated complications such as instability, progressive kyphotic deformity, persistent pain, and neurologic compromise.<sup>1,9,13,14</sup> Operative intervention is indicated in advanced stages with vertebral destruction, deformity, instability, abscess formation, symptomatic neural compression, and failure of conservative therapy.<sup>9,11,14,15</sup> The goals are to relieve pain, treat the infection with aggressive debridement, prevent or reverse neurologic deficit, and restore spinal stability.<sup>7,9,10,11,16</sup>

Many surgeons favor an anterior approach that allows for more direct access to the affected vertebral body for debridement and spinal decompression.<sup>11,14,15</sup> Thoracotomy has long been the standard approach to the anterior thoracic spine.<sup>17</sup> During the past two decades, minimally invasive thoracoscopic procedures have been established for anterior spinal surgery in an attempt to reduce morbidity attributable to standard thoracotomy. This includes incisional morbidity and pain, postoperative respiratory difficulties, and chronic post-thoracotomy pain.<sup>17–21</sup> However, the use of thoracoscopic spinal surgery has been largely limited to degenerative spinal disease and spinal trauma.

Based on our experience with thoracoscopic surgery in more than 500 spinal trauma cases, we thought that this technique could be applied to patients with osteomyelitis.<sup>22</sup> Clearly, these frequently debilitated patient groups with multiple medical comorbidities have a great potential to benefit from minimally invasive techniques if surgery is contemplated. We present our results of thoracoscopic treatment for pyogenic vertebral osteomyelitis in 3 patients, including radical debridement, decompression of the spinal canal, and anterior spinal reconstruction.

### ■ Case Reports

**Case 1.** A 41-year-old woman sustained T6 and T11 vertebral body fractures after a fall. She was initially treated conservatively with bracing. After 1 year, she developed thoracic pain, sensory deficit, and difficulties with walking. Her past medical history included alcohol and tobacco abuse. In addition, the patient was addicted to narcotic pain medications.

From the \*Departments of Surgery and Traumasurgery, Trauma Center Murnau, Murnau, Germany; and †Departments of Neurosurgery and Orthopedics, University of Utah, Salt Lake City, UT.

Acknowledgment date: March 5, 2003. First revision date: August 14, 2003. Acceptance date: October 17, 2003.

The manuscript submitted does not contain information about medical device(s)/drug(s).

No funds were received in support of this work. No benefits in any form have been or will be received from a commercial party related directly or indirectly to the subject of this manuscript.

Address correspondence to Thomas Mückley, MD, Trauma Center Murnau, Prof. Küntscher-Str. 8, 82418 Murnau, Germany; E-mail: T.Mueckley@gmx.de

**Table 1. Summary of patient data**

Case no.	Age (yrs), sex	Symptoms on admission	WBC count	CRP	Diagnosis	Thoracoscopic spinal surgery	Microbiology	Correction of kyphotic angle	Operative time/EBL	Follow-up (mo)
1	41, F	Persistent, severe pain, impaired sensibility	7.4	1.2	Vertebral spinal abscess	Partial corpectomy T6–T7, anterior decompression of the spinal cord fusion T5–T8, cage, plate	<i>Streptococcus agalactiae</i>	preoperative: 22°/ postoperative: 16°	270 min/ 850 mL	24
2	63, M	Persistent, severe lower back pain	11.6	5.0	Vertebral osteomyelitis T10–T11, vertebral body destruction T10, kyphotic deformity	Partial corpectomy T10–T11, fusion T9–T12, cage, double rod	Propionibacterium species	preoperative: 41°/ postoperative: 26°	195 min/ 650 mL	22
3	54, M	Persistent, severe lower back pain	17.7	5.8	Vertebral osteomyelitis T7–T8, vertebral body destruction T7	Posterior internal fixation, partial corpectomy T7, fusion T6–T8, cage, plate	Sterile	preoperative: 20°/ postoperative: 12°	150 min/ 500 mL	24

CRP = C-reactive protein; EBL = estimated blood loss.

Note: Laboratory normal limits: white blood cell (WBC) count (4.3–10.8/nL), CRP (0.0–0.5 mg/dL).

**Hospital Course.** On admission, the patient presented in poor health and had severe back pain. Infectious parameters were elevated (Table 1). Magnetic resonance imaging (MRI) revealed vertebral osteomyelitis at T6 and T7 with destruction of the vertebral bodies and paravertebral soft tissue infection. At T6–T7, a spinal abscess caused 30% canal compromise and associated spinal cord compression (Figure 1). Neurologic examination did not demonstrate a sensory or motor deficit.

Using a thoracoscopic approach, debridement and a partial corpectomy of T6 and T7 with decompression of the spinal cord were accomplished. Spinal stability was restored using an expandable titanium cage and a screw-plate fixation system (Figure 2). The cage was filled with autologous bone graft mixed with gentamycin-impregnated collagen sponge. Microbiology cultures yielded *Streptococcus agalactiae*. Levofloxacin was administered for 4 weeks.

Postoperative radiographic controls demonstrated improvement of kyphotic angle between T5 and T8 from 22° before surgery to 16° after surgery (Table 1). The patient was mobilized without brace on the first postoperative day and was subsequently discharged to a rehabilitation center after 3 weeks. Follow-up after 2 years showed no evidence of infection or loss of correction.

**Case 2.** A 63-year-old man with chronic low back pain had been treated with epidural steroid injections for 4 weeks. MRI scan revealed vertebral osteomyelitis at T10 and T11. Treatment with clindamycin was initiated at an outside hospital. Two months later, the patient presented to our hospital with increasing back pain. His past medical history included resection of a malignant bladder tumor 4 years ago.

**Hospital Course.** The patient complained of persistent severe back pain without neurologic deficit. Infectious parameters including C-reactive protein and white blood cells were elevated. His body temperature was measured at 37.5 C (Table 1). MRI demonstrated progression of the vertebral osteomyelitis. A CT-guided biopsy was obtained and the culture grew *Propionibacterium* species. Intravenous antibiotic therapy with linezolid was initiated (Figure 3). Thoracoscopic radical debridement with partial corpectomy of T10–T11 and anterior spinal reconstruction using a titanium cage filled with autologous bone graft and a double-rod anterior fixation system were performed (Figure 4). After surgery, the patient's back pain was

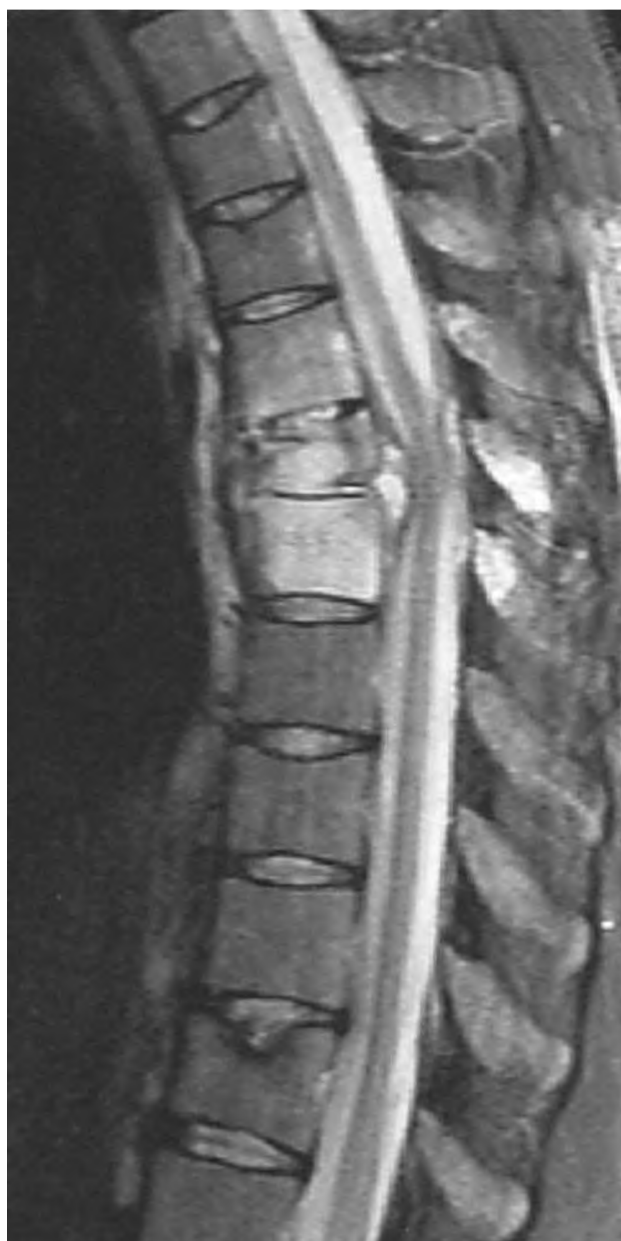

Figure 1. MRI demonstrating vertebral osteomyelitis T6 and T7 with spinal abscess causing compression of the spinal cord.

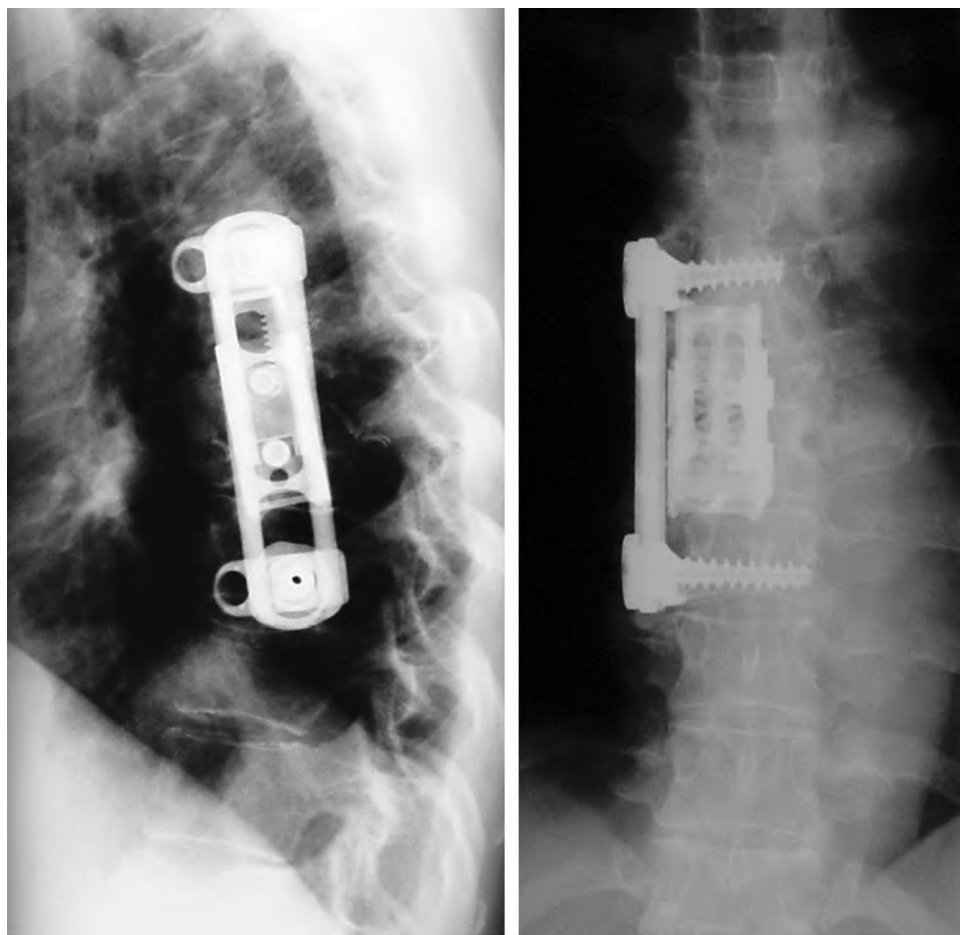


Figure 2. Anterior fusion from T5 to T8 with expandable titanium cage and screw-plate system following thoracoscopic debridement and anterior decompression of the spinal canal.

significantly reduced and he was able to ambulate without a brace. The kyphotic angle on lateral radiographs between T9 and T12 improved from  $41^\circ$  before surgery to  $26^\circ$  after surgery (Table 1). Antibiotic therapy was continued for 4 weeks. At the follow-up assessment after 22 months, the patient was pain-free. Infectious parameters were within normal limits and ra-

diographs demonstrated stable correction without evidence of instrumentation failure.

**Case 3.** A 54-year-old man with diabetes mellitus presented with persistent severe low back pain. This was associated with pain radiating into both arms and legs.

*Hospital Course.* The MRI demonstrated imaging findings consistent with vertebral osteomyelitis at T7–T8 and a paraspinous soft tissue infection. There was no evidence of spinal cord compression. Antibiotic treatment with intravenous clindamycin was started empirically.

After 3 weeks of antibiotics, he was readmitted because of increasing thoracic pain. Infectious parameters were elevated (Table 1). The repeat MRI study demonstrated progression of vertebral osteomyelitis with kyphotic deformity and destruction of the vertebral body at T7 (Figure 5). Initial spinal stabilization was achieved using posterior internal fixation from T5 to T9. The second-stage procedure consisted of a thoracoscopic partial corpectomy of T7 (Figure 6). The vertebral body was replaced with an expandable titanium cage. The cage was filled with autologous bone graft mixed with gentamycin-impregnated collagen sponge. Anterior fixation was achieved with a screw-plate system (Figure 7). The kyphotic angle on lateral radiographs between T6 and T8 was corrected from  $20^\circ$  before surgery to  $12^\circ$  after surgery (Table 1). Cultured specimens did not grow any organisms. After 2 weeks, the patient was discharged to a rehabilitation center. The patient remains

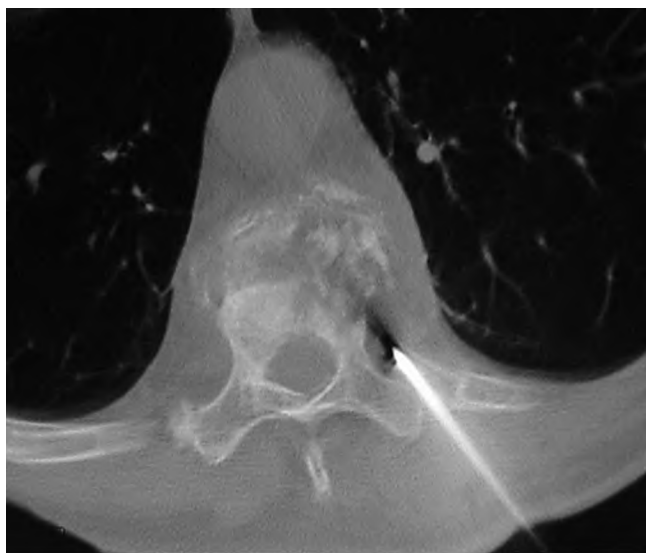


Figure 3. CT-guided biopsy of destruction of vertebral body T10.

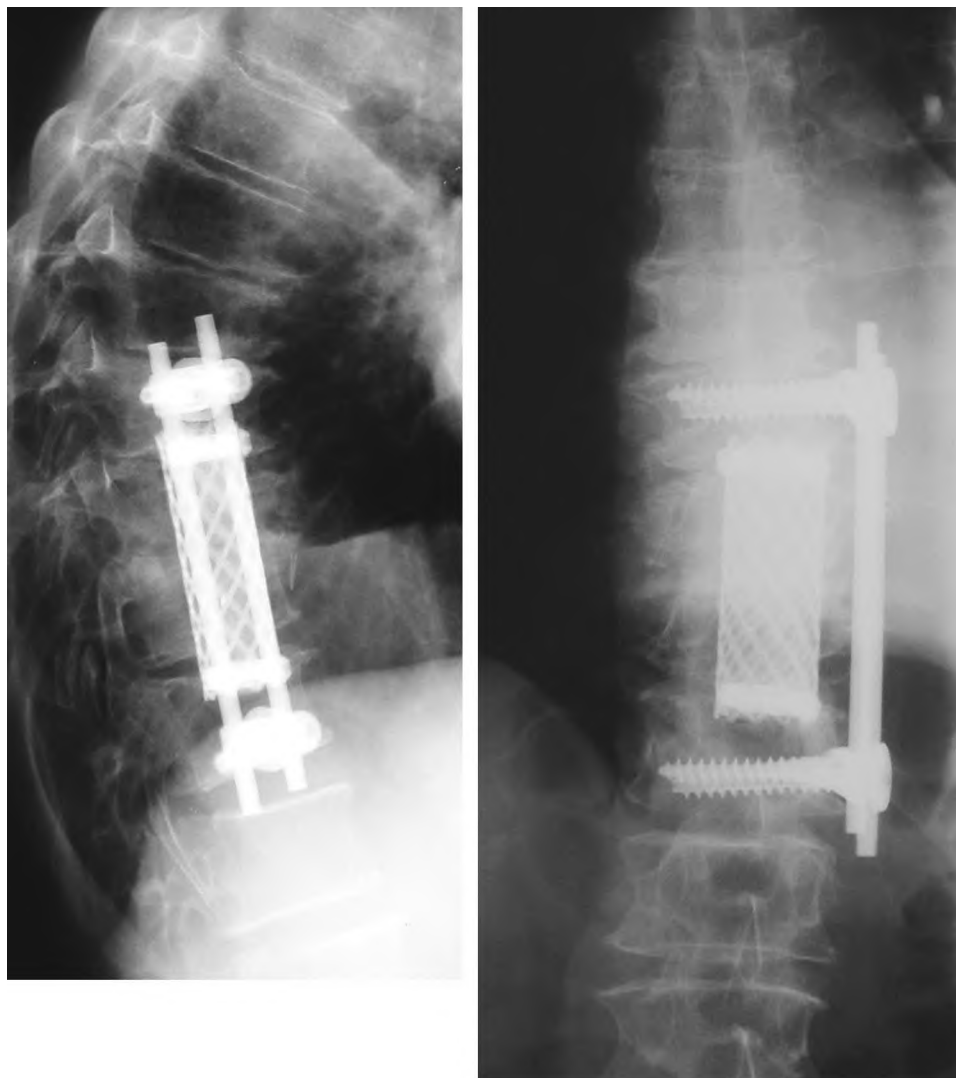


Figure 4. Thoracoscopic debridement T10 to T11 and anterior spinal reconstruction with titanium cage and double-rod system.

clinically and radiographically stable at the 24-month follow-up.

**Operative Technique.** The procedure is performed under general endotracheal anesthesia with a double-lumen tube. The patient is then placed in a true lateral decubitus position on a radiolucent table. The important first step is the precise localizing and marking of the trocar insertion sites on the thoracic wall under fluoroscopy on a lateral spine projection. The main portal (working channel) is placed directly over the diseased vertebral body. This can prevent complications from excessive bending of endoscopic instrumentation. Access to the thoracolumbar junction is gained by endoscopic splitting of the diaphragm, which has been described in detail in prior publications.<sup>22,23</sup> In contrast to common operative techniques, we insert the polyaxial screws for anterior plating before vertebral body resection (Figure 6). The screws can serve as landmarks and facilitate orientation in the operative field, increasing safety and reducing operative time.<sup>14,22</sup> The partial corpectomy is performed using standard endoscopic technique. If indicated, decompression of the spinal cord is also feasible *via* endoscopic technique.<sup>23</sup> Access to the posterior vertebral wall is achieved through resection of the ipsilateral pedicle, which allows for direct visualization of the dural sac. Retropulsed

bony fragments, intervertebral disc debris, and abscess material can be removed endoscopically as illustrated in Case 1.

The distraction of the titanium cage restores the anterior vertebral height and improves the kyphotic deformity. The cage is filled with autologous bone graft and antibiotic-impregnated collagen. Anterior fixation can be achieved by connecting either two rods or a plate to the polyaxial screws. The diaphragm needs to be reapproximated if it was taken down for exposure of the thoracolumbar junction. Before the closure of the incision, a 24-French chest tube is inserted. The patient begins ambulation after the chest tube is removed. Intravenous antibiotics are administered according to culture and sensitivity testing.

#### ■ Discussion

Despite the increasing incidence of vertebral osteomyelitis, optimal treatment concepts still remain controversial. Basic principles include nonoperative treatment with spinal immobilization and administration of antibiotics.<sup>12,13</sup> Considering the morbidity associated with prolonged bed rest, operative management of vertebral osteomyelitis has become more frequent in recent years.<sup>9</sup>

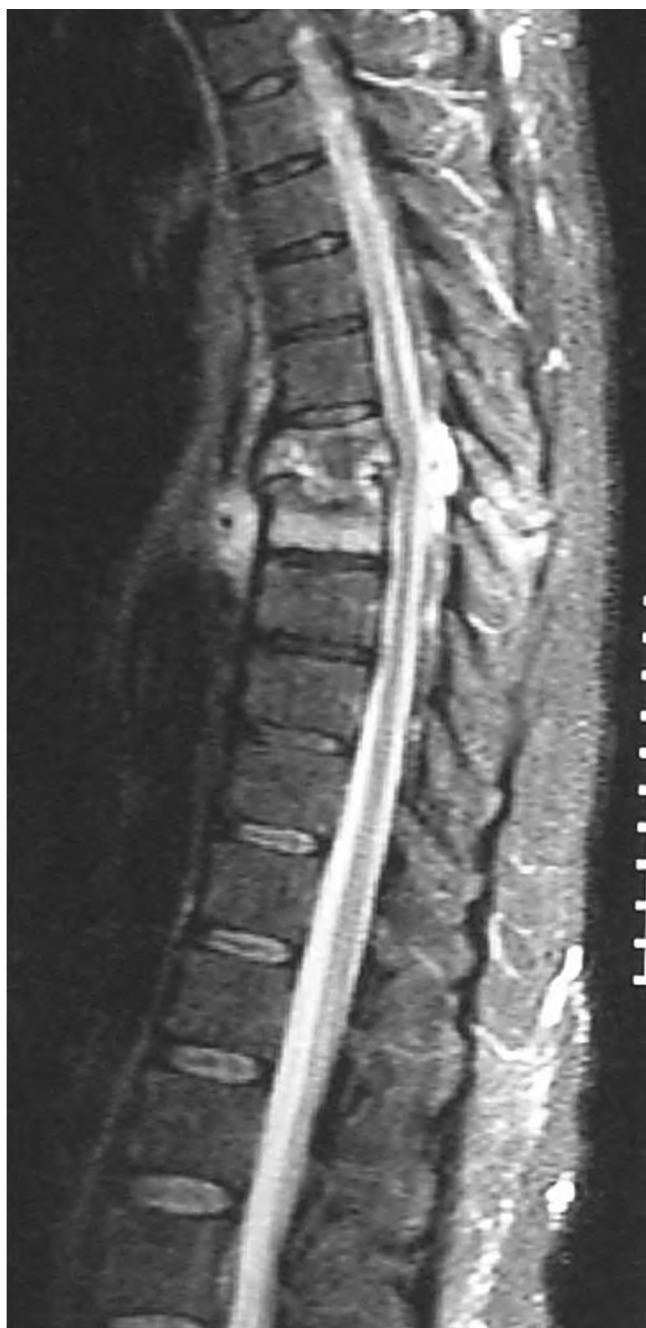

Figure 5. MRI demonstrating vertebral osteomyelitis T7 and T8 with kyphotic deformity and destruction of vertebral body T7.

Early ambulation and return to activities of daily living can result in improved functional outcome and patient satisfaction.<sup>12</sup>

The most commonly performed procedures that allow for debridement and reconstruction of the anterior column in the thoracolumbar spine are the anterolateral (transthoracic) and posterolateral (extracavitary) approaches.<sup>10</sup> The larger incisions required in these open procedures are not needed for thoracoscopic approaches. Several studies have confirmed the benefits of video-assisted thoracoscopic spinal surgery, including reduced postoperative pain and shoulder dysfunction,



Figure 6. Thoracoscopic view of partial corpectomy T7.

improved postoperative respiratory function, shorter hospital stay, and earlier ambulation compared to open surgery.<sup>17,20–22,24</sup> Video-assisted techniques provides a wide surgical field with a high degree of illumination and magnification and require only small incisions.<sup>17,18,22,25</sup>

In 1910, Jacobaeus was the first to use thoracoscopy.<sup>26</sup> Since the early 1990s, video-assisted thoracoscopic surgery has been established for minimally invasive lung resections, mediastinal procedures, or pericardectomy.<sup>17–20,22,27,28</sup> Video-assisted, minimally invasive procedures for anterior thoracic spine surgery were first described in 1993.<sup>29</sup> However, the use of spinal endoscopic techniques has been largely limited to degenerative and traumatic lesions.<sup>17,18,22,28</sup> To the best of our knowledge, there has been only one report on video-assisted thoracoscopic spine surgery in the management of tuberculous spondylitis.<sup>30</sup> This report describes a series of 10 patients. Complications included a nonunion and bone graft subsidence with increased kyphosis in 2 patients. One patient required a conversion to an open procedure. The technique used consisted of endoscopic debridement of the infected vertebral body and reconstruction with a tricortical bone graft. Anterior instrumentation for fixation was not used in that series.




Figure 7. Thoracoscopic view after anterior spinal reconstruction with expandable titanium cage and screw-plate system.

Other authors have reported their results of open anterior debridement followed by autologous bone graft without anterior fixation.<sup>9,31,32</sup> However, in anterior fusions with large bone grafts across multiple levels, the rate of graft dislocation increases and complications such as graft dislocation and secondary kyphosis may occur.<sup>33–35</sup> Anterior instrumentation may reduce the incidence of this complication and permits early ambulation of the patient.<sup>9</sup> In addition, the patient may not need an external brace. Thus, we routinely use a constrained screw-plate fixation system specifically developed for endoscopic spine surgery.<sup>22</sup> Our cases demonstrate that extensive debridement and anterior fusions over multiple levels are feasible with a minimally invasive thoracoscopic approach. Large incisions for standard thoracotomy or thoracoabdominal approaches can be avoided. The thoracoscopic approach can be extended to L2 *via* endoscopic splitting of the diaphragm.<sup>23</sup> A conversion to open technique was not necessary in this case series. However, the surgical team should be prepared to perform an open procedure in case of unexpected events. In all patients, the postoperative course was unremarkable without recurrence of infection or loss of postoperative kyphotic correction during the follow-up period. Operative time and blood loss of endoscopic technique were not increased compared with open procedures.<sup>22</sup> Additional anterior instrumentation allowed early rehabilitation without bracing and prevented secondary deformity.

We also would like to emphasize that endoscopic thoracic corpectomy and anterior instrumentation is a technically demanding procedure with a steep learning curve. Adequate manual coordination and precise orientation with the 30° angled endoscope are essential.<sup>17,18,22,30</sup> Specialized instruments and tools that are not routinely used for other surgical procedures are necessary to accomplish the same operative goals as in open surgery.<sup>28</sup> Anesthetic procedures, including single lung ventilation and central lines, require long preparation time, resulting in increased overall operative time.<sup>17</sup>

## ■ Conclusion

We were able to demonstrate the feasibility and efficacy of thoracoscopic spinal surgery in the management of pyogenic vertebral osteomyelitis. Radical debridement of the vertebral body, decompression of the spinal cord, and anterior spine reconstruction can be performed *via* endoscopic approach. Potential advantages of minimally invasive surgery compared with open technique include reduced postoperative pain, lower morbidity, and earlier patient mobilization. Soft tissue trauma is reduced and cosmetic results are convincing. Elderly patients frequently afflicted with chronic associated illnesses may particularly benefit from minimally invasive thoracoscopic technique.

## ■ Key Points

- Thoracoscopic spinal surgery is performed in 3 cases of pyogenic vertebral osteomyelitis.
- Radical debridement, decompression of the spinal canal, and anterior spinal reconstruction are feasible *via* endoscopic approach.
- Standard thoracotomy can be avoided, even for multilevel fusions.
- Operative time and blood loss are comparable to open technique.

## References

1. Kulkowski J. Pyogenic osteomyelitis of the spine: an analysis and discussion of 102 cases. *J Bone Joint Surg Am.* 1936;18:343–364.
2. Robinson BHB, Lessof MHJ. Osteomyelitis of the spine. *Guys Hosp Rep.* 1972;110:303–309.
3. Jones NS, Anderson DJ, Stiles PJ. A five-year study showing an increase in subacute osteomyelitis. *J Bone Joint Surg Br.* 1987;69:779–783.
4. Liebergall M, Chaimsky G, Lowe J, et al. Pyogenic vertebral osteomyelitis with paralysis: prognosis and treatment. *Clin Orthop.* 1991;269:142–150.
5. Rezai AR, Woo HH, Errico TJ, et al. Contemporary management of spinal osteomyelitis. *Neurosurgery.* 1999;44:1018–1026.
6. Calderone RR, Larsen JM. Overview and classification of spinal infections. *Orthop Clin North Am.* 1996;27:1–8.
7. Osenbach RK, Hitchon PW, Menezes AH. Diagnosis and management of pyogenic vertebral osteomyelitis in adults. *Surg Neurol.* 1990;33:266–275.
8. Patzakis MJ, Rao S, Wilkins J, et al. Analysis of 61 cases of vertebral osteomyelitis. *Clin Orthop.* 1991;264:178–183.
9. Hopf C, Meurer A, Eysel P, et al. Operative treatment of spondylodiscitis: what is the most effective approach? *Neurosurg Rev.* 1998;21:217–225.
10. Rath SA, Neff U, Schneider O, et al. Neurosurgical management of thoracic and lumbar vertebral osteomyelitis and discitis in adults: a review of 43 consecutive surgically treated patients. *Neurosurgery.* 1996;38:926–933.
11. Hadjipavlou AG, Mader JT, Necessary JT, et al. Hematogenous pyogenic spinal infections and their surgical management. *Spine.* 2000;25:1668–1679.
12. Vaccaro AR, Harris BM, Madigan L. Spinal infections, pyogenic osteomyelitis, and epidural abscess. In: Vaccaro AR, Betz RR, Zeidman SM, eds. *Principles and Practice of Spine Surgery.* St. Louis: Mosby, 2003:165–174.
13. Digby JM, Kersley JB. Pyogenic non-tuberculous spinal infection. *J Bone Joint Surg Br.* 1979;61:47–55.
14. Przybylski GJ, Sharan AD. Single-stage autogenous bone grafting and internal fixation in the surgical management of pyogenic discitis and vertebral osteomyelitis. *J Neurosurg.* 2001;94:1–7.
15. Graziano GP, Sidhu KS. Salvage reconstruction in acute and late sequelae from pyogenic thoracolumbar infection. *J Spinal Disord.* 1993;6:199–207.
16. Currier BL, Eismont FJ. Infections of the spine. In: Rothmann RH, Simeone FA, eds. *The Spine.* Philadelphia: Saunders, 1992:1319–1380.
17. Bühren V, Beisse R, Potulski M. Minimal-invasive ventrale Spondylodese bei Verletzungen der Brust- und Lendenwirbelsäule. *Chirurg.* 1997;68:1076–1084.
18. Potulski M, Beisse R, Bühren V. Die thorakoskopisch gesteuerte Behandlung der “vorderen Säule”: Technik und Ergebnisse. *Orthopäde.* 1999;28:723–730.
19. Regan JJ, Ben-Yishay A, Mack MJ. Video-assisted thoracoscopic excision of herniated thoracic disc: description of technique and preliminary experience in the first 29 cases. *J Spinal Disord.* 1998;11:183–191.
20. Rosenthal D, Dickman CA. Thoracoscopic microsurgical excision of herniated thoracic discs. *J Neurosurg.* 1998;89:224–235.
21. Visocchi M, Masferrer R, Sonntag VKH, et al. Thoracoscopic approaches to the thoracic spine. *Acta Neurochir.* 1998;140:737–744.
22. Beisse R, Potulski M, Bühren V. Endoscopic techniques for the management of spinal trauma. *Eur J Trauma.* 2001;27:275–291.
23. Beisse R, Potulski M, Temme C, et al. Endoscopic controlled splitting of the diaphragm: a minimal invasive approach for the treatment of thoracolumbar fractures of the spine. *Unfallchirurg.* 1998;101:619–627.
24. Cunningham BW, Kotani Y, McNulty PS, et al. Video-assisted thoracoscopic

- surgery versus open thoracotomy for anterior thoracic spinal fusion. *Spine*. 1998;23:1333-1340.
25. Caputy A, Starr J, Riedel C. Video-assisted endoscopic spinal surgery: thoracoscopic discectomy. *Acta Neurochir*. 1995;134:196-199.
  26. Jacobaeus HC. Über die Möglichkeit, die Zystoskopie bei der Untersuchung seröser Höhlen anzuwenden. *Münch Med Wochenschr*. 1910;57:2090-2092.
  27. Krasna MJ, Mack MJ. *Atlas of Thoracoscopic Surgery*. St. Louis: Quality, 1994.
  28. McAfee PC, Regan JR, Zdeblick T, et al. The incidence of complications in endoscopic anterior thoracolumbar spinal reconstructive surgery. *Spine*. 1995;20:1624-1632.
  29. Mack MJ, Regan J, Bobechko WP, et al. Application of thoracoscopy for diseases of spine. *Ann Thorac Surg*. 1993;56:736-738.
  30. Huang TJ, Hsu RW, Chen SH, et al. Video-assisted thoracoscopic surgery in managing tuberculous spondylitis. *Clin Orthop*. 2000;379:143-153.
  31. Hodgson AR, Stock FE. Anterior spine fusion for the treatment of tuberculosis of the spine. *J Bone Joint Surg Am*. 1960;42:295-310.
  32. Ito H, Tsuchiy J, Asami G. A new radical operation for Potts disease. *J Bone Joint Surg Am*. 1934;16:499-511.
  33. Lifeso RM, Weaver P, Harder EH. Tuberculous spondylitis in adults. *J Bone Joint Surg Am*. 1985;67:1405-1413.
  34. Oga M, Arizono T, Takasita M, et al. Evaluation of the risk of instrumentation as a foreign body in spinal tuberculosis. *Spine*. 1993;18:1890-1894.
  35. Rajasekaran S, Soundarapandian. Progression of kyphosis in tuberculosis of the spine treated by anterior arthrodesis. *J Bone Joint Surg Am*. 1989;71:1314-1323.