

Ubiquitous expression of cyclooxygenase-2 in meningiomas and decrease in cell growth following in vitro treatment with the inhibitor celecoxib: potential therapeutic application

BRIAN T. RAGEL, M.D., RANDY L. JENSEN, M.D., PH.D., DAVID L. GILLESPIE, PH.D.,
STEPHEN M. PRESCOTT, M.D., PH.D., AND WILLIAM T. COULDWELL, M.D., PH.D.

Department of Neurosurgery, University of Utah; and Huntsman Cancer Institute, Salt Lake City, Utah

Object. Meningiomas are the second most common symptomatic primary central nervous system tumor in adults. Findings of epidemiological studies link meningiomas with a history of head trauma, indicating a causal relationship between the inflammatory response and meningioma tumorigenesis. Cyclooxygenase-2 (COX-2), an inducible inflammatory enzyme, converts arachidonic acid to prostaglandins, which have angiogenic, cell-proliferative, and antiapoptotic effects. The authors investigated COX-2 expression in meningiomas and the effects of celecoxib, a COX-2 inhibitor, on meningioma cell growth in vitro.

Methods. Four meningioma surgical specimens were immunohistochemically stained and graded (0 to 4) for COX-2. In addition, a Western blot analysis was performed to detect the presence of COX-2. Human meningioma cells grown in cell culture were treated with vehicle or celecoxib (0.25–1 mM). An immunohistochemical analysis of COX-2, a methylthiotetrazole cell proliferation assay, a TUNEL apoptosis assay, and a Western blot analysis for the proapoptotic protein BAX were performed in vitro.

One hundred eleven (87%) of 128 benign meningiomas and six (86%) of seven atypical meningiomas displayed a high COX-2 immunoreactivity (Grade 4 staining). In the Western blot analysis all four surgical specimens (100%) stained positive for a 70-kD band consistent with COX-2. Celecoxib inhibited cell growth in a dose-dependent fashion and induced apoptosis by Day 2, with no change noted in the expression of the BAX protein.

Conclusions. The COX-2 enzyme is universally expressed in meningiomas. Celecoxib inhibits meningioma growth in vitro in a dose-dependent fashion, with evidence of apoptosis. Inhibitors of COX-2 may have a role in the treatment of recurrent meningiomas.

KEY WORDS • meningioma • cyclooxygenase-2 • celecoxib

MENINGIOMAS are the second most common symptomatic adult central nervous system tumor, accounting for approximately 20% of all primary intracranial tumors in adults. Meningioma progression or recurrence occurs because of the aggressive biology of the tumor or because the lesion is found in an unresectable location.^{6,27,48} Recurrence rates for benign meningiomas 5 years after their complete removal have been reported to be 2 to 3%, whereas recurrence rates for atypical and anaplastic meningiomas have been reported to be 38 to 50% and 33 to 78%, respectively.^{14,34} Treatment options for recurrent meningiomas include additional surgery, conventional external-beam radiation therapy, stereotactic radiosurgery, and systemic therapies.^{12,33,44,45} Unfortunately, radiation therapy is limited by radiation neurotoxicity, tumor size, and injury to adjacent vascular or cranial nerves.^{3,12} To date, chemo-

therapies have proved to be ineffective in controlling recurrent meningiomas and new treatments should be explored.^{5,29,44,45,47}

Findings of several epidemiological studies have demonstrated a link between meningioma tumors and a history of head trauma; from this we may infer a causal relationship between the inflammatory response and future meningioma formation.^{2,35,39,42,43} Cyclooxygenase-2, an inducible inflammatory response enzyme, has been shown to be upregulated in animal head trauma models.^{23,24} Cyclooxygenase is the rate-limiting enzyme in the synthesis of prostaglandins from arachidonic acid.³⁷ The prostaglandins are involved in a variety of biological activities, such as angiogenesis, increased cell proliferation, and suppression of apoptosis. The enzyme COX-2 is induced by migratory cells (for example, macrophages, monocytes, and microglia) responding to proinflammatory stimuli and is considered to be an important mediator of acute and chronic inflammatory states.^{10,13,31} Overexpression of COX-2 has been closely linked to the tumorigenesis of colon, lung, and breast cancers.^{41,51}

A growing body of literature supports the use of NSAIDs and selective COX-2 inhibitors in the treatment of an increasing number of cancers. The NSAIDs exert their antiin-

Abbreviations used in this paper: COX = cyclooxygenase; DMSO = dimethyl sulfoxide; DPBS = Dulbecco phosphate-buffered saline; MTT = monothiazolium; NSAID = nonsteroidal antiinflammatory drug; TUNEL = terminal deoxynucleotidyl transferase-mediated deoxyuridine triphosphate nick-end labeling; WHO = World Health Organization.

COX-2 universally expressed in meningiomas

flammatory action by inhibiting the activity of the COX enzyme, which in turn results in decreased synthesis of the proinflammatory prostaglandins.¹³ The ability of NSAIDs to inhibit the COX enzyme is considered to be their major, but not sole, mode of function.¹³ Celecoxib (Celebrex; Pfizer, Inc., New York, NY) is a specific COX-2 inhibitor that acts slowly, time-dependently, and irreversibly.¹³

In this article, we demonstrate the ubiquitous expression of COX-2 by immunohistochemical staining and Western blot analysis and describe our initial findings on the effects of celecoxib on meningioma cells grown in vitro.

Materials and Methods

Meningioma Surgical Specimens

Meningioma surgical specimens were obtained in accordance with the University of Utah Institutional Review Board protocol and were processed for immunohistochemical, cell culture, and Western blot analyses. Specimens that were not used for cell cultures were stored at -70°C . Tumors were graded according to WHO criteria.²⁷ For the purposes of this paper, we will use the term "benign meningioma" to describe a WHO Grade I meningioma.²⁷ Patient data associated with paraffin-stained tissue and the in vitro studies are listed in Table 1.

Immunohistochemical Staining for COX-2

Four-micrometer-thick paraffin slides containing human meningiomas were obtained from the pathology department. Normal dura mater (that is, tissue obtained from a patient who underwent temporal lobectomy for intractable seizures), colon cancer, normal colon, breast cancer, and normal breast samples were used as positive and negative controls.⁸ Slides containing tissue were warmed for 20 minutes at 35°C and deparaffinized by bathing them with a series of xylene and alcohol solutions. We used Vectastain Elite Rabbit Kits (Vector Laboratories, Burlingame, CA), following the manufacturer's suggested staining protocol. Briefly, the slides were treated with an antigen unmasking solution (Unmasking citrate buffer solution; Vector Laboratories), heated in a microwave on high setting for 10 minutes, and cooled for 20 minutes. The slides were then rinsed with DPBS and bathed in a 1% H_2O_2 solution for 10 minutes to quench endogenous peroxidases. This was followed by a DPBS rinse and a 20-minute treatment with the rabbit blocking solution that was supplied by the manufacturer. After an additional DPBS rinse, the slides were incubated overnight at 4°C in primary COX-2 rabbit polyclonal antibody (sc-7951; Santa Cruz Engineering, Santa Cruz, CA) at a dilution of 1:200. Following an incubation with the primary antibody, the slides were rinsed in DPBS and treated with the supplied biotinylated secondary anti-rabbit antibody for 30 minutes. The tissue was again rinsed with DPBS and incubated for 30 minutes with premixed avidin-biotin-peroxidase complex (ABC; Vector Laboratories). The final immunohistochemical staining was performed using the 3,3'-diaminobenzidine (DAB; Vector Laboratories) method for 8 minutes to obtain a reaction to the ABC. The slides were rinsed in 0.5 M Tris buffer at pH 6, counterstained with 1% toluidine blue for 15 seconds, and dehydrated by bathing them in a series of increasing concentrations of alcohol and xylene. Permount and coverslips were then applied to the slides containing the tissue.

Grading of Immunohistochemical Staining

The tissue on the slides was graded on the basis of a five-point scoring system demonstrating the percentage of cells that demonstrated stain. The scores were as follows: 0, no staining noted; 1, less than 1% of cells stained; 2, 1 to 10% of cells stained; 3, 11 to 50% of cells stained; and 4, more than 50% of cells stained. This scoring system has been described previously.¹⁷

Protein Extraction

Isolated COX-2 protein was obtained from surgical specimens

TABLE 1

Characteristics of 135 patients with meningiomas

| Characteristic | Value |
|----------------------------------------------|-------------|
| no. of patients | 135 |
| sex. no. of patients (%) | |
| male | 48 (36) |
| female | 87 (64) |
| age (yrs) | |
| mean | 56 ± 15 |
| range | 22–88 |
| histological diagnosis. no. of patients (%)* | |
| benign | 128 (95) |
| atypical | 7 (5) |
| malignant | 0 (0) |

* Meningiomas were graded according to WHO guidelines.

and meningioma cells grown in vitro. Surgical specimens were obtained from our cryogenic tumor bank. Meningioma cells were grown in vitro as described later in this section. Surgical specimens (0.3–0.5 g) were homogenized with the aid of a tissue homogenizer and 3 ml of tissue homogenizing buffer (10 mM HEPES at pH 7.5, 2 mM dithiothreitol, 1 mM NaVO_3 , $1 \times$ protease inhibitor, 100 mM NaF , 0.4 mM phenylmethylsulfonyl fluoride, 0.1 mM ethylene-glycol-bis (β -aminoethylether)-N,N,N',N'-tetraacetic acid, and 10 mM $\text{Na}_2\text{P}_2\text{O}_7$). Cells grown in vitro were rinsed with ice-cold DPBS, scraped from the culture dish, pelleted at 580 G for 5 minutes, resuspended in 1 ml of homogenizing buffer (DPBS at 7.4 pH, 0.01% NP-100, $1 \times$ protease inhibitors), and sonicated for 10 seconds three times. Specimens (homogenized surgical specimens or sonicated cells grown in vitro) were pelleted at 580 G for 5 minutes at 4°C . The supernatant was removed to a new tube and centrifuged a second time. The resulting two pellets were combined and 150 to 300 μl of ice-cold lysis buffer (20 mM HEPES at pH 7.5, 400 mM NaCl , 10 mM NaF , 10 mM 4-nitrophenyl phosphate, 1 mM NaVO_3 , 0.1 mM ethylenediaminetetraacetic acid, 10 μM Na_2MoO_4 , 10 mM β -glycerophosphate, and 20% glycerol) was added. Glycerol was added to the supernatant to make a 5% solution, which was then held on ice for 5 minutes and centrifuged at 15,000 G. The resulting nuclear pellet was resuspended in three volumes of ice-cold lysis buffer, and both nuclear and cytoplasmic fractions were shaken vigorously at 4°C for 30 minutes. Cellular debris was pelleted by centrifugation at 30,000 G at 4°C for 20 minutes. The nuclear and cytoplasmic supernatant was removed and stored at -80°C until use.

Western Blot Analysis for COX-2 and BAX

The total protein concentration of the cellular extract described earlier was measured spectrophotometrically in 96-well plates by using the DC Total Protein Assay (Bio-Rad Laboratories, Hercules, CA) and calculated using a benchmark microplate reader (Bio-Rad Laboratories). Equal amounts of protein ($\sim 35 \mu\text{g}$) were resolved using sodium dodecyl sulfate-polyacrylamide gel electrophoresis (4–12% continuous gradient) and transferred to polyvinylidene difluoride Hybond-P membrane (Amersham Pharmacia, Piscataway, NY). The membrane was blocked and probed using a COX-2 rabbit polyclonal antibody (dilution 1:500, sc-7951; Santa Cruz Engineering), a BAX mouse monoclonal antibody (dilution 1:100, sc-7480; Santa Cruz Engineering), and a mouse immunoglobulin G antiactin monoclonal antibody (1:5000 dilution, MAB 1501; Chemicon International, Inc., Temecula, CA). The Western blots were visualized using ECL+ chemiluminescent reagents (Amersham Pharmacia) and X-OMAT film (Eastman-Kodak, Rochester, NY).

Meningioma Cell Culture

Tumor specimens were obtained from patients with meningiomas and grown in monolayer cultures as described previously.^{15,16} Briefly, specimens obtained at surgery were taken immediately from the operating room, digested in collagenase, and placed in Dulbecco mod-

TABLE 2
*Immunoreactivity grades of human meningioma specimens
 grown in cell culture and immunohistochemically
 stained for COX-2*

| Age (yrs), Sex* | Tumor Grade | Immunoreactivity Grade† |
|-------------------|-------------|-------------------------|
| 61, M, (IOMM-Lee) | malignant | 4 |
| 47, F | benign | 4 |
| 55, M | benign | 4 |
| 38, F | benign | 4 |
| 71, M | benign | 4 |

* Age and sex of the patient from when the specimen was obtained.

† See *Grading of Immunohistochemical Staining* for a complete explanation of staining grades.

ified Eagle medium (Sigma Chemical Co., St. Louis, MO) supplemented with 10% fetal calf serum, L-glutamine (2 μ M), penicillin (50 IU/ml), and streptomycin (50 mg/ml). The cultured cells were maintained at 37°C in 7.5% CO₂. Only cells in Passages 1 through 4 were used in experiments for this study.

Meningiomas grown in vitro have previously been characterized on microscopic, immunohistochemical, and ultrastructural levels.^{15,16,46} According to these studies, cell cultures derived from meningioma surgical samples appear to be of leptomeningeal origin. This conclusion is based on the cells' polygonal shape, negative staining for glial fibrillary acidic protein, and positive staining for vimentin and epithelial membrane antigen, as well as the presence of desmosomes identified using an electron microscope.^{15,16,46} Low-passage cells (that is, cells that have been subcultured no more than four times [Passage 4]) were used for these experiments, making fibroblast overgrowth less likely. Furthermore, G-band karyotyping was performed on four of the six cell lines studied for growth inhibition studies, with chromosomal abnormalities typical of meningiomas found in three (for example, the loss of chromosomes 22 and 1, and the addition of chromosomes 9q and 12q).³ Finally, several cell lines used for in vitro experiments were transplanted into the flanks of nude mice for in vivo experiments, and histologically these xenograft tumors resemble meningiomas (data not shown).

The human malignant meningioma cell line IOMM-Lee was a kind gift from Dr. Ian McCutcheon (M. D. Anderson Cancer Center, Houston, TX) and was grown in Dulbecco modified Eagle medium supplemented with 10% fetal calf serum, L-glutamine (2 μ M), penicillin (50 IU/ml), and streptomycin (50 mg/ml) at 37°C in 7.5% CO₂.²⁵

Karyotyping: G-Band Chromosome Analysis

The IOMM-Lee cell line and three primary meningioma cell lines were grown in T-175 flasks to 80% confluence and processed by the University of Utah Cytogenetics Laboratory (Salt Lake City, UT) for G-band chromosome analysis. All three primary meningioma cell cultures were processed for karyotyping by their third cell culture passage.

In Vitro Immunohistochemical Staining for COX-2

An immunohistochemical analysis was performed on meningioma cells grown in a monolayer culture. The cells were subjected to trypsin treatment, plated in eight-well plastic slides, and allowed to remain in growth media for 2 to 3 days as described earlier. The Ecr293 cell line with an inducible COX-2 vector was also plated for use as a positive control.⁷ After removal of the growth media, methanol maintained at -10°C was added to each well for 10 minutes. After the methanol had been removed, the cells were allowed to air dry for 30 minutes at room temperature. The slides were rinsed with DPBS and bathed in 1% H₂O₂ solution for 10 minutes to quench endogenous peroxidases. This was followed by a DPBS rinse and treatment with 10% goat blocking serum for 30 minutes. After an additional DPBS rinse, the slides were incubated overnight at 4°C in the

primary COX-2 rabbit polyclonal antibody (sc-7951; Santa Cruz Engineering) at a dilution of 1:50. Following incubation with the primary antibody, the slides were rinsed in DPBS and treated with a biotinylated secondary anti-rabbit antibody (Vectastain Elite Rabbit Kits, Vector Laboratories) for 30 minutes. The slides were again rinsed with DPBS and incubated for 30 minutes with premixed ABC. The final immunohistochemical staining was accomplished using a 10-minute DAB reaction to ABC. The slides were first rinsed in 0.5 M Tris buffer, pH 6, then rinsed in DPBS and distilled H₂O, and mounted in an aqueous solution.

Celecoxib Preparation

Purified celecoxib was a kind gift from Myriad Genetics, Salt Lake City, Utah.³⁸ Celecoxib powder was dissolved in DMSO at 1000 mM and used as stock solution for all the in vitro experiments. A final concentration of 0.1% DMSO was obtained for all experiments.

Growth Inhibition Studies

Growth inhibition studies with varying concentrations of celecoxib (0.25–1 mM) were performed on six meningiomas grown in vitro (that is, the IOMM-Lee cell line and five benign primary meningiomas). Cell counts were determined using both a bright-line hemocytometer and the MTT assay.

Cells that had been counted using a bright-line hemocytometer were placed in 12-well bottom plates at varying densities. The IOMM-Lee cell line was plated at a density of 3×10^3 per well, whereas the benign cell lines were plated at densities of 3 to 4×10^3 per well. Cells were treated in triplicate with either 0.1% DMSO vehicle (control group) or increasing doses of celecoxib (0.25 mM, 0.5 mM, and 1 mM). Media and drug were changed daily until the cells were harvested for cell counts. Cells were harvested at varying time points (0, 1, 2, and 3 days) by rinsing the wells with DPBS, dislodging the cells by incubating them in 0.5 ml of Accutase (MP Biomedicals, Irvine, CA) for 1 hour, declumping the cells by pipetting five times, and adding 5 μ l of trypan blue before counting the number of cells per milliliter; the last step was performed in duplicate. Cells that were colored with trypan blue were excluded.

Cell viability was measured by performing a colorimetric MTT assay as recommended by the manufacturer (MTT Cell Proliferation Assay; American Type Culture Collection, Manassas, VA). The cells were placed in 96-well bottom titer plates at a density of 2×10^3 cells per well and treated in triplicate with either 0.1% DMSO vehicle (control) or increasing doses of celecoxib (0.25, 0.5, and 1 mM). The MTT labeling reagent was added at various time points (1, 2, and 3 days) and allowed to react for 2 hours in the cell incubator. The supplied MTT detergent was added, and the cells were solubilized overnight at room temperature. A microtiter plate reader was used to perform the colorimetric evaluation at 570 nm. Cell viability was calculated by performing the MTT assay of absorbance in triplicate. Normalized values for the percentage of viable cells were calculated by dividing the cell count in celecoxib-treated groups by the mean cell count of three control (DMSO only) groups.

The TUNEL Assay

Meningiomas were grown on plastic slides and treated with vehicle (0.1% DMSO) or 1 mM celecoxib. The cell cultures were fixed with 10% formalin on Day 1 or 2 and the TUNEL assay (Promega, Madison, WI) was performed as recommended; the fragmented DNA of apoptotic cells stained brown.

Expression of BAX Protein After Celecoxib Treatment In Vitro

Four meningioma cell lines (IOMM-Lee and three WHO Grade I meningiomas) were plated in T-175 flasks, allowed to grow to 80% confluence, and treated with vehicle (0.1% DMSO) or 1 mM celecoxib for 48 hours. The lanes were loaded with 35 μ g of protein from whole-cell lysate and probed with the anti-BAX antibody (23 kD) as described earlier.

Statistical Analysis

In vitro cell counts were statistically analyzed using the Student

COX-2 universally expressed in meningiomas

TABLE 3

Immunoreactivity grades of 135 human meningiomas immunohistochemically stained for COX-2

| WHO Tumor Grade | Immunoreactivity Grade—No. (%) [*] | | | | | Total |
|-----------------|---------------------------------------------|-------|-------|---------|----------|-----------|
| | 0 | 1 | 2 | 3 | 4 | |
| benign | 0 (0) | 0 (0) | 1 (1) | 16 (12) | 111 (82) | 128 (95) |
| atypical | 0 (0) | 0 (0) | 0 (0) | 1 (1) | 6 (4) | 7 (5) |
| malignant | 0 (0) | 0 (0) | 0 (0) | 0 (0) | 0 (0) | 0 (0) |
| total | 0 (0) | 0 (0) | 1 (1) | 17 (13) | 117 (87) | 135 (100) |

* Grading: 0 and 1 = negative for COX-2; 2 through 4 = positive for COX-2. See *Grading of Immunohistochemical Staining* for a complete explanation of staining grades.

t-test (unpaired, two-tailed t-test, with confidence intervals set to 95%) to compare the control and celecoxib-treated groups. Statistical significance was set at a probability value less than 0.05 (Prism version 4.0; GraphPad Software, Inc., San Diego, CA).

Results

Patient Demographics and Tumor Characteristics

Of the 135 patients studied, 64% were women and the patients ranged in age from 22 to 88 years with a median of 56 years (Table 1). Most tumors were histologically benign; there were only seven atypical and no anaplastic meningiomas. For the *in vitro* immunohistochemical staining studies, five cell lines were grown in monolayer cultures. Sixty percent of the cell lines had been obtained from male patients; the cell lines were derived from four benign meningiomas and one malignant (IOMM-Lee) tumor (Table 2).²⁵ The G-band karyotyping was performed on three of six cell lines grown in culture for growth inhibition studies. Karyotyping of the IOMM-Lee cell line revealed chromosomal abnormalities that fit the initial description of that cell line made in 1990 (karyotype: modal number 49 (44–49).X,–Y,–1, add(2)(p11.2),add(5)(p13),add(6)(p13),i(7)(p10)×2,add(9)(q21),add(12)(q21),–17,add(14)(q13),add(19),add(20)).²⁵ Two of three primary meningiomas analyzed for *in vitro* inhibition studies were found to have chromosomal abnormalities (karyotype of a 71-year-old man: modal number 47 (46–48), X,–Y,add(1)(p34),add(4)(p12),+del(5)(q31),add(6)(q27),+add(9)(p21),add(12)(q21)[cp20]; karyotype of 45-year-old woman: modal number 45,XX,–22; and karyotype of a 71-year-old woman: XX,normal).

Immunohistochemical Analysis of COX-2 in Meningiomas

Immunohistochemical staining for COX-2 was performed on 135 human meningioma surgical specimens and colon carcinoma controls.²⁸ One hundred twenty-eight benign (95%), seven atypical (5%), and no (0%) anaplastic meningiomas stained positively for COX-2 (Table 3). The COX-2 immunoreactivity was found in the cytoplasm of all the meningiomas studied. In fact, 111 (87%) of the 128 benign meningiomas and six (86%) of the seven atypical meningiomas exhibited Grade 4 staining (Fig. 1 and Table 3). Only 16 benign meningiomas (12%) and one atypical tumor (1%) displayed Grade 3 staining, and only one benign tumor (1%) displayed Grade 2 staining (Table 3). No Grade 0 or 1 stainings were noted. Normal dura mater stained for COX-2 displayed staining of the endothelial lining of blood vessels only (Fig. 1).

The immunohistochemical analysis for COX-2 was per-

formed on the IOMM-Lee malignant meningioma cell line and on four meningiomas grown in cell culture.²⁵ All five specimens exhibited extensive cytoplasmic and nuclear staining (Fig. 2 and Table 2).

Expression of the COX-2 Protein in Meningiomas

Four cryogenically stored human meningioma samples were processed for Western blot experiments. The COX-2 protein has a molecular weight of approximately 70 kD.^{10,13} Cytoplasmic and nuclear protein extracts were isolated. All the meningiomas sampled exhibited staining of a large band at approximately 70 kD in the cytoplasm extracts, and three of four stained positively in the nuclear extracts (Fig. 3).

Celecoxib-Induced Apoptosis and Inhibition of Meningioma Cell Growth in Culture Without Change in BAX Protein Expression

The selective COX-2 inhibitor, celecoxib, decreased meningioma cell growth in a dose-dependent fashion in both the malignant IOMM-Lee cell line and six benign meningiomas grown in cell culture (Fig. 4). Doses ranging from 0.25 to 1 mM caused cell growth inhibition, which increased with higher doses. Statistical significance ($p < 0.05$) was reached when the control group was compared with all treatment groups (that is, groups treated with 0.25, 0.5, and 1 mM celecoxib) by Day 1.

Celecoxib (1 mM) induced apoptosis by Day 2 as seen in the results of the TUNEL assay (Fig. 5). A morphological analysis of the treated cells showed a decreased monolayer density, reduced cell size, and cell detachment from tissue culture wells. These findings are consistent with the induction of apoptosis.⁴⁰ No change in the expression of the proapoptotic protein BAX was demonstrated by Western blot analysis in the IOMM-Lee cell line or in three WHO Grade I cell lines (Fig. 6).

Discussion

Rationale for COX-2 Inhibitors and Meningiomas

Although the cause of meningioma is unknown, head trauma has been suspected of playing a causal role since the 1800s, with reports of meningiomas developing in patients at the site of prior head trauma. In one case report the authors describe the extraction of a piece of wire from the center of a meningioma, its presence the result of an explosion that had taken place 20 years earlier.⁴² Several investigators have shown an increased incidence of meningiomas in patients with a history of head trauma, with elevated odds

FIG. 1. Photomicrographs demonstrating expression of COX-2 in human colon cancer and human meningiomas. Positive immunoreactivity appears as reddish-brown staining. A: Positive control. Strong COX-2 immunoreactivity is seen in the cytoplasm of colon carcinoma cells (*solid arrow*). Note that the vascular endothelium stains positively for COX-2 (*open arrow*). B: Negative control. No staining is noted after slides were incubated with serum only. C: Normal dura mater showing staining of the vascular endothelium only (*arrow*). D–F: Strong COX-2 immunoreactivity noted diffusely throughout the cytoplasm of meningiomas (*solid arrows*). Note: monocytes or macrophages within blood vessels stain positively (*open arrow* in D). Original magnification $\times 10$.

ratios ranging between 1.2 and 6.4.^{39,42,43} Possible causal mechanisms of meningioma formation following head trauma include inflammation, neoplastic changes in meningeal tissue caused by healing, and the release of growth factors. All these factors may act as inciting factors in tumorigenesis.^{35,39} In fact, it has been suggested that the formation of a meningioma may occur in the setting of chronic inflammation triggered by head trauma.² Recently, the inducible inflammatory enzyme COX-2 has been shown to be upregulated in animal head trauma models.^{23,24}

Cyclooxygenase is the rate-limiting enzyme in the synthesis of prostaglandins from arachidonic acid.³⁷ The prostaglandins are a diverse group of auto- and paracrine hormones that mediate many physio- and pathological processes. Physiologically, prostaglandins regulate vascular homeostasis, kidney function, ovulation, and parturition. These compounds are equally important as mediators of inflammation, thrombosis, and pain.³² The formation of prostaglandins requires the catalytic activity of COX, which converts arachidonic acid to the prostaglandin endoperoxide, PGH₂, from which all other prostaglandins are formed.

The COX enzyme exists as two isoforms, COX-1 and COX-2.³⁷ The first, COX-1, is constitutively expressed in most tissues and is thought to serve in general “housekeeping” functions (for example, cytoprotection of the stomach and platelet aggregation). The second, COX-2, is induced by migratory cells (for example, macrophages, monocytes, and microglia) as a response to proinflammatory stimuli and is considered to be an important mediator of acute and

chronic inflammatory states.^{13,31} Expression of COX-2 has a wide range of biological activities including angiogenesis, cellular proliferation, and the halt of apoptosis.¹⁰ Both enzymes are targets for therapeutic NSAIDs.³⁷

The ability of NSAIDs to inhibit the COX enzyme is considered to be their major, but not sole, mode of function.¹³ The NSAIDs decrease COX activity through nonselective binding, selective binding to COX-2, or noncyclooxygenase COX-2 mechanisms.¹³ Nonselective COX inhibitors (for example, aspirin and ibuprofen) are clinically limited by their gastrointestinal and platelet side effects, which are attributed to COX-1 inhibition; therefore, selective COX-2 inhibitors were developed. Celecoxib (Celebrex) and rofecoxib (Vioxx) are specific COX-2 inhibitors that act as slow, time-dependent, irreversible inhibitors of COX-2.¹³ From a clinical standpoint, COX-2 inhibition is expected to produce antiinflammatory and analgesic effects without causing gastric ulcers or platelet dysfunction.

Relationship Between COX-2 and Cancer

Human cancers of the bladder, breast, uterine cervix, central nervous system, colorectum, esophagus, head and neck, liver, lung, pancreas, prostate, skin, and stomach overexpress COX-2 and produce more prostaglandins than the normal healthy tissues from which they are derived.⁵¹ Experimental evidence has demonstrated that unregulated COX-2 expression occurs at multiple stages in carcinogenesis and is important in the promotion of tumorigenesis.⁴¹

COX-2 universally expressed in meningiomas

FIG. 2. Expression of COX-2 in EcR293 cells with inducible COX-2 vector (A) and human meningiomas grown in monolayer cultures (B–F). Positive immunoreactivity appears as brown staining. A: Positive control. Strong COX-2 immunoreactivity is seen in the cytoplasm of COX-2-producing EcR293 cells (*arrow*). B: Negative control. No staining is noted after IOMM-Lee cells were incubated with serum only. C: Extensive staining is seen in IOMM-Lee cells (*arrow*). D–F: Strong COX-2 immunoreactivity (Grade 4) is noted diffusely throughout the cytoplasm and nucleus in three separate meningiomas (*arrows*). Original magnification $\times 20$.

The NSAIDs are important agents for cancer prevention and as possible adjuncts to treatment for the following reasons: 1) COX inhibitors stimulate anticancer effects *in vitro*; 2) COX inhibitors inhibit carcinogenesis in carcinogen-induced and genetically driven rodent models; 3) COX inhibitors reduce the incidence of colorectal precancerous lesions and colon cancer (for example, familial adenomatous polyposis); and 4) COX inhibitors produce regression in precancerous lesions (for example, colorectal aberrant crypt foci and adenomas, and actinic keratoses of the skin) in genetic and sporadic cancer risk cohorts.^{9,51}

Currently, celecoxib and rofecoxib are approved by the US Food and Drug Administration for their antiinflammatory, analgesic, and cancer-prevention properties in the treatment of rheumatoid arthritis, osteoarthritis, and familial adenomatous polyposis.^{10,13} On the basis of the aforementioned preclinical and clinical efficacy data obtained in celecoxib and rofecoxib and the ubiquitous overexpression of COX-2 in human neoplasia, the National Cancer Institute is currently tracking more than 20 Phase I, II, and III cancer trials on COX-2 inhibition in the treatment of colon, prostate, liver, lung, and breast tumors, and glioblastoma multiforme (source: National Cancer Institute clinical trials database found at <http://www.nci.nih.gov/clinicaltrials>).

Given the loose association of meningiomas with a history of head trauma, we postulated that chronic inflammation may play a role in meningioma development and that the inflammatory enzyme COX-2 may be associated with tumorigenesis. If these hypotheses are correct, blockade of COX-2 may hold therapeutic promise for the treatment of meningiomas.

Expression of COX-2 in Meningiomas

We performed an immunohistochemical analysis of 135

paraffin meningioma sections and five meningiomas grown *in vitro* for COX-2 and observed extensive staining in the majority of the tumors (Fig. 1 and Table 3). These findings are consistent with those of two other immunohistochemical studies, which demonstrated robust COX-2 staining in meningiomas. Lin and associates²⁶ stained 83 meningiomas for COX-2 and found that an overwhelming percentage of tumors expressed COX-2. Matsuo, et al.,³⁰ also showed strong COX-2 immunoreactivity in six surgical specimens. Immunohistochemically, as shown by our *in vitro* stainings, COX-2 localizes to both the cytoplasm and nuclear compartments. Our paraffin sections were counterstained with a nuclear stain, making it difficult to localize COX-2 staining to the nucleus. Further proof of COX-2 expression in meningiomas is supported by our Western blot data.

A 70-kD band that stained positive for COX-2 protein was universally seen in the cytoplasmic extracts. Western blots for the nuclear extract demonstrated COX-2 immunoreactivity in three of four meningiomas. These findings lend further credence to our immunohistochemical data, demon-

FIG. 3. Western blots of four meningioma tumor samples (numbered 1–4). Nuclear (n) and cytoplasmic (c) protein extracts were isolated and probed with COX-2 antibody. The COX-2 protein has a molecular weight of approximately 70 kD. A large 70-kD band stains positively for COX-2 is noted in all samples except one nuclear extract (*arrow*).

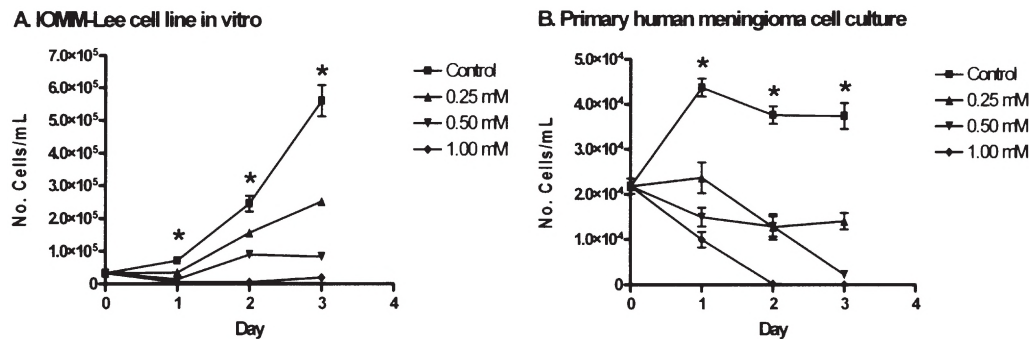


FIG. 4. Effects of varying concentrations of celecoxib (0.25 mM–1 mM) and DMSO vehicle on IOMM-Lee cells (A) and benign meningioma cells (B). The DMSO concentration was held constant at 0.1% for all time points. Cell counts were determined by bright-line hemocytometer in duplicate, with bars representing the standard error of the mean for three separate experiments. Data shown for benign meningiomas (B) are representative of six meningioma cell lines. The t-test used to compare control and treated data found a statistical significance between all treatment groups and control by Day 1 ($p < 0.05$). The growth curve plateau seen in the control cells of B are due to contact inhibition, a typical feature of benign meningiomas as they reach confluence in vitro.

strating extensive COX-2 expression in meningiomas. The presence of the 70-kD COX-2 protein in the nuclear extract in all but one meningioma is an interesting finding, which we attribute to an error in our nuclear extraction process.

Role of Celecoxib in Decreased Meningioma Cell Proliferation and Induction of Apoptosis

Celecoxib, a selective COX-2 inhibitor, was chosen because of its approval by the Food and Drug Administration and its superior antigrowth effects in vitro in several cell lines.^{19,55} Dose-dependent inhibition of meningioma cell viability by celecoxib was seen in vitro in both a malignant cell line (IOMM-Lee) and six benign cell lines. Celecoxib

decreased the growth of meningiomas in a monolayer culture at a dose as low as 0.25 mM; cell death was noted by Day 3 at a dose of 1 mM in one meningioma cell line. These results are compatible with extensive in vitro data obtained on numerous cell lines, which demonstrate growth inhibition by selective COX-2 inhibitors.^{22,50} Specifically, in a study of the glioma cell lines U87MG and U251MG, the COX-2 inhibitor NS-398 was shown to inhibit cell proliferation and migration.¹⁸

The results of our study demonstrate that celecoxib induces apoptosis in vitro. Yamazaki and colleagues⁵⁵ showed that in vitro celecoxib inhibited cell proliferation and induced apoptosis in colon cancer cells. Our findings also agree with those of Williams, et al.,⁵² who demonstrated that

FIG. 5. Celecoxib induces apoptosis of meningioma cells by Day 2. Apoptosis was assessed using the TUNEL assay. A: Negative TUNEL control. B: Positive TUNEL control. C: Drug control, vehicle only (0.1% DMSO). D: Celecoxib (1 mM). Brown staining indicates cells undergoing apoptosis.

COX-2 universally expressed in meningiomas

FIG. 6. Western blots of four meningioma cell lines grown in vitro and treated with 0.1% DMSO vehicle control (Con; Lanes 1, 3, 5, and 7) or 1 mM celecoxib (Tx; Lanes 2, 4, 6, and 8) for 48 hours. The cell lines tested in vitro included a malignant meningioma (IOMM-Lee; Lanes 1 and 2) and three WHO Grade I cell lines (Samples A–C; Lanes 3–8). Lanes were loaded with 35 µg of protein from whole-cell lysate and probed with anti-BAX antibody (23 kD). The IOMM-Lee cell line (Lanes 1 and 2) and all three WHO Grade I meningiomas (Lanes 3–8) displayed no noticeable change in BAX expression.

celecoxib potently induced apoptosis and inhibited progression of the cell cycle in colorectal carcinoma cells grown in culture. Interestingly, the investigators demonstrated that these effects were brought about by mechanisms independent of COX-2 inhibition. In other in vitro studies researchers have shown that COX-2 overexpression results in resistance to apoptosis, which in turn leads to dysregulation of normal cell death.^{50,51} Although the specific antiapoptotic mechanisms remain unclear, one possibility is modulation of the BAX-to-bcl-2 ratio, which is key in driving cell apoptosis. Prostaglandin E2 increases bcl-2, resulting in a BAX-to-bcl-2 ratio and favoring an antiapoptotic effect.¹⁰ In contrast, COX-2 inhibitors increase the levels of BAX and decrease those of bcl-2, thus favoring cell apoptosis.^{1,4,36,51} Our in vitro Western blot studies for BAX demonstrated no change in the expression of this proapoptotic protein. This finding coincides with those of several other studies that demonstrated no change in BAX expression after celecoxib treatment.^{21,53,54} Interestingly, other investigators have demonstrated that celecoxib induces the translocation of BAX from the cytosol to the mitochondria by the simultaneous release of cytochrome C.⁵⁶ Mitochondrial release of cytochrome C is a known trigger for caspase pathway activation and ultimate apoptosis.⁵⁶ Given our findings, it is unclear whether the apoptotic and halt-of-cell-progression effects that celecoxib had on meningiomas in this study are BAX dependent.

In Vitro Celecoxib Treatment

The plasma half-life of celecoxib is 13 hours, with a steady state reached at 5 days.^{11,20,49} The range of our in vitro concentrations of celecoxib was 0.25 mM to 1 mM, which is at least 10 times higher than plasma levels obtained using standard dosing in humans. Growth studies accomplished at lower doses of celecoxib had no effect on cell growth in vitro within the relatively short time frame tested, making the higher dosing regimen necessary (data not shown). Currently, in vivo experiments at therapeutically achievable celecoxib plasma levels are being conducted in our laboratory with promising results (data not shown). Our findings of a discrepancy between the high in vitro drug dosing regimen and the low (clinically relevant) in vivo drug regimen agree with the findings of other investigators.⁵²

Role of COX-2 and COX-2 Inhibition in Meningiomas

In this paper we do not address the roles of COX-2 expression and its inhibition in meningioma tumorigenesis. In fact, many investigators suggest that celecoxib exerts its antitumor effects via pathways other than its blockade of COX-2. Additional studies in our laboratory are underway to delineate the role COX-2 plays in tumorigenesis and whether its blockade by celecoxib is necessary for the antitumor effects seen in vitro. Despite these shortcomings, we propose that celecoxib and other NSAIDs may have a role in the treatment of recalcitrant meningiomas.

Conclusions

The COX-2 enzyme is universally expressed in meningiomas. Celecoxib inhibits meningioma growth in vitro in a dose-dependent fashion, with evidence of apoptosis. The COX-2 inhibitors may have a potential role in the treatment of recurrent meningiomas.

Acknowledgments

We thank Kristin Kraus for her excellent editorial assistance and Spencer Dattage for his laboratory expertise.

References

1. Badawi AF, Eldeen MB, Liu Y, Ross EA, Badr MZ: Inhibition of rat mammary gland carcinogenesis by simultaneous targeting of cyclooxygenase-2 and peroxisome proliferator-activated receptor gamma. *Cancer Res* **64**:1181–1189, 2004
2. Barnett GH, Chou SM, Bay JW: Posttraumatic intracranial meningioma: a case report and review of the literature. *Neurosurgery* **18**:75–78, 1986
3. Barnett GH, Suh JH, Crownover RL: Recent advances in the treatment of skull base tumors using radiation. *Neurosurg Clin N Am* **11**:587–596, 2000
4. Basu GD, Pathangey LB, Tinder TL, Lagioia M, Gendler SJ, Mukherjee P: Cyclooxygenase-2 inhibitor induces apoptosis in breast cancer cells in an in vivo model of spontaneous metastatic breast cancer. *Mol Cancer Res* **2**:632–642, 2004
5. Blankenstein MA, Verheijen FM, Jacobs JM, Donker TH, van Duijnhoven MW, Thijssen JH: Occurrence, regulation, and significance of progesterone receptors in human meningioma. *Steroids* **65**:795–800, 2000
6. Burger PC, Scheithauer BW, Vogel FS (eds): *Surgical Pathology of the Nervous System and Its Coverings*, ed 4. New York: Churchill Livingstone, 2002
7. Cao Y, Pearman AT, Zimmerman GA, McIntyre TM, Prescott SM: Intracellular unesterified arachidonic acid signals apoptosis. *Proc Natl Acad Sci USA* **97**:11280–11285, 2000
8. Cianchi F, Cortesini C, Bechi P, Fantappie O, Messerini L, Vannacci A, et al: Up-regulation of cyclooxygenase 2 gene expression correlates with tumor angiogenesis in human colorectal cancer. *Gastroenterology* **121**:1339–1347, 2001
9. Dixon DA, Balch GC, Kedersha N, Anderson P, Zimmerman GA, Beauchamp RD, et al: Regulation of cyclooxygenase-2 expression by the translational silencer TIA-1. *J Exp Med* **198**:475–481, 2003
10. Fosslien E: Biochemistry of cyclooxygenase (COX)-2 inhibitors and molecular pathology of COX-2 in neoplasia. *Crit Rev Clin Lab Sci* **37**:431–502, 2000
11. Frank DH, Roe DJ, Chow HH, Guillen JM, Choquette K, Gracie D, et al: Effects of a high-selenium yeast supplement on celecoxib plasma levels: a randomized phase II trial. *Cancer Epidemiol Biomarkers Prev* **13**:299–303, 2004

12. Goldsmith BJ, Wara WM, Wilson CB, Larson DA: Postoperative irradiation for subtotally resected meningiomas. A retrospective analysis of 140 patients treated from 1967 to 1990. **J Neurosurg** **80**:195–201, 1994
13. Hinz B, Brune K: Cyclooxygenase-2—10 years later. **J Pharmacol Exp Ther** **300**:367–375, 2002
14. Jaaskelainen J, Haltia M, Servo A: Atypical and anaplastic meningiomas: radiology, surgery, radiotherapy, and outcome. **Surg Neurol** **25**:233–242, 1986
15. Jensen RL, Lee YS, Gujraji M, Oritano TC, Wurster RD, Reichman OH: Inhibition of in vitro meningioma proliferation after growth factor stimulation by calcium channel antagonists: Part II—Additional growth factors, growth factor receptor immunohistochemistry, and intracellular calcium measurements. **Neurosurgery** **37**:937–947, 1995
16. Jensen RL, Oritano TC, Lee YS, Weber M, Wurster RD: In vitro growth inhibition of growth factor-stimulated meningioma cells by calcium channel antagonists. **Neurosurgery** **36**:365–374, 1995
17. Jensen RL, Soleau S, Bhayani MK, Christiansen D: Expression of hypoxia inducible factor-1 alpha and correlation with preoperative embolization of meningiomas. **J Neurosurg** **97**:658–667, 2002
18. Joki T, Heese O, Nikas DC, Bello L, Zhang J, Kraeft SK, et al: Expression of cyclooxygenase 2 (COX-2) in human glioma and in vitro inhibition by a specific COX-2 inhibitor. NS-398. **Cancer Res** **60**:4926–4931, 2000
19. Kardosh A, Blumenthal M, Wang WJ, Chen TC, Schonthal AH: Differential effects of selective COX-2 inhibitors on cell cycle regulation and proliferation of glioblastoma cell lines. **Cancer Biol Ther** **3**:55–62, 2004
20. Karim A, Tolbert DW, Hunt TL, Hubbard RC, Harper KM, Geis GS: Celecoxib, a specific COX-2 inhibitor, has no significant effect on MTX pharmacokinetics in patients with RA. **J Rheumatol** **26**:2539–2543, 1999
21. Kern MA, Schubert D, Sahi D, Schoneweiss MM, Moll I, Haugg AM, et al: Proapoptotic and antiproliferative potential of selective cyclooxygenase-2 inhibitors in human liver tumor cells. **Hepatology** **36**:885–894, 2002
22. King JG Jr, Khalili K: Inhibition of human brain tumor cell growth by the anti-inflammatory drug, flurbiprofen. **Oncogene** **20**: 6864–6870, 2001
23. Koyfman L, Kaplanski J, Artru AA, Talmor D, Rubin M, Shapira Y: Inhibition of cyclooxygenase 2 by nimesulide decreases prostaglandin E2 formation but does not alter brain edema or clinical recovery after closed head injury in rats. **J Neurosurg Anesthesiol** **12**:44–50, 2000
24. Kunz T, Marklund N, Hillered L, Oliw EH: Cyclooxygenase-2, prostaglandin synthases, and prostaglandin H2 metabolism in traumatic brain injury in the rat. **J Neurotrauma** **19**:1051–1064, 2002
25. Lee WH: Characterization of a newly established malignant meningioma cell line of the human brain: IOMM-Lee. **Neurosurgery** **27**:389–396, 1990
26. Lin CC, Kenyon L, Hyslop T, Hammond E, Andrews DW, Curran WJ Jr, et al: Cyclooxygenase-2 (COX-2) expression in human meningioma as a function of tumor grade. **Am J Clin Oncol** **26**: S98–S102, 2003
27. Louis DN, Scheithauer BW, Budka H, von Deimling A, Kepes JJ: Meningiomas, in Kleihues P, Cavenee WK (eds): **World Health Organization Classification of Tumours, Pathology, and Genetics of Tumours of the Nervous System**. Lyon: IARC, 2000, pp 176–184
28. Maihofner C, Charalambous MP, Bhabra U, Lightfoot T, Geisslinger G, Gooderham NJ: Expression of cyclooxygenase-2 parallels expression of interleukin-1beta, interleukin-6 and NF-kappaB in human colorectal cancer. **Carcinogenesis** **24**:665–671, 2003
29. Mason WP, Gentili F, Macdonald DR, Hariharan S, Cruz CR, Abrey LE: Stabilization of disease progression by hydroxyurea in patients with recurrent or unresectable meningioma. **J Neurosurg** **97**:341–346, 2002
30. Matsuo M, Yonemitsu N, Zaito M, Ishii K, Hamasaki Y, Fukuyama K, et al: Expression of prostaglandin H synthase-2 in human brain tumors. **Acta Neuropathol (Berl)** **102**:181–187, 2001
31. Matsuura H, Sakaue M, Subbaramaiah K, Kamitani H, Eling TE, Dannenberg AJ, et al: Regulation of cyclooxygenase-2 by interferon gamma and transforming growth factor alpha in normal human epidermal keratinocytes and squamous carcinoma cells. Role of mitogen-activated protein kinases. **J Biol Chem** **274**: 29138–29148, 1999
32. Meade EA, McIntyre TM, Zimmerman GA, Prescott SM: Peroxisome proliferators enhance cyclooxygenase-2 expression in epithelial cells. **J Biol Chem** **274**:8328–8334, 1999
33. Milosevic MF, Frost PJ, Laperriere NJ, Wong CS, Simpson WJ: Radiotherapy for atypical or malignant intracranial meningioma. **Int J Radiat Oncol Biol Phys** **34**:817–822, 1996
34. Mirimanoff RO, Dosoretz DE, Linggood RM, Ojemann RG, Martuza RL: Meningioma: analysis of recurrence and progression following neurosurgical resection. **J Neurosurg** **62**:18–24, 1985
35. Morantz RA, Shain W: Trauma and brain tumors: an experimental study. **Neurosurgery** **3**:181–186, 1978
36. Narayanan BA, Narayanan NK, Pittman B, Reddy BS: Regression of mouse prostatic intraepithelial neoplasia by nonsteroidal anti-inflammatory drugs in the transgenic adenocarcinoma mouse prostate model. **Clin Cancer Res** **10**:7727–7737, 2004
37. Pairet M, Engelhardt G: Distinct isoforms (COX-1 and COX-2) of cyclooxygenase: possible physiological and therapeutic implications. **Fundam Clin Pharmacol** **10**:1–17, 1996
38. Penning TD, Talley JJ, Bertenshaw SR, Carter JS, Collins PW, Docter S, et al: Synthesis and biological evaluation of the 1,5-diarylpyrazole class of cyclooxygenase-2 inhibitors: identification of 4-[5-(4-methylphenyl)-3-(trifluoromethyl)-1H-pyrazol-1-yl] benzenesulfonamide (SC-58635, celecoxib). **J Med Chem** **40**: 1347–1365, 1997
39. Phillips LE, Koepsell TD, van Belle G, Kukull WA, Gehrels JA, Longstreth WT Jr: History of head trauma and risk of intracranial meningioma: population-based case-control study. **Neurology** **58**:1849–1852, 2002
40. Pozarowski P, Grabarek J, Darzynkiewicz Z: Flow cytometry of apoptosis, in Robinson P, Darzynkiewicz Z, Hyun W, et al (eds): **Current Protocols in Cytometry**. New York: John Wiley & Sons, 2003, Vol 1, pp 7.19.15–17.19.33
41. Prescott SM: Is cyclooxygenase-2 the alpha and the omega in cancer? **J Clin Invest** **105**:1511–1513, 2000
42. Preston-Martin S, Pogoda JM, Schlehofer B, Blettner M, Howe GR, Ryan P, et al: An international case-control study of adult glioma and meningioma: the role of head trauma. **Int J Epidemiol** **27**:579–586, 1998
43. Preston-Martin S, Yu MC, Henderson BE, Roberts C: Risk factors for meningiomas in men in Los Angeles County. **J Natl Cancer Inst** **70**:863–866, 1983
44. Ragel B, Jensen RL: New approaches for the treatment of refractory meningiomas. **Cancer Control** **10**:148–158, 2003
45. Rosenthal MA, Ashley DL, Cher L: Treatment of high risk or recurrent meningiomas with hydroxyurea. **J Clin Neurosci** **9**: 156–158, 2002
46. Rutka JT, Giblin J, Dougherty DV, McCulloch JR, DeArmond SJ, Rosenblum ML: An ultrastructural and immunocytochemical analysis of leptomeningeal and meningioma cultures. **J Neuropathol Exp Neurol** **45**:285–303, 1986
47. Schrell UM, Rittig MG, Anders M, Koch UH, Marschalek R, Kiesewetter F, et al: Hydroxyurea for treatment of unresectable and recurrent meningiomas. II. Decrease in the size of meningiomas in patients treated with hydroxyurea. **J Neurosurg** **86**: 840–844, 1997
48. Simpson D: The recurrence of intracranial meningiomas after surgical treatment. **J Neurochem** **20**:22–39, 1957
49. Stempak D, Gammon J, Klein J, Koren G, Baruchel S: Single-

COX-2 universally expressed in meningiomas

- dose and steady-state pharmacokinetics of celecoxib in children. **Clin Pharmacol Ther** 72:490–497, 2002
50. Tsujii M, Kawano S, Tsuji S, Sawaoka H, Hori M, DuBois RN: Cyclooxygenase regulates angiogenesis induced by colon cancer cells. **Cell** 93:705–716, 1998
51. Umar A, Viner JL, Anderson WF, Hawk ET: Development of COX inhibitors in cancer prevention and therapy. **Am J Clin Oncol** 26:S48–S57, 2003
52. Williams CS, Watson AJ, Sheng H, Helou R, Shao J, DuBois RN: Celecoxib prevents tumor growth in vivo without toxicity to normal gut: lack of correlation between in vitro and in vivo models. **Cancer Res** 60:6045–6051, 2000
53. Wu T, Leng J, Han C, Demetris AJ: The cyclooxygenase-2 inhibitor celecoxib blocks phosphorylation of Akt and induces apoptosis in human cholangiocarcinoma cells. **Mol Cancer Ther** 3:299–307, 2004
54. Wun T, McKnight H, Tuscano JM: Increased cyclooxygenase-2 (COX-2): a potential role in the pathogenesis of lymphoma. **Leuk Res** 28:179–190, 2004
55. Yamazaki R, Kusunoki N, Matsuzaki T, Hashimoto S, Kawai S: Selective cyclooxygenase-2 inhibitors show a differential ability to inhibit proliferation and induce apoptosis of colon adenocarcinoma cells. **FEBS Lett** 531:278–284, 2002
56. Zhang Z, Lai GH, Sirica AE: Celecoxib-induced apoptosis in rat cholangiocarcinoma cells mediated by Akt inactivation and Bax translocation. **Hepatology** 39:1028–1037, 2004

Manuscript received July 21, 2004.

Accepted in final form May 2, 2005.

This work was supported in part by a grant from the American Association of Neurological Surgeons Neurosurgery Research and Education Foundation to Brian Ragel.

Address reprint requests to: William T. Couldwell, M.D., Ph.D., Department of Neurosurgery, University of Utah, 30 North 1900 East, Suite 3B409, Salt Lake City, Utah 84132. email: william.couldwell@hsc.utah.edu.