

Selective MR Imaging Approach for Evaluation of Patients with Horner's Syndrome

Kathleen B. Digre,¹ Wendy R.K. Smoker,^{2,3} P. Johnston,⁴ Michael R. Tryhus,² H.S. Thompson,⁴ Terry A. Cox,¹ and W.T.C. Yuh⁵

Purpose: To assess the usefulness of MR in the evaluation of patients with Horner's syndrome.

Patients and Methods: We prospectively performed MR imaging in 33 patients with Horner's syndrome (13 preganglionic and 20 postganglionic), using a protocol specifically designed for pre- and postganglionic varieties of this syndrome. Assignment of patients to pre- or postganglionic categories was performed on the basis of pharmacologic testing. **Results:** Abnormalities in one-half of the patients with preganglionic Horner's syndrome included lateral medullary infarct, spinal cord/root disease, apical lung tumor, and paravertebral metastatic mass. Three of 20 patients with postganglionic Horner's syndrome had carotid artery dissection. **Conclusion:** Routine scanning of patients who have postganglionic Horner's syndrome with cluster headaches was not helpful in our small series.

Index terms: Horner syndrome; Brain, magnetic resonance

AJNR 13:223-227, January/February 1992

Horner's syndrome, also known as oculosympathetic dysfunction, is characterized by ptosis, miosis, "upside-down ptosis" (or elevation of the lower lid), and facial anhidrosis. The syndrome is produced by a lesion occurring anywhere along the sympathetic pathway from the first neuron (hypothalamus), which descends through the brain stem and cord, to the second neuron (C8-T1 cord). The fibers exit the cord through this root and proceed under the subclavian artery, over the apex of the lung, and ascend to the third neuron in the superior cervical ganglion, located

at the levels of C2 and the carotid bifurcation. As shown in Figure 1, the fibers travel along the internal carotid artery to the end organs: the dilator of the pupil, Müller's muscle of the eyelid, and the vasculature of the face (1).

The evaluation of patients with Horner's syndrome has involved localizing the lesion to preganglionic (before the superior cervical ganglion) or postganglionic (after the superior cervical ganglion) segments. Clinical judgment has then been used to determine whether chest radiographs, chest computed tomography (CT), carotid angiography, or head CT should be performed. Frequently no cause for Horner's syndrome is found.

Magnetic resonance (MR) imaging has been used in the evaluation of patients with carotid artery dissection (2) and lateral medullary infarction (3). We postulated that MR imaging may be useful as a diagnostic tool in the evaluation of patients with Horner's syndrome. The purpose of this study was to: 1) divide the syndrome into pre- or postganglionic Horner's and image-known sympathetic pathways by regional protocols; and 2) to determine which patients may benefit from MR evaluation.

Materials and Methods

Thirty-three patients at our two institutions were identified between November 1986 and April 1990 with the

Received March 26, 1991; revision requested June 5; revision received July 19; final acceptance July 22.

Presented at the 28th Annual Meeting of the ASNR, Los Angeles, CA, March 19-23, 1990.

This project is supported in part by a grant to the Department of Ophthalmology at the University of Utah School of Medicine, Salt Lake City, from Research to Prevent Blindness, New York, NY.

¹ Department of Ophthalmology and Neurology, University of Utah School of Medicine, 50 North Medical Drive, Salt Lake City, UT 84132. Address reprint requests to Dr K.B. Digre.

² Department of Radiology, University of Utah School of Medicine, Salt Lake City, UT 84132.

³ Present address: Department of Radiology, Medical College of Virginia, Richmond, VA 23298.

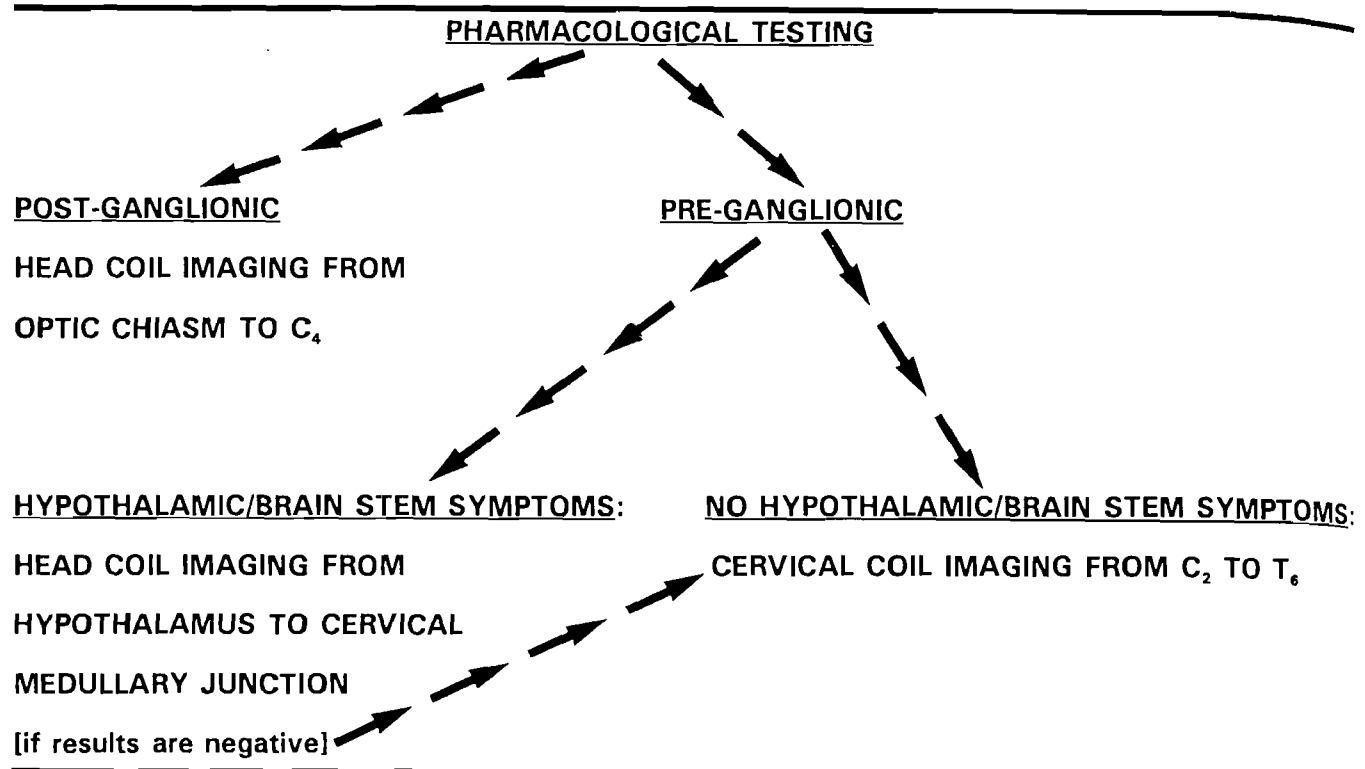
⁴ Department of Ophthalmology, University of Iowa, Iowa City, IA 52242.

⁵ Department of Radiology, University of Iowa, Iowa City, IA 52242.

AJNR 13:223-227, Jan/Feb 1992 0195-6108/92/1301-0223

© American Society of Neuroradiology

TABLE 1: MR imaging algorithm for Horner's syndrome



clinical diagnosis of Horner's syndrome (miosis, ptosis). Twenty-six were men and seven were women; mean age was 46.9 years (range: 12–57 years). Horner's syndrome was confirmed by either photographs or video showing distinct dilation lag or cocaine drop testing.

Each patient's pupils were photographed using a hand-

held Polaroid camera in room light, bright light, and dim light. A drop of hydroxyamphetamine, which had been standardized in testing for pre- postganglionic Horner's syndrome, was administered (4). A second drop of hydroxyamphetamine was instilled 1 minute later, and a follow-up photo was taken between 45 and 60 minutes. Measurements of the pupil were taken using a magnifying ruler measuring to the nearest 0.1 mm.

The difference between the right and left pupillary size before and after instillation of hydroxyamphetamine was measured. A preganglionic Horner's syndrome was defined by equal dilation of both pupils (hence no increased anisocoria). A postganglionic Horner's syndrome was diagnosed when the pupil did not dilate the contralateral eye after the drops, showing an increase of anisocoria (4).

For imaging purposes, it was useful to further establish whether the preganglionic Horner's syndrome patients also had associated brain stem or hypothalamic symptoms, indicative of a disruption of the proximal pathways of the

TABLE 2: Preganglionic Horner's syndrome without brain/brain stem symptoms protocol: cervical spine surface coil

Imaging Plane	Region Imaged	Imaging Sequence
Sagittal	Entire neck, offset to side of interest	Spin-echo T1
Coronal	Posterior spinal cord through anterior neck	Spin-echo T2
Axial	C2 through T6	Spin-echo T1
Axial	C2 through T6	Spin-echo T2

TABLE 3: Preganglionic Horner's syndrome with brain/brain stem symptoms protocol: head coil*

Imaging Plane	Region Imaged	Imaging Sequence
Sagittal	Entire brain	Spin-echo T1
Axial	Entire brain	Spin-echo T2
Axial	Entire brain	Spin-echo T1

* If no lesion was identified, the remainder of the preganglionic pathway was examined.

TABLE 4: Postganglionic Horner's syndrome protocol: head coil

Imaging Plane	Region Imaged	Imaging Sequence
Sagittal	Brain/upper cervical spine-offset to side of interest	Spin-echo T1
Coronal	Carotid spaces and cavernous sinuses	Spin-echo T2
Axial	Optic chiasm to C4	Spin-echo T2
Axial	Optic chiasm to C4	Spin-echo T1

TABLE 5: Summary of Horner's lesions demonstrated by MR prospectively

Central Horner preganglionic (N = 6)	
Lateral medullary infarct	3 patients
Vertebral dissection with lateral medullary infarct	1 patient
Preganglionic (N = 7)	
Cord/root compression secondary to disc disease	2 patients
Apical lung mass (Pancoast tumor)	1 patient
Paravertebral metastatic mass	1 patient
Postganglionic (N = 20)	
Carotid artery dissection	3 patients

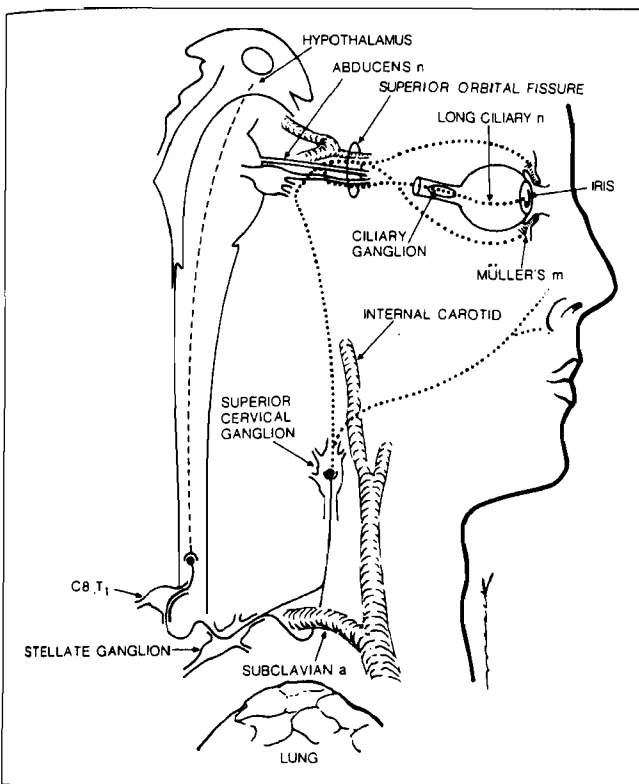


Fig. 1. Schematic drawing demonstrating the ocular sympathetic pathway.

first order neuron in the brain. The duration of the patient's Horner's syndrome was also noted.

Table 1 depicts the imaging algorithm used during the study. Patients received pharmacologic testing and were divided into pre- and postganglionic arms. Preganglionic patients without brain stem or hypothalamic symptoms were imaged with a cervical neck surface coil from C2 to T6, attempting to image the first-order neuron pathways in the cervical cord, and the second neuron from its origin to the superior cervical ganglion. Patients with preganglionic Horner syndrome and symptoms localizing a lesion to the brain or brain stem were imaged from the cervical

medullary junction through the hypothalamus in the standard head coil. If a lesion was not found, the remainder of the preganglionic pathway was imaged, as previously outlined. Postganglionic patients were imaged in the standard head coil to the level of C4 because the pathology must be located in the superior cervical ganglion, at the skull base, or above.

Thirteen patients were studied at institution A on a 0.5 T Superconducting Magnet (Picker International, Highland Heights, OH). Twenty patients were studied at institution B on a 1.5 T Superconducting Magnet (Ge Signa, Milwaukee, WI). The specific imaging protocols for the three patient groups (preganglionic Horner's syndrome without brain/brain stem symptoms, preganglionic Horner's syndrome with brain/brain stem symptoms, and postganglionic Horner's syndrome) are outlined in Tables 2, 3, and 4. Typically, spin echo T1 (400-750/20/.75-4) = (TR/TE/excitations) and spin echo T2 (2000-2800/30-40, 70-100/1-2) were routinely used. Later in the study, additional scanning techniques were also employed to further evaluate cervical disc disease (gradient echo sequence) and flow in vessels suspected of being dissected (single slice gradient echo technique). MR angiography was not routinely available at the time of this study.

Results (See Table 5)

There were 13 preganglionic Horner's syndrome patients. Of these, six patients had symptoms and signs to suggest central involvement: three had facial numbness, and three had diplopia. Four out of these six had abnormal MR scans. Three had lateral medullary infarction (Fig. 1) and one had a vertebral artery dissection producing lateral medullary infarction. One patient had an incidental dolichoectatic basilar artery that was not clearly causing the Horner's syndrome.




Fig. 2. Axial T1-weighted MR scan in a patient with preganglionic Horner's syndrome, in the absence of brain or brain stem symptoms, reveals a large left apical lung mass (M) compatible with a Pancoast tumor. The mass appears to be extending into the neural foramen (arrowheads) (600/20/20).

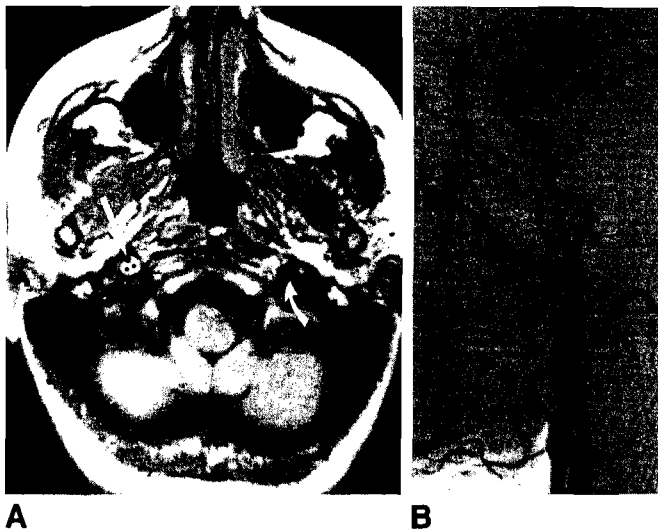


Fig. 3. A, Axial T1-weighted MR scan in a patient with post-ganglionic Horner's syndrome. Compared to the normal flow void of the internal carotid artery on the left (*curved white arrow*). The right carotid artery flow void is very diminutive (*white straight arrow*). There is high signal intensity surrounding the vessel, compatible with hemorrhage (*dots*) indicating internal carotid artery dissection (600/20/2).

B, Common carotid artery arteriogram (lateral view) demonstrates the carotid artery dissection (*small arrowheads*) with a pseudoaneurysm present at the entrance to the carotid canal (*large arrowhead*).

The seven remaining preganglionic Horner's syndrome patients had no other central signs. Of these, four of the seven had MR abnormalities: Pancoast tumor (one patient; see Fig. 2), significant disk disease at C5-C6 or T1-T2 levels on the correct side of the Horner's syndrome (two patients), paravertebral metastatic mass (one patient). There were two patients with positive scans who had symptoms less than 2 months and two with symptoms over 6 months.

There were 20 postganglionic patients. Of these, three had carotid artery dissection identified by MR (Fig. 3), subsequently confirmed by angiography. All of these patients had acute onset of Horner's syndrome identified within 7-21 days of their MR studies. Of the postganglionic Horner's syndrome patients with negative MR studies, seven had cluster headaches. None of these seven patients demonstrated an abnormal MR lesion. The Horner's syndrome had been present for an average of 8.2 years (range 1 month to 38 years). Four other postganglionic patients had headaches (not cluster) and two had a history of trauma. Among the patients with a Horner's syndrome of less than 2 months duration, three had positive MR scans and seven had negative scans. No patient in whom Horner's syndrome was doc-

umented to be greater than 2 months duration had identifiable lesion (N = 10).

Discussion

Horner's syndrome has been associated with many important lesions. It has been useful to divide Horner's syndrome into pre- and postganglionic groups by using hydroxyamphetamine. Hydroxyamphetamine releases norepinephrine from its stores; therefore, in a preganglionic lesion with stores in place, the pupil dilates, whereas in postganglionic Horner's syndrome, the pupil does not (due to the absence of norepinephrine accumulation). In a review of 120 patients with ocular sympathetic paresis, Grimson and Thompson showed that 41% had preganglionic Horner's syndrome, and one-half of them had underlying neoplasia (5). Other known causes of preganglionic Horner's syndrome include: postsurgical trauma, nonsurgical trauma, cervical arthritis, and brachial plexus lesions (6). The postganglionic Horner's syndrome differential diagnosis includes: 1) abnormalities around the internal carotid artery (dissections, spontaneous and traumatic occlusion, aneurysms, headache syndromes including cluster headache); 2) lesions around the cavernous sinus (basilar skull fracture, locally invasive malignant neoplasm); 3) inflammation of adjacent structures (Tolosa-Hunt syndrome, otitis media, petrositis, trigeminal zoster, sinus disease); and 4) orbital lesions (very rare) (6).

There are two clinical problems encountered when evaluating a patient with Horner's syndrome: 1) the pathology ranges from relatively insignificant to life threatening; and 2) the pathology extends along the oculosympathetic pathway from the hypothalamus to the thorax, to the carotid artery, and finally the orbit. This is a very large area to be imaged, requiring multiple coils and pulse sequences during MR imaging.

In this study, we prospectively evaluated patients with Horner's syndrome by MR scanning, using pharmacologic testing as a guide to the area to be scanned. We expected greater sensitivity in diagnosing "the causative lesion" using this technique. Many reasons could account for our inability to find a diagnosis in every case. First, the time of onset of the Horner's syndrome was variable from patient to patient. Some patients had acute onset, while others had their syndrome for years. There may have been an abnormality acutely present, but, after years, the abnormality may no longer be identifiable (for example, re-

canalization after carotid artery dissection and thrombosis). Certainly patients with acute Horner's syndromes, especially those in the postganglionic category, had an increased incidence of identifiable pathology. Second, MR relies on tissue contrast to detect lesions. Using our MR scanning techniques, lesions (which have little contrast) could be missed. Direct imaging of the sympathetic nerve is not yet possible. Third, the cause of Horner's syndrome in some cases may not be structural. For example, cluster headaches are thought to be due to injury of the sympathetic fibers within the bony carotid canal either by swelling of the adventitia or local chemical changes (7, 8). Other authors have also reported being unable to identify abnormalities on MR in patients with cluster headaches (9).

At the time this prospective study was instituted, gadolinium-DTPA (Gd-DTPA) was not available for routine use. Similarly, the various fat suppression techniques were not in vogue. For these reasons, none of our patients were imaged following the administration of Gd-DTPA, and no fat suppression studies were obtained. It is certainly possible that the use of Gd-DTPA with or without fat suppression techniques might disclose additional, causative pathology. However, this remains to be determined in the evaluation of patients with Horner's syndrome.

Our recommendations for the MR evaluation of patients with Horner's syndrome include using hydroxyamphetamine testing to distinguish between preganglionic and postganglionic varieties. If there are central signs or symptoms, an MR of the brain stem and upper cervical cord should be performed. All preganglionic lesions can be

screened using our preganglionic protocol with an expected yield of 50% positive scans. If the lesion is postganglionic and acute (ie, less than 2 months of age), there is a greater yield of positive scans (three out of 10 vs zero out of nine in patients with chronic Horner's syndrome). MR imaging in patients with chronic postganglionic Horner syndrome, especially those with cluster headache, was not helpful in our small series.

Acknowledgment

The authors thank Steven M. Thiese, scientific editor for the Department of Ophthalmology at the University of Utah School of Medicine, for his advice and assistance in the preparation of this report.

References

1. Fox AJ, Bogousslavsky J, Carey LS, et al. Magnetic resonance imaging of small medullary infarctions. *AJNR* 1986;7:229-233
2. Goldberg HI, Grossman RI, Gomori JM, Asbury AK, Bilaniak LT, Zimmerman RA. Cervical internal carotid artery dissecting hemorrhage: diagnosis using MR. *Radiology* 1986;158:157-161
3. Fox A, Bogousslavsky J, Carey LS, et al. Magnetic resonance imaging of small medullary infarction. *AJNR* 1986;7:229-233
4. Cremer SA, Thompson HS, Digre KB, Kardon R. Hydroxyamphetamine mydriasis in Horner's syndrome. *Am J Ophthalmol* 1990;110:71-76
5. Grimson BS, Thompson HS. Horner's syndrome: overall view of 120 cases. In: Thompson HS, ed. *Topics in neuro-ophthalmology*. Baltimore: Williams & Wilkins, 1979:151-156
6. Grimson BS, Thompson HS. Post-ganglionic Horner's syndrome. In: Glaser JS, ed. *Neuro-ophthalmology*. St. Louis: CV Mosby, 1977:190-198
7. Ekborn K, Greitz T. Carotid angiography in cluster headaches. *Acta Radiol (Diagn) (Stockh)* 1970;10:177-186
8. Vijayan N, Watson C. Evaluation of oculosympathetic function in vascular headache syndrome. II. Oculocephalic sympathetic function in cluster headaches. *Headache* 1982;22:200-202
9. Sjaastad O, Rinck P. Cluster headache: MRI studies of the cavernous sinus and base of the brain. *Headache* 1990;30:350-351