

Terson Syndrome: CT Evaluation in 12 Patients

Charles E. Swallow, Jay S. Tsuruda, Kathleen B. Digre, Matthew J. Glaser,
H. Christian Davidson, and H. Ric Harnsberger

PURPOSE: Terson syndrome may be overlooked in the acute setting and often requires ophthalmologic intervention to prevent long-term visual loss. In this syndrome, vitreous or retinal hemorrhage results from an abrupt rise in intracranial pressure, leading to retinal venous hypertension and intraocular hemorrhage. Our objective was to determine whether imaging findings could be discovered that might facilitate an earlier diagnosis.

METHODS: Our inpatient medical record data base for 1991-1996 listed 11 patients with Terson syndrome. The medical records of these 11 patients were reviewed retrospectively and compared with their noncontrast head CT scans and with scans of 10 control subjects. One additional case was discovered prospectively, for a total of 12 patients. Three radiologists unaware of the patients' history evaluated CT scans of the orbits for evidence of intraocular hemorrhage.

RESULTS: CT findings in eight patients were suggestive of retinal hemorrhage manifested by a retinal crescent or nodule that was slightly hyperdense relative to the vitreous humor. There was a high degree of concordance between the retrospective and independent reviews.

CONCLUSION: Retinal nodularity and crescentic hyperdensities are evident on CT scans in the majority of patients with Terson syndrome. Although findings are subtle and not present in all cases, in the setting of subarachnoid hemorrhage they suggest retinal hemorrhage and warrant detailed fundoscopic evaluation.

Terson syndrome is a vitreous or retinal hemorrhage occurring consequent to subarachnoid hemorrhage; it is strongly associated with visual deficits and may require early surgical management (1-4). Fundoscopic examination is the usual means of diagnosis, but it may be difficult to perform or the bleeding may be overlooked in the setting of acute subarachnoid hemorrhage. The presence of Terson syndrome has been reported to be predictive of poor clinical outcome in terms of recovery from the intracranial hemorrhage (4-6). We reasoned that if characteristic imaging findings of Terson syndrome could be established, earlier diagnosis could prove useful as a prognostic sign. We therefore reviewed CT scans in 12 patients discharged from our facility with the diagnosis of Terson syndrome in an effort to determine

whether specific findings of this entity could be identified on CT studies of the brain.

Methods

The inpatient medical records from the computer data base for the period 1990 through 1996 were searched for patients discharged with the diagnosis of Terson syndrome or with diagnostic combinations of subarachnoid hemorrhage and vitreous or retinal hemorrhage. The search generated 11 patients. The imaging studies and medical records of these patients were reviewed retrospectively by two radiologists. A subsequent case (case 8, see Table) was diagnosed prospectively on the basis of CT findings.

The records of the 12 patients with Terson syndrome and those of 10 control subjects with intracranial hemorrhage but without Terson syndrome as noted on fundoscopic examination were reviewed by three radiologists (a senior radiology resident, a neuroradiology fellow, and a neuroradiology professor). The reviewers were unaware of which subjects had ocular disease, and were asked to judge the retinal surfaces as normal, abnormal, or obscured.

The majority of imaging studies were performed with a 23-cm field of view, 120 kV, 170 mA, 2-second scan time, and 512 × 512 matrix, and photographed at a window width of 150 and level of 35 (GE 9800 or High Speed Advantage). In a single patient, imaging parameters included a 22-cm field of view, 130 kV, 125 mA, 3-second scan time, and 512 × 512 matrix, photographed at a window width of 80 and level of 40 (Picker 1200).

Received June 13, 1997; accepted after revision October 1.

Presented at the annual meeting of the American Society of Head and Neck Radiology/American Society of Neuroradiology, Toronto, Canada, May 1997.

From the Departments of Radiology (C.E.S., J.S.T., M.J.G., H.C.D., H.R.H.) and Ophthalmology (K.B.D.), University of Utah Health Science Center, Salt Lake City.

Address reprint requests to Jay S. Tsuruda, MD, Department of Radiology, Room A171, 50 N Medical Center Dr, Salt Lake City, UT 84132.

Terson syndrome: data in 12 cases

Case	Age, y	Cause of Hemorrhage	Documented Eye Examination	Retrospective CT Findings	Outcome Visual Acuity	Time to Diagnosis	Days to Abnormal CT Findings
1	46	ACOM aneurysm	Vitreous and retinal heme, OS > OD	L crescentic density temporal to macula	Bilateral vitrectomy 20/20 OS, 20/30 OD	2 wk	12
2	29	Giant L MCA aneurysm	Central retinal and vitreous heme OS	3 × 3-mm L macula nodule	Vitrectomy OS, 20/20 OU	3 wk	2
3	35	Trauma	Vitreous and retinal hemorrhage OS	8 × 3-mm hyperdense crescent temporal to L ON	20/15, 20/25	3 mo	1
4	42	ACOM aneurysm	Vitreous and retinal hemorrhage OD	R temporal retinal thickening and nodularity near ON	Unknown	Unknown	1
5	60	ACOM aneurysm	OD >> OS vitreous and retinal hemorrhage	L hyperdense crescent medial retinal surface	Unknown	2 mo	20
6	20	Trauma	Bilateral vitreous and retinal hemorrhage	Bilateral 5 × 15-mm central retinal hyperdense crescents	Death	Immediate	1
7	16	Trauma	Central and inferomedial retinal heme OD	R crescentic density central and inferior retina	Unknown	Immediate	1
8	55	ACOM aneurysm	Temporal retinal hemorrhage OD	R retinal crescentic nodule temporal to ON	Unknown	2 d	2
9	45	LVA aneurysm, cocaine	Small dot blot foci of retinal heme OS	Normal retina	Spontaneous clearance improved to 20/80 OS	3 wk	...
10	50	L PICA aneurysm	Vitreous heme OS, small macular heme	Normal retina	Spontaneous clearance improved to 20/70 OS	3 mo	...
11	57	Undetermined	Small retinal heme inferior to disk OD	Normal retina	Never had visual deficit	Unknown	...
12	72	ACOM rupture 3 aneurysms	Retinal heme OD	Normal retina	Unknown	Unknown	...

Note.—ACOM indicates anterior communicating artery; MCA, middle cerebral artery; LVA, left vertebral artery; PICA, posterior inferior cerebellar artery; OS, left eye; OD, right eye; ON, optic nerve.

Results

The results of the imaging and chart reviews are summarized in the Table. Intracranial hemorrhage resulted from aneurysmal rupture in eight cases and from head trauma in three cases. In one case, the cause of the hemorrhage could not be determined despite multiple angiograms.

The degree of vitreous and retinal hemorrhage documented in the ocular examination varied substantially among patients, ranging from extensive hemorrhage in some patients to only minimal findings in others. Terson syndrome was diagnosed in 15 globes examined fundoscopically. The time to ophthalmologic diagnosis varied from immediate diagnosis in three cases to several weeks to months in half the cases, often related to discovery of a late visual defect hindering physical therapy or rehabilitation.

Retrospective review of the CT scans revealed findings suggestive of retinal hemorrhage in eight of the patients. This included nine of the 15 globes with hemorrhage on physical examination. In six of these patients, findings suggestive of retinal hemorrhage were discovered on CT scans obtained within 2 days after intracranial hemorrhage. The hemorrhage became slightly more dense and conspicuous over the subsequent week in three of those cases. In one patient (case 1) transferred to our facility 12 days after his intracranial hemorrhage, an admission CT scan at

that time showed retinal hemorrhage. His earlier studies were not available for review. In one patient (case 9) imaged on an older-model scanner, evidence of retinal hemorrhage was not appreciated until seen on scans obtained 20 days after the initial intracranial hemorrhage.

Although the CT findings ranged from subtle asymmetric retinal thickening to dense crescents 3 to 5 mm thick, typical findings consisted of a crescent or nodule on the retinal surface that was slightly hyperdense relative to the vitreous (Figs 1–3). The clinically documented hemorrhage in the vitreous was often large, to the point of obscuring the retina, but no qualitative difference could be discerned between the involved and uninvolved vitreous on CT scans. Hounsfield unit measurements were obtained for the vitreous humor in the first five patients with Terson syndrome and in five control patients, but no significant difference in the average vitreous density was found between Terson patients and control subjects or in the density of the involved and uninvolved vitreous in individual patients despite the presence of vitreous hemorrhage documented on fundoscopic examination (Fig 2). Because no significant differences in vitreous density were found, no Hounsfield unit measurements were obtained in the subsequent cases.

The retrospective review of the images by the three radiologists was in agreement with findings in the

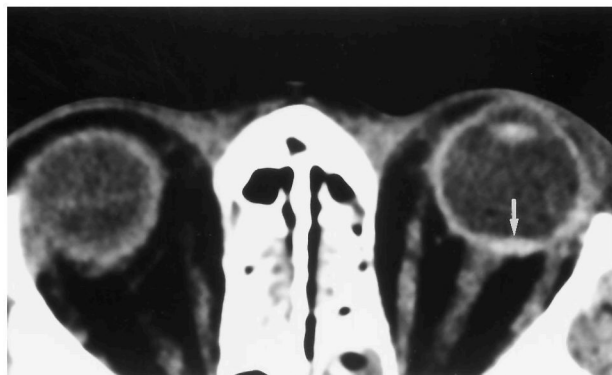


FIG 1. Case 3: 35-year-old woman with severe closed head injury after being struck by a car. Two months later a left visual field deficit was noted during admission for shunt revision. Fundoscopy revealed retinal hemorrhage in the temporal pole and old vitreous blood in the left eye. A CT scan obtained on the day of the trauma revealed a hyperdense crescent (*arrow*) in the temporal retinal surface adjacent to the optic nerve corresponding to the site of hemorrhage on fundoscopy.

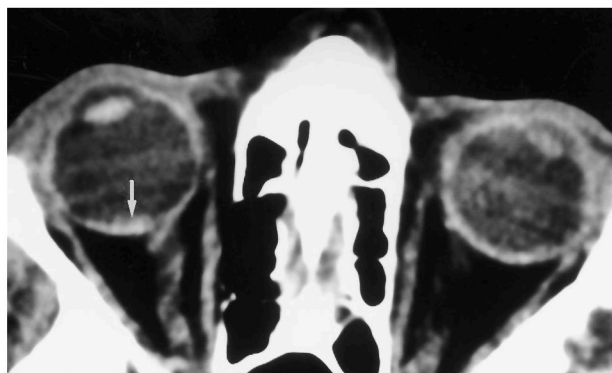


FIG 2. Case 4: 42-year-old man after aneurysmal rupture and clipping in the anterior communicating artery. Physical examination revealed vitreous and retinal hemorrhage in the right eye. A CT scan obtained 1 week after intracranial hemorrhage revealed a hyperdense crescent (*arrow*) on the temporal retinal surface adjacent to the optic nerve corresponding to hemorrhage on fundoscopy. Note the apparent increased density of the normal left vitreous as compared with the abnormal right side.

control subjects in the majority of cases. The most experienced reviewer achieved the highest rate of concordance (11 of 12). There was agreement with the retrospective review in 10 of 12 cases reviewed by the fellow, and in nine of 12 cases reviewed by the resident. In the single case in which the three independent reviewers all disagreed with the retrospective analysis (case 5), the findings were subtle, partially obscured by streak artifact, and had been imaged on the oldest model CT scanner. In case 10, the fellow predicted an abnormality that corresponded with retinal hemorrhage on physical examination, although no lesion was detected on either of the retrospective reviews. None of the control studies were called abnormal by the professor, although in one case of unilateral Terson syndrome (case 8), bilateral lesions were described. Three control cases were called abnormal and three were called obscured by the fellow. One control study was called abnormal and two were called obscured by the resident. In reviewing the

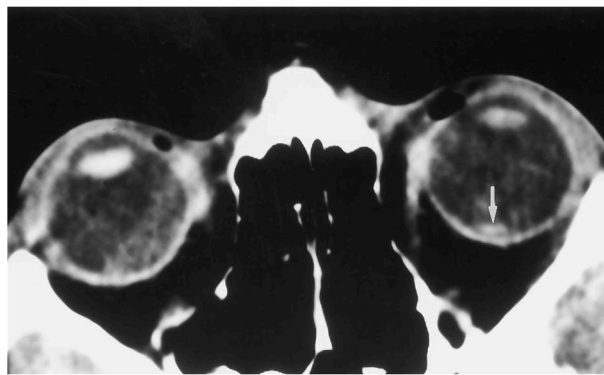


FIG 3. Case 2: 29-year-old woman 12 days postpartum suffered rupture of a giant fusiform left middle cerebral artery aneurysm. A visual field deficit was noted 3 weeks later, at which time fundoscopy revealed central retinal and vitreous hemorrhage in the left eye. A CT scan obtained on the day after the intracranial hemorrhage revealed a hyperdense nodule (*arrow*) on the central left retinal surface corresponding to the fundoscopic abnormality.

false-positive diagnoses, the majority were found to be due to mistaking the tangentially imaged superior or inferior aspects of the globe for a retinal abnormality. In two cases, a streak artifact and in one case a rectus muscle insertion were mistaken for a retinal hemorrhage.

Knowledge of the clinical outcome was available in six patients. In two cases, a pars plana vitrectomy was performed, resulting in improved visual acuity. In case 1, vision improved from "count fingers" to 20/20 in the left eye and to 20/30 in the right eye. Case 2 underwent a left vitrectomy resulting in 20/20 visual acuity; however, the preoperative acuity was not noted in the inpatient records. In case 11 the small hemorrhages never resulted in a significant visual deficit, and in cases 9 and 10 spontaneous clearing of the vitreous hemorrhage resulted in improved visual acuity from 20/400 to 20/80 and from 20/400 to 20/70, respectively. Patient 6 died shortly after his injury.

Discussion

Terson syndrome is defined as vitreous or retinal hemorrhage associated with subarachnoid hemorrhage and is thought most likely to result from a sudden large increase in intracranial pressure (1). It is seen in 10% to 20% of patients with spontaneous or traumatic subarachnoid hemorrhage and generally begins as bleeding between the internal limiting membrane and the retina (3, 7). The hemorrhage may be localized to this site or may extend into the subhyaloid or vitreous spaces. The pathogenesis of the ocular findings is thought to be related to disturbed circulation in the retinal vessels consequent to the increased intracranial pressure, which leads to retinal venous hypertension and, eventually, to hemorrhage (8–10). The clinical course of this process is variable. While in some patients, the hemorrhage clears spontaneously, many will incur vision loss, chronic hematoma, or epiretinal membranes requiring ophthalmologic care, including vitrectomy (3, 7, 8).

Some studies have suggested that patients with intraocular hemorrhage in the setting of acute subarachnoid hemorrhage have a higher mortality rate (50% to 90%) than do patients without Terson syndrome, and that the presence of intraocular blood may be a manifestation of rebleeding from the aneurysm (4, 6). In another series, no difference in mortality was found between patients with and patients without intraocular hemorrhage (5). Only one patient in our group of 12 died. This comparatively low mortality is most likely a result of case selection bias, since the retrospective search parameters we used would favor patients who survived to long-term follow-up and ophthalmologic evaluation.

Clinical examination and pathologic studies of the hemorrhages in Terson syndrome have revealed a dome-shaped posterior pole membrane arising in the subhyaloid space, typically in the temporal vascular arcade (6, 11). The blood may remain confined in this space and appear as a mound on the retina, or may partially or completely decompress through the hyaloid membrane and seep into the vitreous (Fig 4). We postulate that the crescents seen on our imaging studies represent the subhyaloid blood.

To our knowledge, the imaging features of Terson syndrome and the evolution of retinal hemorrhage have not been previously described. As would be expected from the pathologic studies described above, the presence of retinal hemorrhage may be identified on CT scans. In our series, positive findings on CT scans included thickening, nodularity, or crescent-shaped increased density of the retinal surface, often adjacent to the optic nerve and along the temporal surface of the retina. These findings were identified within the first few days after intracranial hemorrhage in the majority of patients with CT evidence of Terson syndrome. In three cases, the retinal hemorrhages became slightly more dense over time, possibly related to consolidation and retraction of the thrombus. Clinical studies involving patients with Terson syndrome as well as subretinal hemorrhage related to senile macular degeneration suggest that

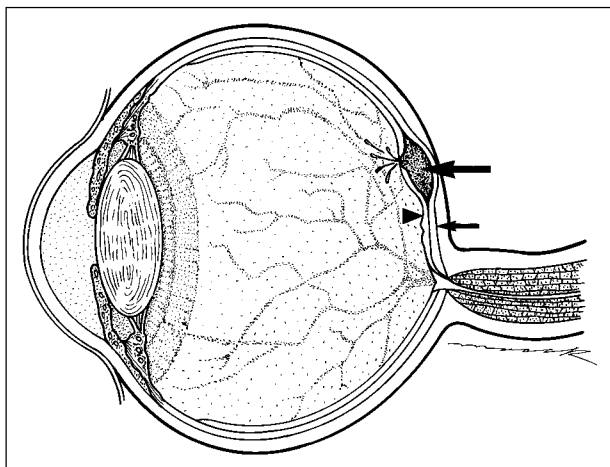


FIG 4. Illustration of hemorrhage (*large arrow*) arising between the retina (*small arrow*) and the internal limiting membrane (*arrowhead*) with decompression into the vitreous.

the blood products are cleared over a period of months by macrophages, that large hemorrhages are associated with poor clinical outcome, and that some of the damage to the retina may be related to toxic effects of iron in large hemorrhages (7, 8, 12). Vitreous hemorrhage, the principle fundoscopic finding, could not be identified on CT scans. During the evaluation of the first five patients in this series, an attempt was made to compare the vitreous Hounsfield unit measurements in the patients with Terson syndrome against those in the control subjects, but no significant density differences between patients and control subjects or between normal and abnormal globes in the same patient could be found. This was thought to be due to the baseline increased attenuation of the vitreous humor relative to cerebrospinal fluid, which, combined with streak artifacts commonly found over the globes, limits CT contrast resolution between the radiologically dense vitreous and the similarly dense intermixed blood products.

No CT evidence of ocular abnormalities could be found in four of the clinically positive cases in this series. In some patients, these false-negative studies may have been due to the small size of the irregularity on the retinal surface. In others, the lower image quality of the earlier model CT scanners may have played a role. The subtle findings we have described may be obscured or difficult to appreciate owing to streak artifacts from the adjacent orbits or to motion artifacts in acutely ill patients. A potential cause of a false-positive CT finding is volume averaging at the rectus muscle insertions or tangential sectioning of the superior and inferior aspects of the globe, which may mimic a crescentic increased density in the retina. The true findings might be most reliably appreciated on the surface of the retina adjacent to the optic nerve, where volume averaging is less likely to occur. Reduction of the section profile from 5 mm to 3 mm thickness might decrease the volume-averaging artifacts, but such a section profile is not routinely used when screening for subarachnoid hemorrhage or in subsequent follow-up studies when ocular disease is not suspected.

Although the differential diagnosis of a noncalcified retinal nodule would include such entities as melanoma, metastasis, and hemangioma, in the setting of acute subarachnoid hemorrhage, where there is a high prevalence of retinal hemorrhage, Terson syndrome is the most likely possibility. In either case, the detection of a retinal nodule should lead to further detailed evaluation.

Conclusion

Terson syndrome is a relatively common complication of subarachnoid hemorrhage that may require early surgical attention to prevent long-term vision loss and hasten recovery (2, 3, 8). Although the diagnosis is typically made fundoscopically, this examination may be limited in an acutely ill patient or findings may evolve after the initial evaluation. The diagnosis may not be made until weeks or months into rehabil-

itation, when a visual field deficit is discovered. We have described findings of retinal nodularity and crescentic increased density in two thirds of the patients in this small series, with a high concordance rate between the retrospective and independent reviews. Although the findings are often subtle and not present in all patients, discovering them in the setting of subarachnoid hemorrhage suggests the presence of retinal hemorrhage and should prompt a detailed fundoscopic examination.

References

1. Kincaid MC, Yanoff M, Fine BS. **Vitreous.** In: *Duane's Foundations of Clinical Ophthalmology* 95, vol 3. Lippincott-Raven; 1995:4-5
2. Schultz PN, Sobol WM, Weingeist TA. **Long-term visual outcome in Terson syndrome.** *Ophthalmology* 1991;98:1814-1819
3. Roux FX, Panthier JN, Tanghe YM, et al. **Terson syndrome and intraocular complications in meningeal hemorrhages (26 cases)** *Neurochirurgie* 1991;37:106-110
4. Pfausler B, Belcl R, Metzler R, Mohsenipour I, Schmutzhard E. **Terson syndrome in spontaneous subarachnoid hemorrhage, a prospective study in 60 consecutive patients.** *J Neurosurg* 1996;85:392-394
5. Garfinkle AM, Danys IR, Nicole DA. **Terson syndrome: a reversible cause of blindness following subarachnoid hemorrhage.** *J Neurosurg* 1992;76:766-771
6. Shaw HE, Landers MB. **Vitreous hemorrhage after intracranial hemorrhage.** *Am J Ophthalmol* 1975;80:207-213
7. Williams DF, Mieler WF, Williams GA. **Posterior segment manifestations of ocular trauma.** *Retina* 1990;10(Suppl 1):S35-S44
8. Velikay M, Datlinger P, Stolba U, Wedrich A, Binder S, Hausmann N. **Retinal detachment with severe proliferative vitreoretinopathy in Terson syndrome.** *Ophthalmology* 1994;101:35-37
9. Weingeist TA, Goldman EJ, Fulk JC, Packer AJ, Ossoinig KC. **Terson syndrome: clinicopathologic correlation.** *Ophthalmology* 1986;93:1435-1442
10. Smith DC, Kearns TP, Sayre GP. **Preretinal and optic nerve sheath hemorrhage: pathologic and experimental aspects in subarachnoid hemorrhage.** *Trans Am Acad Ophthalmol Otolaryngol* 1957;61:201-210
11. Vanderlinden RG, Chisholm LD. **Vitreous hemorrhage and sudden increased intracranial pressure.** *J Neurosurg* 1974;41:167-176
12. Lim JI. **Subretinal hemorrhage.** *Int Ophthalmol Clin* 1995;35:95-104