

Hearing restoration after resection of an intracanalicular vestibular schwannoma: a role for emergency surgery?

Case report and review of the literature

LAWRENCE Z. MEITELES, M.D., JAMES K. LIU, M.D.,
AND WILLIAM T. COULDWELL, M.D., PH.D.

*Department of Otolaryngology, New York Medical College, Valhalla and New York, New York; and
Department of Neurosurgery, University of Utah School of Medicine, Salt Lake City, Utah*

✓ Patients with vestibular schwannomas (VSs) most commonly present with sensorineural hearing loss, which is often insidious or gradual. Up to 26% of patients may present with sudden hearing loss, however, which poses an important surgical challenge. Sudden hearing loss has been attributed to spasm or occlusion of the labyrinthine artery resulting from tumor compression, and it is usually treated with corticosteroids. Hearing preservation surgery is not usually attempted in patients who have poor or nonserviceable hearing preoperatively.

The authors describe a 68-year-old man with complete deafness of the left ear since childhood, who developed sudden, profound sensorineural hearing loss in the right ear. Magnetic resonance imaging revealed a small right-sided intracanalicular tumor. Treatment with high-dose corticosteroids produced only minimal improvement in hearing. Subsequent emergency decompression and resection of a VS resulted in rapid improvement and restoration of hearing, with facial nerve preservation.

Although most neurotologic lesions in patients with hearing in only one ear are managed nonsurgically, resection of small tumors in the setting of sudden hearing loss should be considered in selected cases. This finding indicates that a therapeutic window may exist during which sudden hearing loss caused by intracanalicular tumors is reversible.

KEY WORDS • vestibular schwannoma • acoustic neuroma •
sudden hearing loss • hearing preservation

ADVANCEMENTS in microsurgical procedures and intraoperative monitoring have enabled the resection of VSs (also referred to as acoustic neuromas) while preserving existing hearing. Improvement of the SRT and/or the SDS from their preoperative status is possible after vestibular tumor removal.^{4,5,9,11,15,21,25,26} Patients with small VSs who present with sudden hearing loss are a distinct population, and there are only six reported cases of hearing improvement after removal of VSs in patients who presented with sudden hearing loss.^{4,25,26,30}

Sudden hearing loss caused by a vestibular tumor in the functional ear in patients with unilateral deafness adds yet another challenging dimension to the management of the disease. Only one report of this phenomenon exists, and it includes three patients who underwent middle fossa decompression of the IAC for rapidly deteriorating hearing in their sole functional ear.¹⁰ No tumor was removed in these patients, and only one continued to experience hearing improvement 12 months postoperatively. We report on a case of hearing restoration after emergency removal of a small

intracanalicular tumor presenting with sudden hearing loss in the functional ear of a patient with unilateral deafness.

Case Report

History. This 68-year-old right-handed man who had a history of hypertension and residual left-sided deafness caused by a childhood measles infection presented with acute onset of hearing loss in his functional (right) ear. Two days earlier, he had experienced vertigo, which lasted for several seconds, with associated nausea; he also noted diminution of his hearing ability. The day before presentation, he completely lost his subjective hearing, experienced motion-provoked loss of balance, and continued to experience nausea.

Examination. The patient could communicate with the examiner only by writing; he had complete functional hearing loss bilaterally, with normal tympanic membranes. He exhibited minimal sway on the Romberg test. Facial sensation and motor function were intact. Emergency MR images obtained with and without gadolinium enhancement revealed a 1-cm right-sided intracanalicular tumor with a 3-mm extension into the right cerebellopontine angle cistern (Fig. 1). An audiogram revealed profound sensorineu-

Abbreviations used in this paper: ABR = auditory brainstem response; IAC = internal auditory canal; MR = magnetic resonance; OAE = otoacoustic emission; SDS = speech discrimination score; SRT = speech reception threshold; VS = vestibular schwannoma.

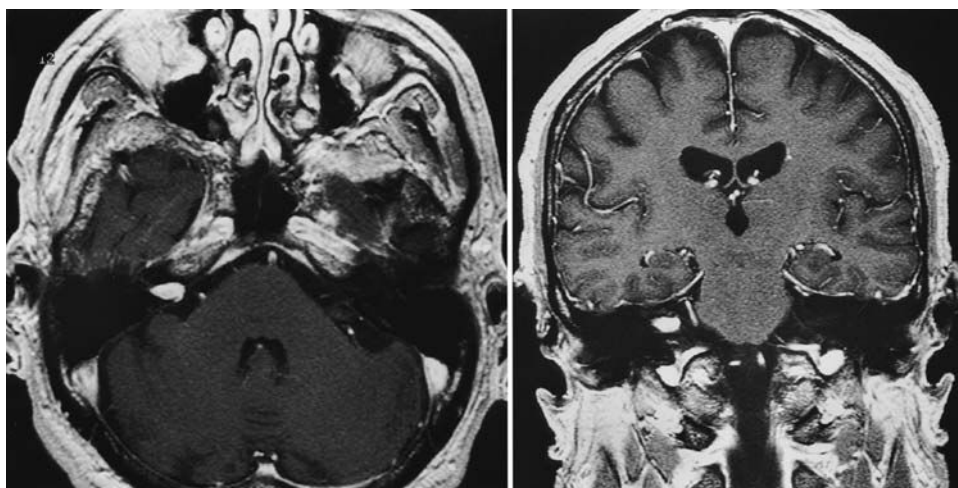


FIG. 1. Axial (*left*) and coronal (*right*) MR images with gadolinium enhancement demonstrating a 1-cm right-sided intracanalicular tumor with a 3-mm extension into the right cerebellopontine angle.

ral hearing loss in the left ear and moderate sensorineural hearing loss in the lower tones, downsloping to a profound loss in the higher tones, in the right ear. The SRT was 0 dB in the left ear; in the right ear the patient had a threshold of 50 dB but could not understand any words (Fig. 2, *upper*).

The patient was immediately treated with high-dose corticosteroids. An audiogram performed approximately 24 hours after corticosteroid treatment was begun revealed an approximately 10- to 20-dB improvement in his pure tone response.

Operation. Shortly after the audiogram was performed, in an attempt to preserve his hearing, the patient underwent an emergency suboccipital/retrosigmoidal craniotomy for resection of the VS. His facial nerve function, somatosensory evoked potentials, and ABRs were monitored intraoperatively. The ABR, however, was not initially obtainable. After the dura was opened, the lateral cerebellum was retracted medially with the aid of an operating microscope, and the seventh and eighth cranial nerve complex was clearly visualized. Approximately 3 mm of the tumor was seen protruding from the IAC. The arachnoid over the seventh and eighth cranial nerve complex was opened. At this time, the ABR revealed a waveform V at approximately 9 msec.

The IAC was carefully drilled out, and the dura was opened to expose the small intracanalicular tumor that arose from the superior vestibular nerve. On completion of decompression of the IAC, the ABR improved by 0.5 msec. The tumor was then dissected from the cochlear nerve, leaving the facial and cochlear nerves intact. After complete excision of the tumor, the ABR improved, with doubling of the amplitude of the response and a decrease of the waveform V time constant. The facial nerve responded well to stimulation at the end of the operation.

Pathological Findings and Postoperative Course. Histopathological examination of the specimen showed evidence of Antoni type A and Antoni type B cells consistent with a VS. On postoperative Day 1, the patient experienced immediate and significant improvement in the hearing in his right ear. He stated that he had some echoing in the ear, but otherwise he could hear everything. He had only mild vestibular symptoms and began ambulating on the 2nd postopera-

tive day. He was discharged from the hospital on postoperative Day 3.

The patient was enrolled in a formal vestibular rehabilitation therapy program, with resolution of his loss of balance. An audiogram performed 1 week postoperatively revealed normal hearing through 1000 Hz and a mild-to-moderate sensorineural hearing loss at 2000 through 8000 Hz in the right ear (Fig. 2, *lower left*). The patient had an SRT of 30 dB and an SDS of 88% at this time. Five months postsurgery, his audiogram showed normal hearing through 2000 Hz and a mild-to-moderate sensorineural hearing loss at 4000 through 8000 Hz (Fig. 2, *lower right*). His SRT and SDS had improved to 20 dB and 92%, respectively. His family and friends thought that his hearing was better after surgery than it had been before the onset of his symptoms.

Discussion

Sudden Hearing Loss Associated With VSs

In 1956, Hallberg¹² first reported sudden deafness as the initial symptom of a VS. Nevertheless, descriptions of patients with VSs presenting with sudden hearing loss can be found in Cushing's⁶ writings as early as 1917. Whereas only 1 to 2% of patients presenting with sudden hearing loss will be found to have a VS, the incidence of VSs presenting with sudden hearing loss has been reported to range from 3% to as high as 26%.^{3,13,14,18,23,29} This wide range is due to an increased rate of early detection of intracanalicular tumors on MR imaging.²⁴ Sudden hearing loss associated with VSs has been reported to resolve spontaneously or to improve with administration of corticosteroid therapy.^{2,3} Patients presenting with sudden hearing loss should undergo an aggressive workup, including an ABR test and gadolinium-enhanced MR imaging, to rule out a VS.^{1,22,23}

Although the pathophysiological features of VSs that cause sudden hearing loss are not yet defined, the mechanism is thought by many to be a vascular occlusive phenomenon.^{1,3,13,18,23,29} The labyrinthine artery, a branch of the anterior inferior cerebellar artery, courses cephalad to the cochlear nerve in the IAC, supplying the cochlea and ves-

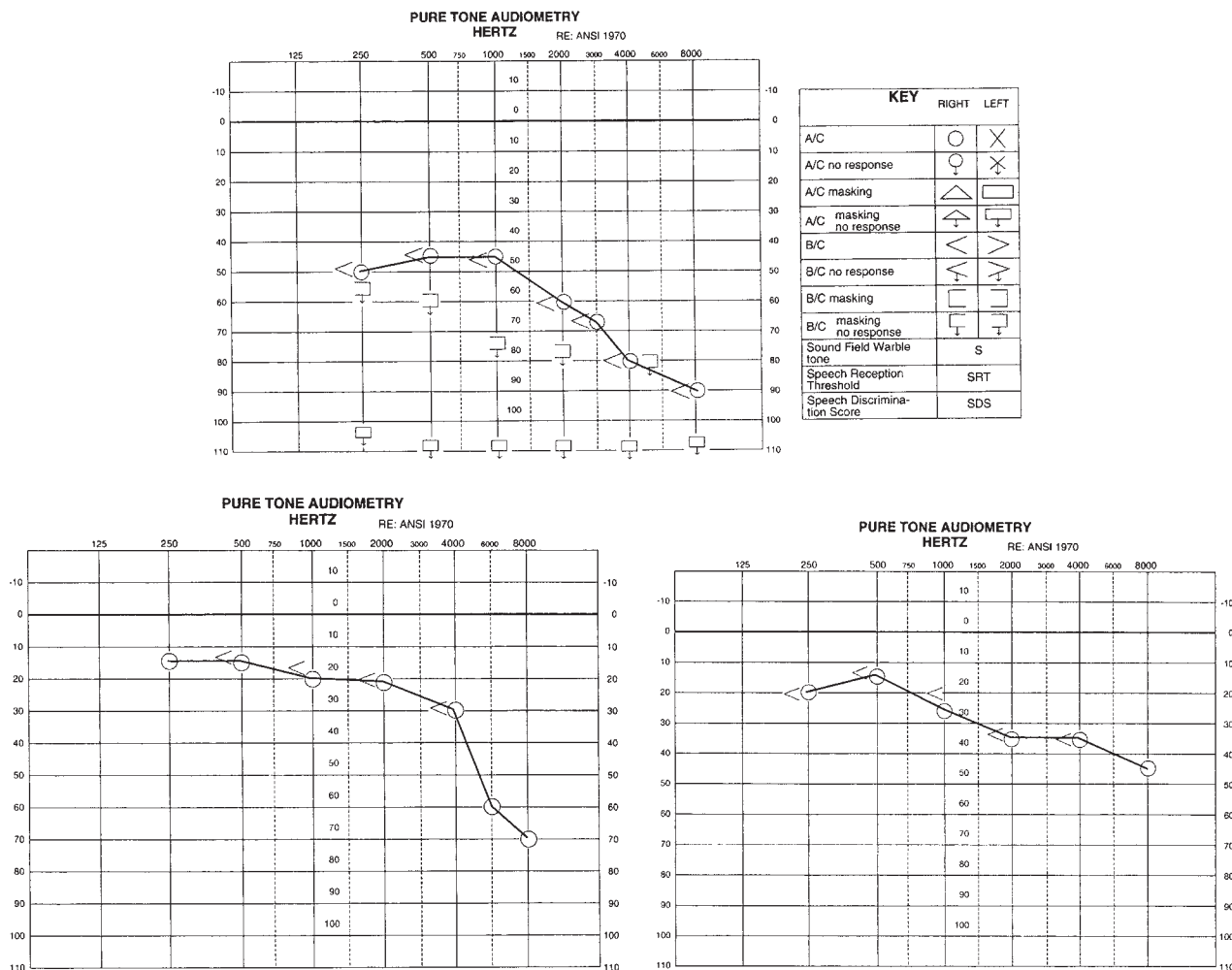


FIG. 2. Pure tone audiograms. *Upper:* Preoperative audiogram showing profound sensorineural hearing loss in the left ear and moderate sensorineural hearing loss in the lower tones, downsloping to a profound loss in the higher tones, in the right ear (SDS 0%). *Lower Left:* Audiogram performed 1 week postoperatively demonstrating marked improvement in hearing in the right ear (SDS 88%). There is normal hearing through 1000 Hz and a mild-to-moderate sensorineural hearing loss at 2000 through 8000 Hz. *Lower Right:* Audiogram performed 5 months postsurgery demonstrating more improvement, with normal hearing through 2000 Hz and a mild-to-moderate sensorineural hearing loss at 4000 through 8000 Hz (SDS 92%). Numbers on the y axis are decibels. A/C = air conduction; B/C = bone conduction.

tibular organs. In 50% of cases, a second branch may be present, running caudad to the inferior vestibular nerve. An expanding tumor or a hemorrhage into an intracanalicular tumor can compress the labyrinthine artery; the sudden hearing loss that results is caused by ischemia of the cochlea and degeneration of the organ of Corti.^{13,18} Vestibular symptoms are not usually present in sudden hearing loss associated with VS.²³ The temporary restoration of hearing after treatment with corticosteroid agents may be a result of reduction of tumor mass and absorption of intratumor fluid.²⁹ Prolonged ischemia, however, can lead to irreversible deafness.

Other investigators have refuted a vascular mechanism and support a mechanical conduction block of the cochlear nerve action potential.^{17,22} Because the cochlear nerve is tonotopically organized, its compression would result in high-frequency and midfrequency (trough type) hearing loss. The low-frequency fibers, found deep in the central

core of the nerve, are also present in the apical turn of the cochlea, which is the distal watershed region of cochlear blood flow. Thus, a low-frequency hearing loss is expected in a vascular event.^{3,22}

Small intracanalicular tumors have been thought by some authors to be associated with a higher incidence of sudden hearing loss.^{17,29} Yanagihara and Asai²⁹ postulated that the tumor mass lying in the IAC may produce sudden hearing loss more frequently than larger tumors because of arterial compression, thus supporting the vascular theory. Our case supports their argument. Other studies, however, have failed to show a correlation between tumor size and sudden hearing loss.^{1,18}

Hearing Improvement After VS Removal

Only a few reports of hearing improvement after VS removal exist, predominantly in the otolaryngological literature.^{4,5,9,26,30} Shelton and House²⁵ defined hearing improve-

ment after acoustic tumor removal as a gain of at least 20% in SDS or an improvement of 15 dB in SRT above preoperative scores. In their study of 106 patients who underwent hearing preservation surgery via a middle fossa approach, hearing improved in nine (8.5%), with the greatest changes occurring in SDS and smaller changes in SRT or pure-tone average. The average size of the tumors was 1 cm, and the duration of hearing loss ranged from 1 to 48 months. Although these authors found no preoperative factors that would predict postoperative hearing improvement, one patient in their series experienced a precipitous drop in SDS 1 day preoperatively, followed by a 92% improvement in their SDS after surgery. Telian, et al.,²⁶ reported a similar case of a patient with a 1.5-cm tumor who suffered sudden and profound deterioration of hearing preoperatively (SDS 0%), and improved dramatically after surgery (SDS 84%). Brackmann⁴ also described a patient with a 4-mm tumor who presented with sudden hearing loss, with an SRT of 73 dB and an SDS of 0%, whose hearing improved postoperatively to an SRT of 30 dB and an SDS of 92%. Our patient improved to 30 dB in SRT and 92% in SDS after tumor resection. These reported cases and ours support the possibility that hearing may be improved by emergency surgical decompression in patients with small VSs who present with sudden hearing loss. Sudden deterioration of hearing may predict postoperative hearing improvement, as suggested by Telian, et al.,²⁶ perhaps because of the reversal of the pressure and associated ischemia caused by the tumor.⁷ Nevertheless, improvement of neural conduction cannot be ruled out.²⁵

In various case reports, the interval between the onset of precipitous sudden hearing loss and successful surgical intervention has ranged from 24 hours to 1 month.^{4,25,26} It is not clear how to determine which of the patients with sudden hearing loss caused by VS will best respond to corticosteroid therapy, or how long to wait until removal of the lesion is warranted. In our case, corticosteroid therapy was initiated in the patient after the diagnosis of complete sudden hearing loss. Because of marginal improvement in hearing, he underwent resection the following day.

Otoacoustic emissions, which have been proposed to have predictive value for hearing preservation after the removal of VSs,^{8,16} are generated by the biomechanical response of the cochlear outer hair cells to acoustic stimuli during the hearing process. The presence of OAEs reflects normal cochlear function at the level of the outer hair cells and provides indirect evidence of cochlear blood supply. In animal studies it has been demonstrated that reversible ischemia to the outer hair cells leads to a transient disappearance of OAEs.^{20,28} Cases of hearing loss during VS removal could be the consequence of a compromised vascular supply to the cochlea rather than damage to the eighth cranial nerve.⁸ It may be useful to measure OAEs in cases of sudden hearing loss caused by VSs to differentiate vascular from neural compression. The presence of detectable OAEs during sudden hearing loss may predict the potential for hearing preservation or recovery after surgery. In our case, however, OAEs may not have been helpful because of the severity of hearing loss and eighth cranial nerve dysfunction.

Management of VS in the Remaining Functional Ear

Hearing preservation surgery in the functional ear in pa-

tients with unilateral deafness poses a challenge because of the devastating potential of leaving the patient totally deaf. This situation is most commonly seen in patients with bilateral VSs (neurofibromatosis Type 2) and unilateral VSs in their remaining functional ear.¹⁰ Treatment options have traditionally included observation, stereotactic radiosurgery, and hearing preservation surgery. Cochlear implants are now being considered in the management of VSs in an "only-hearing ear."^{19,27} Thedinger, et al.,²⁷ described a patient with unilateral deafness who had a 3-cm VS in the remaining functional ear. This patient, who had poor preoperative hearing, first underwent a cochlear implantation in the deaf ear before a translabyrinthine removal of the tumor was performed. Pensak, et al.,¹⁹ described the successful insertion of a cochlear implant into the deafened ear after removal of a VS with cochlear nerve preservation.

When hearing rapidly deteriorates in a sole functional ear, a more aggressive approach should be considered, because observation and stereotactic radiosurgery may render the patient permanently deaf. Gadre, et al.,¹⁰ reported on three patients with small VSs in their sole functional ear who presented with progression of hearing loss and underwent middle fossa decompression of the IAC. This procedure involved unroofing the IAC and slitting the dura to allow expansion of the tumor into the middle fossa. Although decompression does not offer a surgical cure, it may slow down rapid hearing loss by relieving the pressure exerted by the tumor on the neurovascular structures. One patient had useful hearing 12 months postsurgery; the other two eventually lost all hearing because of tumor enlargement.

Conclusions

Our case and the few others reported indicate that there is a period when sudden and profound hearing loss caused by VS may be reversible. Aggressive surgical decompression and tumor removal may be beneficial in offering hearing preservation and long-term tumor control.

References

1. Aslan A, De Donato G, Balyan FR, et al: Clinical observations on coexistence of sudden hearing loss and vestibular schwannoma. **Otolaryngol Head Neck Surg** 117:580–582, 1997
2. Berenholz LP, Eriksen C, Hirsch FA: Recovery from repeated sudden hearing loss with corticosteroid use in the presence of an acoustic neuroma. **Ann Otol Rhinol Laryngol** 101:827–831, 1992
3. Berg HM, Cohen NL, Hammerschlag PE, et al: Acoustic neuroma presenting as sudden hearing loss with recovery. **Otolaryngol Head Neck Surg** 94:15–22, 1986
4. Brackmann DE: Middle cranial fossa approach, in House WF, Luetje CM (eds): **Acoustic Tumors**. Baltimore: University Park Press, 1979, Vol 2, pp 15–41
5. Cohen NL, Ransohoff J, Jacobs J: Restoration of speech discrimination following suboccipital, transmeatal excision of extracranial acoustic neuroma. **Otolaryngol Head Neck Surg** 93:126–131, 1985
6. Cushing H: **Tumors of the Nervus Acusticus and the Syndrome of the Cerebellopontine Angle**. Philadelphia: WB Saunders, 1917
7. Dornhoffer JL, Helms J, Hoehmann DH: Hearing preservation in

- acoustic tumor surgery: results and prognostic factors. **Laryngoscope** **105**:184–187, 1995
8. Ferber-Viart C, Laoust L, Boulud B, et al: Acuteness of preoperative factors to predict hearing preservation in acoustic neuroma surgery. **Laryngoscope** **110**:145–150, 2000
 9. Fischer G, Constantini JL, Mercier P: Improvement of hearing after microsurgical removal of acoustic neurinoma. **Neurosurgery** **7**:154–159, 1980
 10. Gadre AK, Kwartler JA, Brackmann DE, et al: Middle fossa decompression of the internal auditory canal in acoustic neuroma surgery: a therapeutic alternative. **Laryngoscope** **100**:948–952, 1990
 11. Goel A, Sekhar LN, Langheinrich W, et al: Late course of preserved hearing and tinnitus after acoustic neurilemoma surgery. **J Neurosurg** **77**:685–689, 1992
 12. Hallberg OE: Sudden deafness of obscure origin. **Laryngoscope** **66**:1237–1267, 1956
 13. Higgs WA: Sudden deafness as the presenting symptom of acoustic neurinoma. **Arch Otolaryngol** **98**:73–76, 1973
 14. Jackler RK: Acoustic neuroma (vestibular schwannoma), in Jackler RK, Brackmann DE (eds): **Neurotology**. St Louis: Mosby-Year Book, 1994, pp 729–785
 15. Kemink JL, LaRouere MJ, Kileny PR, et al: Hearing preservation following suboccipital removal of acoustic neuromas. **Laryngoscope** **100**:597–602, 1990
 16. Lanzino G, diPierro CG, Ruth RA, et al: Recovery of useful hearing after posterior fossa surgery: the role of otoacoustic emissions: case report. **Neurosurgery** **41**:469–473, 1997
 17. Ogawa K, Kanazaki J, Ogawa S, et al: Acoustic neuromas presenting as sudden hearing loss. **Acta Otolaryngol Suppl** **487**:138–143, 1991
 18. Pensak ML, Glasscock ME III, Josey AF: Sudden hearing loss and cerebellopontine angle tumors. **Laryngoscope** **95**:1188–1193, 1985
 19. Pensak ML, Tew JM Jr, Keith RW, et al: Management of the acoustic neuroma in an only hearing ear. **Skull Base Surg** **1**:93–96, 1991
 20. Ren T, Brown NJ, Zhang M, et al: A reversible ischemia model in gerbil cochlea. **Hear Res** **92**:30–37, 1995
 21. Samii M, Matthies C, Tatagiba M: Intracanalicular acoustic neurinomas. **Neurosurgery** **29**:189–199, 1981
 22. Saunders JE, Luxford WM, Devgan KK, et al: Sudden hearing loss in acoustic neuroma patients. **Otolaryngol Head Neck Surg** **113**:23–31, 1995
 23. Selesnick SH, Jackler RK: Clinical manifestations and audiologic diagnosis of acoustic neuromas. **Otolaryngol Clin North Am** **25**:521–551, 1992
 24. Selesnick SH, Jackler RK, Pitts LW: The changing clinical presentation of acoustic tumors in the MRI era. **Laryngoscope** **103**:431–436, 1993
 25. Shelton C, House WF: Hearing improvement after acoustic tumor removal. **Otolaryngol Head Neck Surg** **103**:963–965, 1990
 26. Telian SA, Kemink JL, Kileny PR: Hearing recovery following suboccipital excision of acoustic neuroma. **Arch Otolaryngol Head Neck Surg** **114**:85–87, 1988
 27. Thedinger BA, Cueva RA, Glasscock ME III: Treatment of an acoustic neuroma in an only-hearing ear: case reports and considerations for the future. **Laryngoscope** **103**:976–980, 1993
 28. Widick MP, Telischi FF, Lonsbury-Martin BL, et al: Early effects of cerebellopontine angle compression on rabbit distortion-product otoacoustic emissions: a model for monitoring cochlear function during acoustic neuroma surgery. **Otolaryngol Head Neck Surg** **111**:407–416, 1994
 29. Yanagihara N, Asai M: Sudden hearing loss induced by acoustic neuroma: significance of small tumors. **Laryngoscope** **103**:308–311, 1993
 30. Yanagihara N, Murakami S, Asai M, et al: Hearing improvement following removal of acoustic neuroma with preoperative sudden deafness. **Ear Nose Throat J** **73**:886, 890–894, 1994

Manuscript received May 21, 2001.

Accepted in final form December 13, 2001.

Address reprint requests to: William T. Couldwell, M.D., Ph.D., Department of Neurosurgery, Suite 3B409, 30 North 1900 East, Salt Lake City, Utah 84132–2303. email: william.couldwell@hsc.utah.edu.