

Variations in Surgical Treatment of Cervical Facet Dislocations

Ahmad Nassr, MD,* Joon Y. Lee, MD,† Marcel F. Dvorak, MD,‡ James S. Harrop, MD,§
Andrew T. Dailey, MD,¶ Christopher I. Shaffrey, MD,|| Paul M. Arnold, MD,**
Darrel S. Brodke, MD,†† Raja Rampersaud, MD,‡‡ Jonathan N. Grauer, MD,§§§§
Corbett Winegar, MD,¶¶ and Alexander R. Vaccaro, MD¶¶¶

Study Design. Retrospective Survey Analysis.

Objective. To explore surgeon preference in the choice of surgical approach in the treatment of traumatic cervical facet dislocations.

Summary of Background Data. The choice of surgical approach in the treatment of traumatic cervical dislocations is highly variable and maybe influenced by a variety of factors. The purpose of this study was to examine inter-rater reliability in choice of surgical approach.

Methods. Twenty-five members of the Spine Trauma Study Group evaluated 10 cases of traumatic cervical dislocations. Evaluation of the case as a unilateral or bilateral injury and surgeon interpretation of the presence of a disc herniation as well as preferred surgical approach were assessed.

Results. Only slight agreement was observed among surgeons in the choice of surgical approach ($Kappa < 0.1$). This improved slightly when patients were assumed to have a complete spinal cord injury ($Kappa = 0.15$). Surgeons used more anterior approaches either alone or as the first stage in a combined approach when a disc herniation was present regardless of neurologic status of the patient. When a patient was neurologically intact, an anterior approach was more common than a posterior approach even when a disc herniation was not present. Combined approaches were preferred for the treatment of bilateral facet dislocations.

Conclusion. The poor agreement on the treatment of these injuries likely reflects a combination of factors in-

cluding surgeon training and experience. Treatment decisions are likely to be affected by the neurologic status of the patient, interpretation of a disc herniation, and the classification of the injury as a unilateral or bilateral injury.

Key words: cervical facet dislocation, traumatic, surgical approach, Survey Study. *Spine* 2008;33:E188–E193

The surgical treatment of traumatic cervical facet dislocations is highly variable.¹ This may be due to a number of factors including a lack of standardized imaging protocols,^{2–6} variable interpretation of advanced imaging studies used to assess the features of the spinal canal, spinal cord compression and the presence or absence of a traumatic intervertebral disc herniation, neurologic status of the patient and the training and technical familiarity and experience of the individual surgeon.⁷ All of these variables are particularly pertinent when decisions are being made with respect to a traumatic cervical facet dislocation, a condition where the neurologic risks are substantial.^{8–10}

Many surgeons advocate that magnetic resonance imaging (MRI) should be obtained before operative intervention.^{7,8,11,12} The concern is the presence of a canal occupying disc herniation, which may accompany these injuries and result in neurologic deterioration at the time of closed or open reduction, such that surgical decompression may be preferable before the reduction and stabilization procedure.

The ability of MRI to detect a canal occupying herniated disc before or after closed skeletal cervical traction results in the potential for variability in surgical approach selection.^{6,7,11,13} Some surgeons will choose to remove a traumatic disc herniation from the anterior approach thus decompressing the spinal cord before manipulation.^{7,8,11,12,14} Others feel that a posterior approach, due to its ability to expand the spinal canal and indirectly decompress the spinal cord may be more optimal and safer in light of a stable neurologic profile. Others may choose an anterior, posterior, or combined approach regardless of the status of the disc.^{15–17} This variability in surgical approaches may also be a reflection of surgeon training, surgeon experience, and the individual's interpretation of the literature. The current article attempts to examine the variability in surgical approach to patients with traumatic unilateral or bilateral facet

From the *Department of Orthopedic Surgery, Mayo Clinic, Rochester, Minnesota; †Department of Orthopedic Surgery, University of Pittsburgh Medical Center, Pittsburgh, Pennsylvania; ‡Department of Orthopedic Surgery, University of British Columbia, Vancouver, BC; §Department of Neurosurgery, Thomas Jefferson University, Philadelphia, Pennsylvania; ¶Department of Neurosurgery, University of Utah, Salt Lake City, Utah; ||Department of Neurosurgery, University of Virginia, Charlottesville, Virginia; **Department of Neurosurgery, University of Kansas Medical Center, KS City, Kansas; ††Department of Orthopedic Surgery, University of Utah, Salt Lake City, Utah; ‡‡Department of Surgery, University of Toronto, Toronto, ON; §§Department of Orthopedics and Rehabilitation, Yale University School of Medicine, New Haven, Connecticut; and ¶¶Department of Orthopedic Surgery, Thomas Jefferson University, Philadelphia, Pennsylvania.

Acknowledgment date: August 1, 2007. Revision date: November 6, 2007. Acceptance date: November 6, 2007.

The manuscript submitted does not contain information about medical device(s)/drug(s).

Corporate/Industry funds were received in support of this work. No benefits in any form have been or will be received from a commercial party related directly or indirectly to the subject of this manuscript.

Supported by members of the Spine Trauma Study Group and an unrestricted educational grant from Medtronic Sofamor Danek.

This study was reviewed and approved by the University of Pittsburgh Medical Center IRB.

Address correspondence and reprint requests to Ahmad Nassr, MD, Department of Orthopedic Surgery, Mayo Clinic, 200 1st St SW, Rochester, MN 55905; E-mail: spinesurgeon@gmail.com

dislocations in the presence or absence of a traumatic disc herniation.

■ Materials and Methods

Twenty-nine members of the Spine Trauma Study Group were provided 10 clinical vignettes with imaging studies of patients with a traumatic unilateral or bilateral facet dislocation and surveyed on their choice of surgical approach (anterior, posterior, or combined). Cases were collected from a database of traumatic cervical dislocations treated at a Level-1 trauma center after Institutional Review Board approval was obtained. Patients in the case series had been evaluated with computed tomography and a prerelief MRI. A closed reduction had been attempted in all patients. Twenty-five surgeons completed the evaluations, which are included in this analysis. Surgeons were provided with computed tomography sagittal reconstructed images through the facets bilaterally, a midsagittal reconstruction, T2 weighted MRI axial and sagittal images, and plain radiographs.

Each case vignette was analyzed as to the influence of the patient's neurologic examination on intervention. Three clinical scenarios were assessed for each of the 10 cases including: a neurologically intact patient, a patient with an incomplete spinal cord injury, and a patient with a complete spinal cord injury. Surgeons' treatment algorithms were documented based on the clinical vignette and the setting of a successful and an unsuccessful closed reduction. Surgical approach options included: anterior alone, anterior-posterior, anterior-posterior-anterior, posterior alone, and a posterior-anterior approach.

Questionnaires were then analyzed for inter-rater agreement (Kappa) on choice of surgical approach in each of the 3 clinical scenarios. Surgeon interpretation of a unilateral or bilateral facet dislocation as well as their construal of the presence or absence of a traumatic disc was ascertained. Percent agreement and Fleiss' Kappa values were calculated for each scenario. Fleiss' Kappa was calculated using SPSS v13.0 (Chicago, IL). All other data analysis was performed using MED-CALC Software Version 8.1.0 (Mariakerke, Belgium).

■ Results

A total of 29 surveys were distributed to members of the Spine Trauma Study Group and 25 were returned for analysis. Significant variability was detected in surgeons' choice of surgical approach depending on the clinical scenarios presented. Surgeons demonstrated only slight agreement (Kappa = 0.094) for neurologically intact patient scenarios and this increased slightly for incomplete (Kappa = 0.133) and complete (Kappa = 0.15) spinal cord injury patient scenarios (Figure 1). Even with this significant variability, however, several key trends were observed based on the patients' neurologic status, injury type, and the presence or absence of disc herniations, as described below.

Neurologically Intact Scenario

Surgeons were most likely to choose an anterior only approach in the setting of a neurologically intact patient (37.1%), although this failed to reach statistical significance (Figure 2). If all anterior and anterior/combined approaches were considered together, surgeons chose an anterior procedure for the treatment of neurologically

intact patients in 69% of the cases ($P < 0.0001$). Moreover, if a traumatic disc herniation was present, and the patient was neurologically intact, surgeons chose an anterior-first procedure (anterior only, anterior-posterior, or anterior-posterior-anterior) 96% of the time (Table 1). If no disc herniation was detected then there was an increased incidence in treating with a posterior operation as the only procedure (39% of cases without disc herniation *vs.* 1% of cases with a herniation identified by rater, $P < 0.001$). Overall anterior procedures, either alone or initially in a combined approach, were more commonly selected when patients were neurologically intact.

In unilateral facet dislocations, the preferred surgical approach was either anteriorly alone (45% of cases) or posteriorly alone (32% of cases) (Table 2). When surgeons interpreted a bilateral injury, the most common choice of approach was an anterior-posterior procedure (42% of cases) (Table 2).

Incomplete Spinal Cord Injury Scenario

Significant variability existed in the treatment of incomplete spinal cord injury with 31.2% of cases being treated with an anterior alone approach, 28% with a posterior only approach, 24.4% with an anterior then posterior approach, 9.6% with a posterior then anterior approach, and 6.8% treated with an anterior-posterior-anterior approach (Figure 2). In the presence of a traumatic disc herniation, an anterior or anterior/posterior combined approach was used in 93% of the cases (Table 1).

As with the neurologically intact patients, unilateral injuries in an incomplete spinal cord injury patient were more likely to be treated with a single procedure, either posterior alone (40% of cases) or anterior alone (35% of cases, Table 2). For bilateral injuries, a combined anterior-posterior approach was most likely the surgical choice (47% of cases, Table 2).

Complete Spinal Cord Injury Scenario

In the patients with a complete spinal cord injury, there was a trend towards the use of posterior only procedures with 33% of cases being treated in this fashion ($P < 0.01$ compared with intact scenario, Figure 2). Surgeons selected an anterior or anterior/combined approach 91% of the cases in which there was an associated disc herniation (Table 1). When no disc herniation was present, most surgeons elected to treat the patients with a posterior only procedure (56% of cases).

There was also a trend towards the use of a posterior alone (45% of cases) or anterior alone (34% of cases) procedure in injuries interpreted as unilateral facet dislocations (Table 2). An increased use of combined approaches was observed, predominantly anterior-posterior procedures (43.5% of cases), when the injury was interpreted to be a bilateral facet dislocation (Table 2).

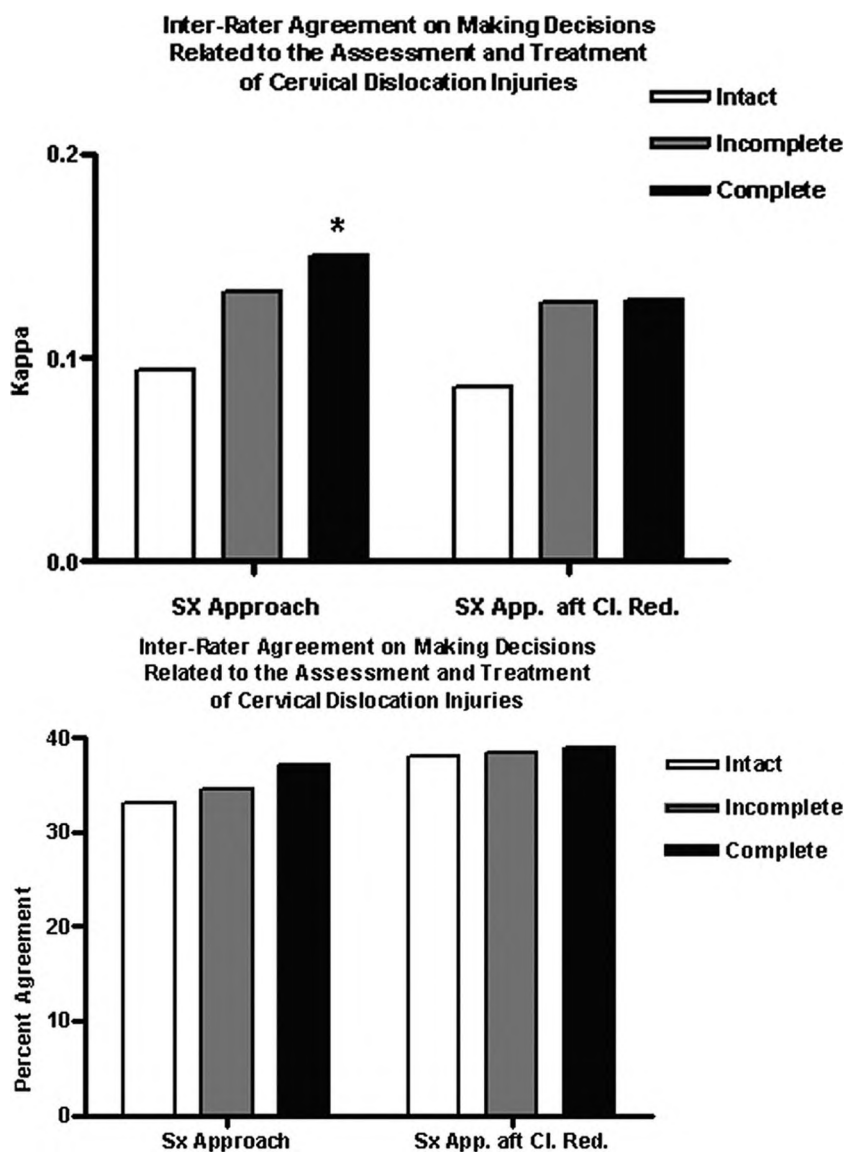


Figure 1. (A) Inter-rater agreement on surgical approach based on neurologic status as assessed by Fleiss' Kappa. (* $P < 0.05$ for difference between "complete" and "intact" without successful closed reduction). (B) Inter-rater percent agreement of choice of surgical approach based on neurologic status.

Discussion

Significant variability exists in the choice of surgical approach for the treatment of traumatic cervical facet dislocations. This analysis illustrates that the inter-rater agreement on choice of surgical approach for these injuries is relatively poor and improves only slightly when patients are assumed to have complete spinal cord injury. However, a trend towards the use of the anterior approach alone or as the initial procedure in a combined approach when dealing with a suspected disc herniation and in neurologically intact patients was observed. Presumably this approach is such that maximum decompression of the neural elements may be performed before any manipulation of the spinal column. In addition, we demonstrated a greater reliance on combined anterior and posterior approaches for the treatment for bilateral facet dislocations in comparison to unilateral injuries.

Few studies in the literature address the rationale of surgical approach selection in the treatment of traumatic cervical spine injuries. Facet dislocations have been his-

torically treated with posterior procedures. However, with improvements in preoperative imaging for assessment of the spinal canal and neural elements there has been a recent trend towards use of the anterior procedure either alone or as the first stage of a combined procedure in the presence or absence of a traumatic disc herniation. This may be related to a concern for neurologic worsening in patients with a suspected disc herniation.^{8,9,11,12,18,19}

In a recent study by Reindl *et al*,¹⁶ 41 consecutive patients with traumatic cervical dislocations were treated using the anterior approach. They demonstrated that the anterior approach could be used safely in these injuries and that reduction could be successfully accomplished with the anterior approach in the majority of cases with an approximate reduction failure rate of 25% necessitating the use of a posterior procedure. Ordonez *et al*²⁰ studied 10 patients in whom an anterior approach was used for decompression, reduction and fusion revealed a success rate of 90% with only 1 patient requir-

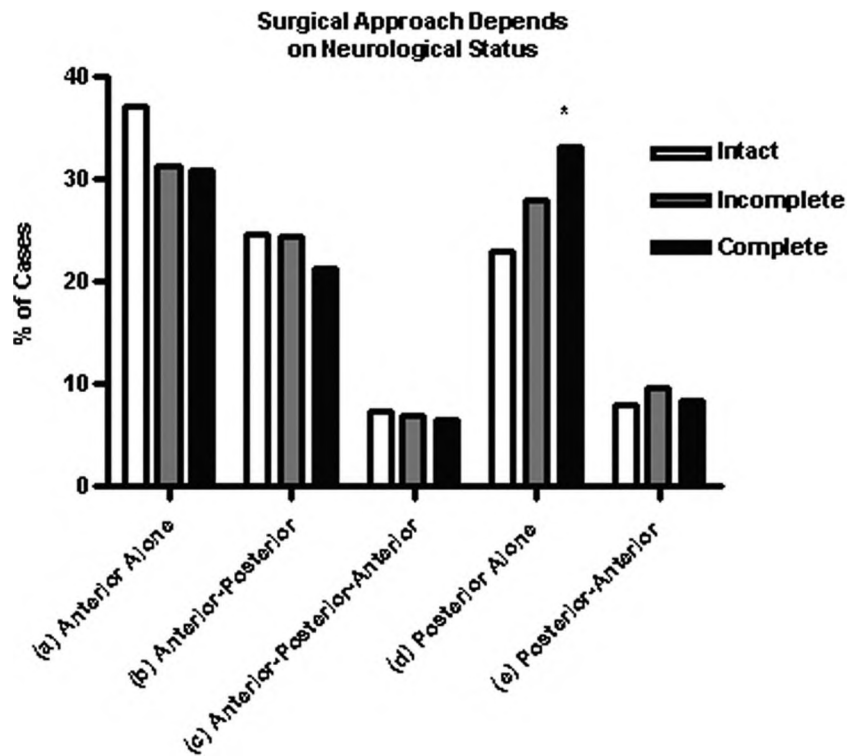


Figure 2. Percentage of cases treated by each surgical approach as a function of neurologic status. (* $P < 0.01$ for difference between “complete” and “intact” in proportion of cases treated by a posterior only approach).

ing a posterior approach for reduction and then subsequent anterior grafting and instrumentation for a failed anterior reduction attempt.

Johnson *et al*¹⁷ reviewed a series of 81 patients with unilateral or bilateral facet dislocations treated with an anterior discectomy and fusion with instrumentation. They found a 13% incidence of loss of reduction and associated this with the presence of either a facet or end-

plate fracture. They did not find an increased failure rate when comparing unilateral to bilateral facet dislocations.

In a study of 83 consecutive cervical dislocations, De Lure *et al*¹⁹ concluded that the use of anterior discectomy and fusion was useful in most cases except for the irreducible unilateral facet dislocation. In this scenario, the authors favored a posterior reduction followed by ante-

Table 1. Surgical Approach based on Surgeon Interpretation of Disk Status

Procedure	Neurologically Intact		Complete SCI		Incomplete SCI	
	Disk Herniation	No Disk Herniation	Disk Herniation	No Disk Herniation	Disk Herniation	No Disk Herniation
Anterior Alone	44	48	34	43	33	45
Anterior-Posterior	42	19	44	9	45	16
Anterior-Posterior-Anterior	16	2	16	0	17	0
Posterior Alone	1	56	1	82	0	70
Posterior-Anterior	3	17	8	13	7	17
Total (n)	106	142	103	147	102	148

Table 2. Surgical Approach on Surgeon Interpretation of Unilateral Versus Bilateral Facet Dislocation

Procedure	Neurologically Intact		Complete SCI		Incomplete SCI	
	Unilateral Dislocation	Bilateral Dislocation	Unilateral Dislocation	Bilateral Dislocation	Unilateral Dislocation	Bilateral Dislocation
Anterior Alone	67	25	53	24	56	22
Anterior-Posterior	19	42	13	40	18	43
Anterior-Posterior-Anterior	4	14	7	9	6	11
Posterior Alone	48	9	71	12	63	7
Posterior-Anterior	11	9	14	7	15	9
Total (n)	149	99	158	92	158	92

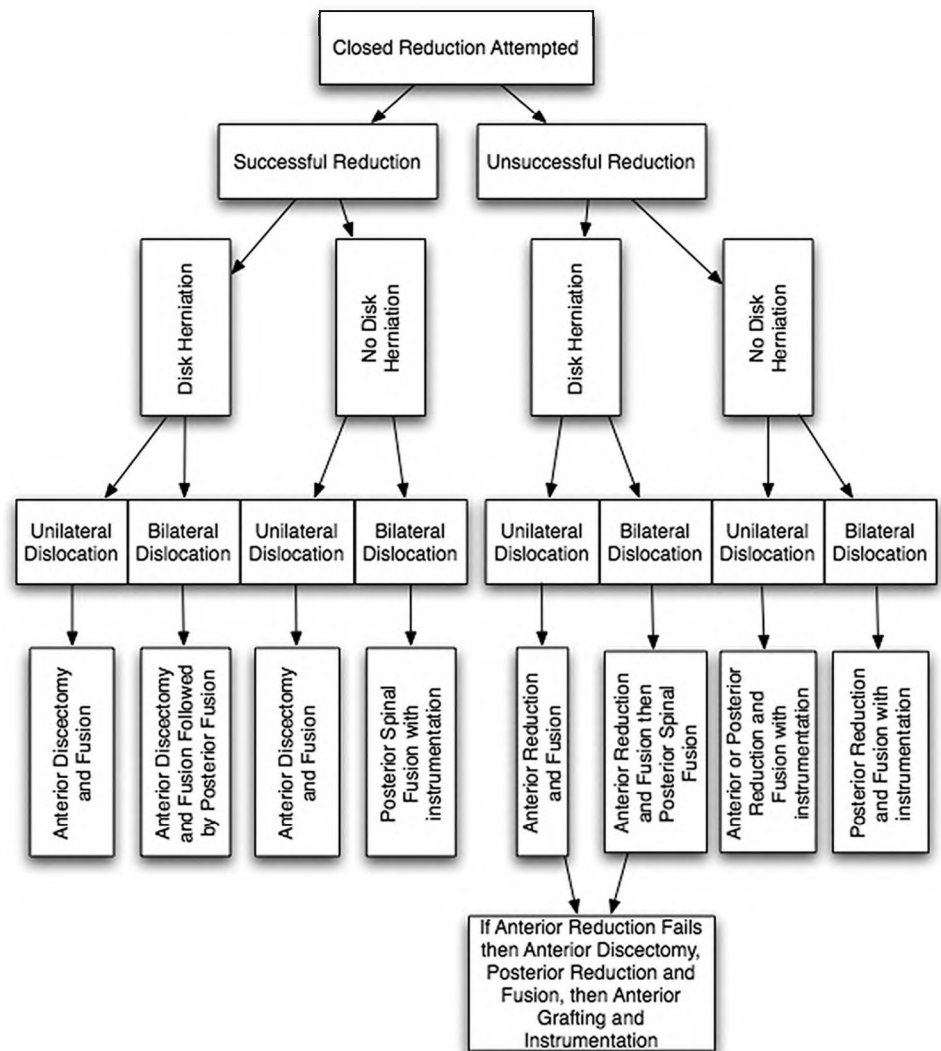


Figure 3. Treatment algorithm for traumatic cervical dislocations after an attempted closed reduction.

rior discectomy and fusion. Razack *et al*,¹⁵ in a retrospective study of anterior cervical discectomy and fusion using unicortical anterior plating, demonstrated good results with only 1 case of hardware failure in 22 patients. They concluded that this technique could be safely employed in patients with injuries that could be closed reduced before surgery.

Allred and Sledge²¹ reported a novel technique of treatment of irreducible cervical dislocation in the setting of a suspected disc herniation. The technique consists of an anterior cervical discectomy and grafting with the use of an anterior buttress plate followed by a posterior reduction and fusion. Their series of patients did well with no implant failures or neurologic worsening.

Abumi *et al*²² reported a posterior cervical reduction technique using cervical pedicle screw instrumentation in the setting of cervical disc herniation. They documented restoration of space available for the neurologic elements in all cases with no cases of neurologic worsening in their series of 16 patients.

Brodke *et al*²³ analyzed anterior *versus* posterior surgical approaches for traumatic cervical injuries associated with neurologic injury, but failed to demonstrate

any significant difference in neurologic recovery, patient outcome, or pseudarthrosis rates between approaches and concluded that either technique was safe and effective.

Based on our survey and the above-noted literature, we propose a treatment algorithm based on: the presence or absence of a traumatic disc herniation, the injury type (unilateral *vs.* bilateral), and success of a closed reduction attempt (Figure 3). As part of the algorithm an assessment of the spinal canal and the presence of a disc herniation is required with MRI or myelography. It should be noted that this algorithm is based on Level-IV evidence, and that it is not to be taken as a “gold-standard” but as a treatment option.

In cases of suspected disc herniation, we recommend the use of an anterior or anterior then posterior procedure to decompress the neural elements regardless of the patient’s neurologic status. If an anterior procedure is chosen as the initial approach in the presence of an irreducible or unreduced dislocation, due to the presence of a disc herniation, then an open reduction may be attempted, and if successful, maybe followed with anterior fusion and instrumentation. If the attempted anterior re-

duction is unsuccessful then a subsequent posterior reduction and stabilization will be necessary. The presence of a bilateral facet dislocation may signify a higher energy injury and thus the addition of posterior fixation maybe considered, due to loss of reduction seen occasionally with anterior only procedures.

■ Key Points

- Only slight agreement was seen among spine surgeons who were asked to evaluate surgical approach preference in the treatment of traumatic cervical facet dislocations.
- There is an increased likelihood that a surgeon will use an anterior approach for decompression when they interpreted the presence of a preoperative disc herniation.
- Surgeons tend to use more combined approaches when treating bilateral *versus* unilateral facet dislocations.

References

1. Glaser JA, Jaworski BA, Cuddy BG, et al. Variation in surgical opinion regarding management of selected cervical spine injuries. A preliminary study. *Spine* 1998;23:975–82; discussion 83.
2. Anderson RE, Drayer BP, Braffman B, et al. Spine trauma. American College of Radiology. ACR Appropriateness Criteria. *Radiology* 2000;215(suppl):589–95.
3. Blackmore CC. Evidence-based imaging evaluation of the cervical spine in trauma. *Neuroimaging Clin N Am* 2003;13:283–91.
4. Bloom AI. Re: Imaging of acute injuries of the cervical spine: value of plain radiography, CT, and MR imaging. *AJR Am J Roentgenol* 1996;166:218.
5. Clark CR, Igram CM, el-Khoury GY, et al. Radiographic evaluation of cervical spine injuries. *Spine* 1988;13:742–7.
6. Vaccaro AR, Madigan L, Schweitzer ME, et al. Magnetic resonance imaging analysis of soft tissue disruption after flexion-distraction injuries of the subaxial cervical spine. *Spine* 2001;26:1866–72.
7. Vaccaro AR, Falatyn SP, Flanders AE, et al. Magnetic resonance evaluation of the intervertebral disc, spinal ligaments, and spinal cord before and after closed traction reduction of cervical spine dislocations. *Spine* 1999;24:1210–7.
8. Eismont FJ, Arena MJ, Green BA. Extrusion of an intervertebral disc associated with traumatic subluxation or dislocation of cervical facets. Case report. *J Bone Joint Surg Am* 1991;73:1555–60.
9. Harrop JS, Sharan AD, Vaccaro AR, et al. The cause of neurologic deterioration after acute cervical spinal cord injury. *Spine* 2001;26:340–6.
10. Robertson PA, Ryan MD. Neurological deterioration after reduction of cervical subluxation. Mechanical compression by disc tissue. *J Bone Joint Surg Br* 1992;74:224–7.
11. Doran SE, Papadopoulos SM, Ducker TB, et al. Magnetic resonance imaging documentation of coexistent traumatic locked facets of the cervical spine and disc herniation. *J Neurosurg* 1993;79:341–5.
12. Harrington JF, Likavec MJ, Smith AS. Disc herniation in cervical fracture subluxation. *Neurosurgery* 1991;29:374–9.
13. McCulloch PT, France J, Jones DL, et al. Helical computed tomography alone compared with plain radiographs with adjunct computed tomography to evaluate the cervical spine after high-energy trauma. *J Bone Joint Surg Am* 2005;87:2388–94.
14. Arena MJ, Eismont FJ, Green BA. Intervertebral disc extrusion associated with cervical facet subluxation and dislocation. Fifteenth Annual Meeting of the Cervical Spine Research Society. Washington, DC, 1987.
15. Razack N, Green BA, Levi AD. The management of traumatic cervical bilateral facet fracture-dislocations with unicortical anterior plates. *J Spinal Disord* 2000;13:374–81.
16. Reindl R, Ouellet J, Harvey EJ, et al. Anterior reduction for cervical spine dislocation. *Spine* 2006;31:648–52.
17. Johnson MG, Fisher CG, Boyd M, et al. The radiographic failure of single segment anterior cervical plate fixation in traumatic cervical flexion distraction injuries. *Spine* 2004;29:2815–20.
18. Maiman DJ, Barolat G, Larson SJ. Management of bilateral locked facets of the cervical spine. *Neurosurgery* 1986;18:542–7.
19. De Iure F, Scimeca GB, Palmisani M, et al. Fractures and dislocations of the lower cervical spine: surgical treatment. A review of 83 cases. *Chir Organi Mov* 2003;88:397–410.
20. Ordonez BJ, Benzel EC, Naderi S, et al. Cervical facet dislocation: techniques for ventral reduction and stabilization. *J Neurosurg* 2000;92:18–23.
21. Allred CD, Sledge JB. Irreducible dislocations of the cervical spine with a prolapsed disc: preliminary results from a treatment technique. *Spine* 2001;26:1927–30; discussion 31.
22. Abumi K, Shono Y, Kotani Y, et al. Indirect posterior reduction and fusion of the traumatic herniated disc by using a cervical pedicle screw system. *J Neurosurg* 2000;92:30–7.
23. Brodke DS, Anderson PA, Newell DW, et al. Comparison of anterior and posterior approaches in cervical spinal cord injuries. *J Spinal Disord Tech* 2003;16:229–35.