

# Significance of CT and MR Findings in Sphenoid Sinus Disease

Kathleen B. Digre<sup>1</sup>  
 Charles E. Maxner<sup>2</sup>  
 Stephen Crawford<sup>3</sup>  
 William T. C. Yuh<sup>4</sup>

Disorders of the paranasal sinuses, particularly the sphenoid sinus, can be associated with significant disorders of the optic and other cranial nerves. We examined 100 consecutive routine CT scans, 100 posterior fossa CT scans, and 100 MR scans to look for evidence of sinus disease, especially of the sphenoid sinus. The sphenoid sinus was abnormal in 7% of scans by all methods. Other sinuses were more frequently abnormal, including maxillary (23%), ethmoid (34%), and frontal (16%). Although MR was more sensitive in detecting sinus inflammation in the ethmoid and maxillary sinuses, the frequency of visible sphenoid sinus abnormalities detected by MR was not significantly greater when compared with CT. Of those patients with abnormal sphenoid sinuses, 24% had visual problems associated with the abnormality.

It is well recognized that disorders of the paranasal sinuses, and in particular of the sphenoid sinus, can cause significant neuroophthalmic morbidity [1-4]. Recently, we studied two patients at the University of Iowa Neuroophthalmology Clinic who presented with visual system disorders caused by sphenoid sinus disease. Although the radiologic manifestations of their sphenoid sinus disease were relatively trivial, the findings were clinically significant. An incidental note of sphenoid sinus disease is frequently made when CT and MR scans are reviewed and is often regarded as having no clinical significance. Our clinical impression, however, was that sphenoid sinus disease on CT or MR is infrequent and may be clinically significant. Because of the following cases and our clinical impression, we prospectively evaluated CT and MR scans done at the University of Iowa to determine the incidence of sinus abnormalities and its associated visual disorders.

Received June 6, 1988; accepted after revision November 1, 1988.

This work was supported in part by a grant from the Heed Ophthalmic Foundation (1986-1987). This research was also supported in part by an unrestricted grant from Research to Prevent Blindness at the University of Iowa. Dr. Maxner was supported by the E. A. Baker Foundation for the Prevention of Blindness, Toronto, Canada.

<sup>1</sup> Departments of Neurology and Ophthalmology, University of Utah, Salt Lake City, UT 84142. Address reprint requests to K. B. Digre.

<sup>2</sup> Division of Neurology, Department of Medicine, Dalhousie University, Halifax, N.S., Canada B3H 2Y9.

<sup>3</sup> Department of Radiology, University of Utah, Salt Lake City, UT 84142.

<sup>4</sup> Department of Radiology, University of Iowa, Iowa City, Iowa 52242.

*AJNR* 10:603-606, May/June 1989  
 0195-6108/89/1003-0603  
 © American Society of Neuroradiology

## Case Reports

### Case 1

A 27-year-old woman presented with painless loss of vision in her right eye of 10 days duration. However, she reported a 10-month history of right retroorbital and frontal headache associated with nasal stuffiness. On examination, she had evidence of bilateral optic nerve dysfunction with the right eye more significantly impaired. Both optic disks appeared hyperemic with the right being more edematous.

There was no proptosis or motility disturbance, and the remainder of the neurologic examination was normal. A CT scan (Fig. 1) revealed evidence of partial opacification of the left sphenoid sinus. IV antibiotic treatment was instituted, but visual parameters failed to improve. A sphenoidotomy was performed to drain the sinus, and biopsy showed chronic inflammation on both sides of the sinus. The patient's vision recovered within 20 days of surgery.

### Case 2

A 68-year-old man presented with a 4-week history of left retroorbital pain, numbness of the left cheek, and burning dysesthesias over the left forehead. On examination, he had a

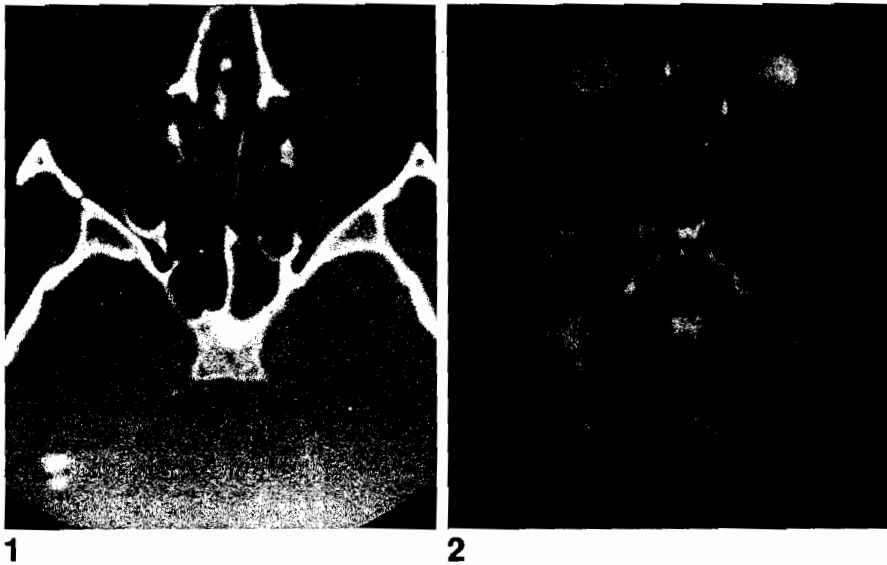


Fig. 1.—Axial CT scan at wide window settings shows marked mucosal thickening as well as hyperostosis of sphenoid wall, indicating chronic inflammatory disease in left sphenoid compartment.

Fig. 2.—T2-weighted, SE 2000/100, MR image shows focal inflammation in posterior aspect of sphenoid sinus. Higher signal intensity of mucosal change distinguishes it from lower signal intensity of clival marrow space.

diminished left corneal reflex, left ptosis, and miosis that proved pharmacologically to be a postganglionic Horner syndrome. Raeder paratrigeminal syndrome was diagnosed. An MR scan (Fig. 2) revealed a soft-tissue density in the sphenoid sinus. Several courses of antibiotics brought short-term relief each time. Eventually, a sphenoidotomy and biopsy showed chronic inflammation. Within the month, the patient was asymptomatic and his facial sensation had returned to normal.

### Materials and Methods

From April to July 1986, the authors (two radiologists and two neurologists) together reviewed 100 consecutive routine CT scans, 100 posterior fossa CT scans, and 100 MR scans on patients more than 12 years old. There were 144 inpatients and 156 outpatients.

Routine CT scans were obtained in the axial plane at 8-mm intervals by using either a Picker 1200 Synerview\* or a Siemens DRH.<sup>†</sup> Scans done for posterior fossa evaluation were obtained at 5 mm through the posterior fossa and at 8 mm through the cerebrum. Contrast enhancement was not a requisite for inclusion in the study.

MR was performed with a 0.5-T superconductive unit.<sup>‡</sup> The pulse sequences included T1-weighted, 400–600/20–26 (TR range/TE range), T2-weighted, 2000–2300/80–100, spin-echo (SE), and, occasionally, inversion recovery (IR), 2500–3500/500/40 (TR range/T1/TE), images. Axial T2-weighted and sagittal T1-weighted SE pulse sequences were routinely obtained. Coronal images were obtained with either a T2-weighted SE or IR pulse sequence. All slices were 10 mm thick.

For all patients we noted whether sinus development was normal or not. An abnormal sinus was defined by CT scanning as any mucosal thickening or fluid density within the sinus, and by MR imaging as signal intensity in the sinus greater than air on the T1-weighted images or greater than CSF on the T2-weighted images.

Even though focal bone and soft-tissue changes may be overlooked on 10-mm sections, careful attention was paid to all the paranasal sinuses that could be visualized on each study. Any abnormality was noted.

### Results

Table 1 identifies the frequency with which abnormalities were noted in the various sinuses by each radiologic procedure. The maxillary sinus was frequently not visualized on either the routine CT scans or the posterior fossa CT scans. We were particularly interested in the sphenoid sinus, and this was adequately visualized in all the studies. Sphenoid abnormalities were seen in 7% of the routine CT scans, 8% of the posterior fossa studies, and 6% of the MR scans, thus representing a total of 21 patients.

The charts of the 21 patients with abnormal sphenoid sinus studies were reviewed. The group consisted of 12 inpatients and 9 outpatients, 20 to 73 years old (mean, 40.5 years). There were 13 men and eight women. Visual problems attributable to sinus disease occurred in five of the 21 patients. Three had relative afferent pupillary defects indicating optic nerve dysfunction. Two had visual field defects. The presence of visual disorders did not appear to correlate with the severity of the sinus disease. Four patients were recovering from trauma and three patients were intubated. Two patients complained of headache. One patient had meningitis. The types of abnormalities we noted are listed in Table 2; mucosal membrane thickening was the most common. Interestingly, the formal radiology reports on the 21 patients with sphenoid abnormalities were reviewed and only nine reports noted the sphenoid findings. The scans not reported as abnormal, however, showed easily missed minor abnormalities.

The ethmoid and maxillary sinuses were more frequently noted to have abnormalities. In particular, MR imaging demonstrated ethmoid problems in 34% of the studies. The type of abnormalities seen in the ethmoid sinus included mucosal thickening (CT: 2; posterior fossa CT: 5; MR: 29), opacification (CT: 4; posterior fossa CT: 2; MR: 3), soft-tissue mass (CT: 1; posterior fossa CT: 2), and air fluid level (MR: 1). The types of abnormalities seen in the maxillary sinus included mucosal thickening/inflammation (CT: 1; posterior fossa CT: 1; MR: 8), opacification (MR: 5), air fluid level (CT: 1), and polyps (pos-

\* Picker International, Cleveland, OH.

† Siemens Corp., Erlangen, West Germany.

‡ Picker International, Cleveland, OH.

TABLE 1: Abnormal Sinuses

	CT			Posterior Fossa CT			MR		
	No.	(%)	NV	No.	(%)	NV	No.	(%)	NV
Sphenoid	7	(7)	0	8	(8)	0	6	(6)	0
Maxillary	2	(14)	86	2	(10)	80	22	(23)	4
Ethmoid	7	(9.5)	27	8	(8.5)	9	33	(34)	2
Frontal	1	(1)	0	1	(1)	5	16	(16)	2

Note.—NV = not visualized adequately.

TABLE 2: Sphenoid Sinus Abnormalities

Procedure	Finding (No.)
CT (n = 7)	Mucosal thickening (4) Congenitally absent (1) Opacification (1) Air fluid level (1)
Posterior fossa CT (n = 8)	Mucosal thickening (4) Soft-tissue density (1) Opacification (1) Craniopharyngioma (1) Lymphoma of sinuses (1)
MR (n = 6)	Mucosal inflammation (5) Opacification (1)

terior fossa CT: 1; MR: 1). Estimation of the incidence of antral disease may be higher than found, since part or all of the antrum may not be visible on axial brain studies. Frontal sinuses demonstrated the following abnormalities: undeveloped sinus (CT: 3; posterior fossa CT: 12; MR: 6), mucosal inflammation/thickening (MR: 9), opacification (CT: 1; MR: 1), and soft-tissue mass (posterior fossa CT: 1).

## Discussion

Several publications [5-9] have reviewed the anatomic features of the sphenoid sinus and emphasized the proximity of important neurovascular structures such as the optic nerve, first two divisions of the trigeminal nerve, and the carotid artery to the internal environment of the sphenoid. In particular, Fujii et al. [9], in a study of 25 cadavers, found that in 4% of specimens, only the optic nerve sheath and sinus mucosa separated the optic nerve from the sinus. In 78%, less than 0.5 mm thickness of bone separated the nerve from the sinus. Similarly, in 8% of specimens, there was no bone separating the carotid artery from the sinus. Using high-resolution CT, Johnson et al. [6] reported that 14% of their patients had no bony separation of the carotid artery.

It is obvious that inflammatory and neoplastic processes are capable of producing significant neuroophthalmic dysfunction, and so in the face of neuroophthalmic complaints, one must be vigilant in searching for sphenoid sinus disease.

How much significance should one place on the findings of partial or complete opacification of the sphenoid sinus in neuroradiologic studies? Schatz and Becker [10], in a review of the CT anatomy of the sphenoid sinus, noted that the mucosa of the sinus so closely approximates the bone that the normal mucosa cannot be visualized on CT and, therefore,

any bulge of soft tissue that is seen in the sinus is abnormal. Axelsson and Jensen [11] found that when plain radiography was performed on 300 patients specifically referred with a clinical diagnosis of sinusitis, 68% had abnormal studies but none showed abnormalities in the sphenoid sinus. Thus, even in a high-risk group for sinus disease, sphenoid sinus involvement was uncommon. In a review of sella turcica tomograms, Dolan [5] found that 10% of sphenoid sinuses had incidental mucous membrane thickening. These studies suggest that incidentally noted sphenoid sinus disease is theoretically rare.

In our review of 300 radiographic studies, the sphenoid sinus was visualized in all cases. Abnormalities were detected in only 7% of the routine CT scans, 8% of the posterior fossa CT scans, and 6% of the MR scans, confirming that even with more advanced radiologic techniques (as compared with plain radiography), demonstration of sphenoid sinus disease is uncommon. The number of abnormal sphenoid sinuses detected was not increased with MR, even though MR was much more sensitive in detecting all paranasal sinus disease when compared with CT. Of the 21 patients with detected sphenoid abnormalities, the sphenoid disease produced neuroophthalmic dysfunction in five individuals. Thus, in 24% of the patients the detection of sphenoid disease had important clinical significance.

Clinicians and radiologists managing patients with neuroophthalmic complaints should appreciate the proximity of important neurovascular structures to the sphenoid sinus and recognize that sphenoid sinus disease can threaten vision. Abnormalities noted on CT and MR in the appropriate clinical context should not be casually dismissed, but should be appreciated as being the possible cause of the patient's problem. Minimal sphenoid sinus disease seen in CT or MR does not exclude the sphenoid sinus as a possible cause for visual problems. Although MR increases the yield in detecting ethmoid, frontal, and maxillary abnormalities, it does not change the yield of sphenoid lesion identification.

## REFERENCES

- Levine H. The sphenoid sinus, the neglected nasal sinus. *Arch Otolaryngol* 1978;104:585-587
- Schramm VL, Myers EN, Kennerdell JS. Orbital complications of acute sinusitis: evaluation, management, and outcome. *Otolaryngol Head Neck Surg* 1978;86:221-230
- Dale BA, MacKenzie JJ. The complications of sphenoid sinusitis. *J Laryngol Otol* 1983;97:661-670
- Rothstein J, Maisel RH, Berlinger NT, et al. Relationship of optic neuritis to disease of the paranasal sinuses. *Laryngoscope* 1984;94:1501-1508
- Dolan KD. Paranasal sinus radiology, Part 3A: sphenoidal sinus. *Head*

- Neck Surg* 1982;5:164-176
6. Johnson DM, Hopkins RJ, Hanafee WN, Fisk JD. The unprotected parasphenoidal carotid artery studied by high resolution computed tomography. *Radiology* 1985;155:137-141
  7. Renn WH, Rhoton AL Jr. Microsurgical anatomy of the sellar region. *J Neurosurg* 1975;43:288-298
  8. Maniscalco JE, Habal MB. Microanatomy of the optic canal. *J Neurosurg* 1978;48:402-406
  9. Fujii K, Chambers SM, Rhoton AL Jr. Neurovascular relationship of the sphenoid sinus. *J Neurosurg* 1979;50:31-39
  10. Schatz CJ, Becker TS. Normal CT anatomy of the paranasal sinuses. *Radiol Clin North Am* 1984;22:107-118
  11. Axelsson A, Jensen A. The roentgenologic demonstration of sinusitis. *Am J Roentgenol Rad Ther Neurol Med* 1974;122:621-627