

Definition of the Role of Contemporary Surgical Management in Cisternal and Parenchymatous Cysticercosis Cerebri

William T. Couldwell, M.D., Chi-Shing Zee, M.D., and Michael L. J. Apuzzo, M.D.

Departments of Neurosurgery (WTC, MLJA) and Neuroradiology (CZ), University of Southern California School of Medicine, Los Angeles, California

With increasing immigration from endemic regions, the incidence of neurocysticercosis in North America is rising. This retrospective study was undertaken to examine the role of surgery in those cases presenting with large cystic parenchymal and cisternal lesions in the current era of anthelmintic agents administered orally. A total of 237 patients presented with newly diagnosed neurocysticercosis to our institution over a recent 5-year period (mean age, 31.2 years). Among those who presented with cystic mass lesions predominantly affecting the brain parenchyma and cisternal spaces, 20 (8.4%; mean age, 40.2 years) with large cystic lesions subsequently underwent surgical intervention, either because of an emergent presentation or because they were refractory to medical management. Clinical presentation included increased intracranial pressure, focal neurological deficit, and seizure. Radiographic imaging (computed tomography and/or magnetic resonance imaging) demonstrated 12 cases with cisternal lesions, 7 with parenchymal lesions, and 1 involving both compartments. Based on imaging guidelines, 30 operative procedures (excluding shunt revisions) were performed (14 craniotomies, 8 cerebrospinal fluid diversions, 7 stereotactic procedures, and 1 burr hole drainage). Fifteen (75%) showed neurological or symptomatic improvement over a median follow-up period of 36.4 months. There were three surgery-related complications and no deaths. (*Neurosurgery* 28:231-237, 1991)

Key words: Brain cyst, Computed tomography, Cysticercosis, Magnetic resonance imaging, Praziquantel, Stereotaxis

INTRODUCTION

Infestation of the central nervous system with the larval form of the porcine intestinal tapeworm *Taenia solium*, cysticercosis cerebri, is becoming increasingly common in North America because of immigration from endemic regions. Symptomatic involvement occurs when man serves as the inadvertent intermediate host for the larvae; usually, man is the sole asymptomatic definitive host. Infestation occurs from the ingestion of contaminated foods (especially uncooked vegetables that have been fertilized with porcine manure containing proglottids or ova), or autoinfection resulting from either reverse peristalsis or anal-oral contamination from ingestion of ova released by adult intestinal forms (15, 18, 41). The disease was first described in the United States by Walter Dandy in 1927 (5) and is predominantly an affliction of underdeveloped countries, with the majority of cases described in developed nations being harbored by immigrants (15, 33). Of epidemiological interest to support this was the 2% incidence reported in an autopsy series in Berlin over a century ago (13). In endemic areas, such as central and South America, eastern Europe, and Asia, the disease is prevalent; in Mexico, general autopsy incidence has been reported as 3.5 to 4% (3, 36), and it accounts for up to 11% of all neurosurgical procedures in selected centers (23). The majority of these cases, however, are asymptomatic (12).

Neurological manifestations occur in 60 to 92% of infestations (21). Anatomically, the larvae may infest the parenchymal, cisternal (subarachnoid), or ventricular spaces, although often, a single case may have involvement of more than one compartment. The neurological manifestations of the disease are protean, and symptoms depend on the magnitude of the infestation, the neuroanatomical location of the cysts, and the immune response of the host. Other system involvement may occur with larval deposition in myocardial or skeletal muscle or ocular or cutaneous tissues.

The potential for poor outcomes in both intraventricular

(2, 10) and basilar racemose forms (16, 20, 28, 29, 40) of the disease are well recognized. Parenchymal lesions, on the other hand, are acknowledged to occupy the benign end of the symptomatic spectrum (14). The introduction of the anthelmintic agents praziquantel (4, 6-8, 18, 31, 34, 35, 38, 43) and, more recently, albendazole (8, 9, 35, 37) has had a major impact on the management of parenchymal lesions; however, the present role of surgery in these cases is not defined. The optimal surgical management of large basilar cisternal cysts, which are more frequently refractory to medical treatment, is also not established in the contemporary literature. We have therefore reviewed our surgical experience with such lesions in an attempt to determine the current role of surgery in their management.

CLINICAL MATERIAL AND METHODS

Diagnostic criteria

The diagnosis of neurocysticercosis is confirmed by a number of epidemiological, symptomatic, serological, and radiographic findings consistent with the infestation. In the authors' experience, the radiographic evaluation, especially computed tomographic (CT) scans and, more recently, magnetic resonance imaging (MRI), in conjunction with cerebrospinal fluid (CSF) serology, offer the most specific diagnostic information. The soft tissue or muscular calcifications evident on long bone radiographs are reliable and specific but are not always present (10, 15, 39). Examination of stool for ova is routinely performed but is not sensitive, nor is it pathognomonic for determination of intracranial pathology; however, this information is of value from an epidemiological perspective by virtue of identifying a potential infectious source. CSF or serum eosinophilia is indicative of a parasitic infection and may offer supportive evidence but is neither specific nor sensitive. Serological assays are well known to be of limited diagnostic value, being positive in only up to 60% of previously reported series of cysticercosis cerebri (27). In addition, the delay in obtaining results offers limited clinical guidance in the treatment of

the symptomatic patient. Newer serological methodologies hold future hope for increased diagnostic accuracy, as a recently published series from Mexico reports an 87% sensitivity with CSF serology using enzyme-linked immunoadsorbent assay (32).

Case selection

For the basis of this study, cases of newly diagnosed central nervous system cysticercosis presenting to the University of Southern California teaching hospitals were reviewed. Over a 5-year interval (January 1982 to January 1987), there were 237 such cases, with a mean age of the entire population of 31.2 years at presentation. In all cases, CT scan and/or MRI was performed to aid in the diagnosis and to determine the most appropriate therapeutic strategy.

Of the reviewed cases, 20 of 237 patients (8.4%) presented with symptomatic large cysternal and/or parenchymal cysts that subsequently were surgically drained or removed and were the focus of the present analysis. Inclusion criteria for surgical intervention were: 1) rapidly progressive symptoms or neurological deficits from cyst mass effect refractory to an attempted trial of standard medical therapy (fluid restriction, osmotic diuretic, and glucocorticoid administration) (15 cases); 2) progression of symptoms despite the administration of the anthelmintic agent praziquantel and glucocorticoids (4 cases); and 3) emergent presentation requiring surgical decompression (1 patient).

The mean age of the patients in this series was 40.2 years, with a range of 24 to 64 years. All patients were of Hispanic origin, and all had histories consistent with country of origin or recent travel to an endemic area. There was no sex difference (male to female ratio, 1:1). Table 1 summarizes the location of the lesions and their mode of presentation.

SURGICAL MANAGEMENT AND RESULTS

Parenchymal cysts

Seven patients in this series presented with large symptomatic parenchymal cysts requiring drainage. Of the 9 large symptomatic cysts in the 7 patients (2 patients harbored 2 large cysts), 4 were frontal, 3 were frontoparietal (central), and 1 each were in the temporal lobe frontotemporally. These patients underwent a variety of surgical interventions, including stereotactic drainage, craniotomy, and burr hole drainage of a superficial cyst (Table 1).

Four patients underwent a primary stereotactic drainage procedure with placement of permanent cyst catheter-reservoirs. A Cordis catheter with a Rickham reservoir has proved suitable, and no complications of catheter obstruction have been encountered with this system. The need for subsequent aspiration of the cyst via the indwelling catheter was individualized for symptom control among the patients in this series, but ranged from 0 to 10 times with an average frequency of every 3 weeks. All of these patients improved clinically and had radiographic resolution of their targeted cysts. The single patient in which primary craniotomy was performed for an isolated parenchymal cyst suffered a recurrence; at surgery, adhesions of the cyst wall to the surrounding parenchyma precluded total operative removal. He subsequently required a stereotactic procedure with placement of a cyst catheter-reservoir for definitive treatment. One patient presented with large frontal intraparenchymal and suprasellar cysternal cysts producing significant mass effect; a frontal craniotomy was performed with drainage of the frontal cyst and excision of the suprasellar racemose collection, which achieved adequate decompression and resolution of symptoms. The patient harboring a superficial cyst managed by burr hole drainage had no further occurrence of cysts.

Cisternal cysts

Twelve patients presented with predominantly cysternal involvement, the most common locations being suprasellar, Sylvian, and quadrigeminal (Table 1). The major symptom associated with these large cysts in these locations was headache, whether or not there was associated hydrocephalus from major midline shift or intraventricular involvement. Focal deficit was present in 25% of these patients and was predictable from the location of the lesion (e.g., visual loss with a suprasellar cyst and hemiparesis in a patient with a large Sylvian lesion). Nine patients underwent primary craniotomy and open resection of cysts. In all of these cases, multiple cysts were removed from the basilar cisterns at craniotomy; at surgery, the cysts were extracted easily with gentle suction and irrigation. All patients received preoperative glucocorticoids (dexamethasone, 4 mg every 6 hours perioperatively). In the 4 cases of intraoperative cyst rupture, there was no incidence of chemical meningitis, as reported by other authors (19, 22). Of the patients who underwent primary craniotomy for cyst removal, none required further open surgical intervention. One patient, however, did require subsequent shunts for intraventricular involvement and hydrocephalus. Two of the 12 patients were treated initially by CT-scan-guided stereotactic puncture and aspiration of the cysternal cysts; both of these patients required subsequent open surgical removal of recurrent lesions because of inadequate decompression. This probably was due to the limitation of aspirating multiple cysts through a single trajectory. Two patients with moderate-sized quadrigeminal lesions that distorted the tectal region resulting in aqueductal stenosis were treated successfully with primary ventriculoperitoneal shunts.

Follow-up

There was a total of 30 operative procedures performed on the 20 patients. Of the 30 procedures, 14 were craniotomies, 8 were CSF diversions, 1 was a burr hole drainage, and 7 were stereotactic procedures (1 aspiration and 6 cyst catheters). Fifteen of the 20 patients (75%) improved symptomatically over a median follow-up period of 36.4 months. There were no deaths in the series. Of the patients that presented with a neurological deficit, 88% (7 of 8 patients) showed either marked improvement or reversal of their deficits. Three patients (15%) experienced surgery-related complications. In one 54-year-old man, a deep vein thrombosis occurred 1 week after craniotomy for a suprasellar cyst, which resolved with anticoagulant therapy with no sequelae. In another, a cyst catheter-reservoir infection by a Gram-negative enteric organism that subsequently required open surgical removal for resolution occurred 1 month postoperatively; the patient suffered a mild left arm paresis that was unchanged after 18 months. The third was a complication of chronic pneumocephalus after ventriculoperitoneal shunt placement for hydrocephalus. Water-soluble contrast cisternography failed to disclose the source of the leak that resolved with conservative therapy 3 weeks postoperatively.

ILLUSTRATIVE CASES

Review of this series permitted analysis of the medical treatment and surgical options for the management of these lesions.

Case 1: Parenchymal cysts

A 43-year-old Hispanic man presented to the emergency department in extremis, exhibiting signs of midbrain compression and herniation. A history given by the family indicated several years' history of tonic clonic seizures treated successfully with phenytoin. A CT scan demonstrated a massive left frontal ring-enhancing cyst with marked midline shift (Fig. 1, A and B). In addition, low-density edema surrounded the lesion. An emergent twist-drill craniotomy

TABLE 1
Cisternal and Parenchymal Cysts Requiring Surgical Drainage^a

Location of Lesion	Symptoms	Initial Treatment	Secondary Treatment ^b
Cisternal			
Sylvian (3)	Headache (2) hemiparesis (1)	Craniotomy (2) Ventriculoperitoneal shunt (1)	None Craniotomy*
Suprasellar (6)	Headache (3) Visual loss (1) Syncope (2)	Stereotactic (1) Craniotomy (5)	Craniotomy* Ventriculoperitoneal shunt (1)
Quadrigeminal (4)	Headache (4)	Stereotactic (1) Craniotomy (1) Ventriculoperitoneal shunt (2)	Craniotomy* None None
Cisterna magna (2)	Headache (2) 6th nerve palsy (1)	Craniotomy (1) Ventriculoperitoneal shunt (1)	None Craniotomy
Parenchymal			
	Headache (5) Seizure (2) Focal deficit (4)	Craniotomy (1) Stereotactic (4) Ventriculoperitoneal shunt (1) Burr hole (1)	Stereotactic* None Stereotactic* None
Parenchymal and Cisternal			
	Hemiparesis Headache	Craniotomy	None

^a The numbers in parentheses indicate the number of cases. Some patients had cysts that required drainage in more than one location.

^b * Procedures performed for persistent or recurrent cysts.

was performed with drainage of approximately 20 ml of clear fluid. The patient's condition improved immediately, and normal mental status was achieved within 12 hours of the procedure. Two days after admission, a cyst catheter-reservoir was stereotactically inserted to allow repeat aspiration of the cyst. The cyst was progressively tapped to its total resolution over the 7 days after admission (Fig. 1C). The patient subsequently required intermittent cyst aspiration (approximately every 2 weeks) for recurrent headache for a period of 3 months. He was treated for a 14-day period with praziquantel and had resolution of his other smaller parenchymal cysts. He was asymptomatic 12 months postoperatively.

Cisternal cysts alone and cisternal cysts combined with parenchymal cysts

There were 12 patients in the series with predominantly cisternal involvement and 4 patients with combined cisternal and either intraparenchymal or intraventricular cysts. This illustrates the occasional need for a combination of therapeutic approaches in a single patient.

Case 2

A 49-year-old man who was born in Mexico presented with several weeks' history of progressive headache, nausea, and instability of gait. A CT scan revealed ventriculomegaly. Ventriculostomy was performed and water-soluble contrast ventriculography revealed obstruction at the foramen of Monro, but no intraventricular cyst was visualized. A ventriculoperitoneal shunt was placed, and the patient's symptoms resolved. He presented again 6 months later with similar complaints; a CT scan at that time revealed multiple large right Sylvian cisternal cysts (Fig. 2). Ventricular size had returned to normal in the interval since shunt placement. His progressive symptoms prompted an open frontotemporal procedure for drainage of the Sylvian lesions. Postoperatively, the patient's symptoms resolved; however, he presented again 8 weeks after craniotomy with progres-

sive headache. A CT scan at this admission demonstrated no recurrence of the Sylvian lesions but interim development of a large left frontal parenchymal cyst. Stereotactic placement of a cyst catheter-reservoir was performed, which enabled adequate control of the cyst; at 24 months after craniotomy he showed no recurrence clinically or radiographically.

DISCUSSION

Parenchymal cysts

Cysticercosis cellulosa is a cyst 3 to 18 mm in diameter found usually in the brain parenchyma (26). Most patients with this form of infection are asymptomatic or present with seizures. The life span of the larvae is self-limited; the cyst usually dies within 7 to 10 years of infestation (24). With larval death in parenchymal lesions, however, the cyst may rapidly enlarge, with imbibition of fluid secondary to a loss of osmotic regulation, and produce symptoms by compression of surrounding parenchyma (as seen in Case 1). As one might expect, and as was the case in 8 patients in our series, this is the most frequent time of symptomatic presentation in patients with large space-occupying cysts.

The use of the anthelmintic agent praziquantel, a heterocyclic pyrazinoisoquinolone (Biltricide, Miles Pharmaceuticals), has been shown in several studies to be effective against parenchymal neurocysticercosis (31, 34, 35, 38). Recently, another agent, albendazole, has undergone clinical trials in Mexico (9, 35, 37). This work suggests that it also is a potent antiparasitic, comparable or superior in efficacy to praziquantel in the treatment of this disorder, and is presently the drug of choice in Mexico (9, 35). These orally administered agents should be considered standard initial therapy for this form of disease. One caveat, however, recognized with the use of

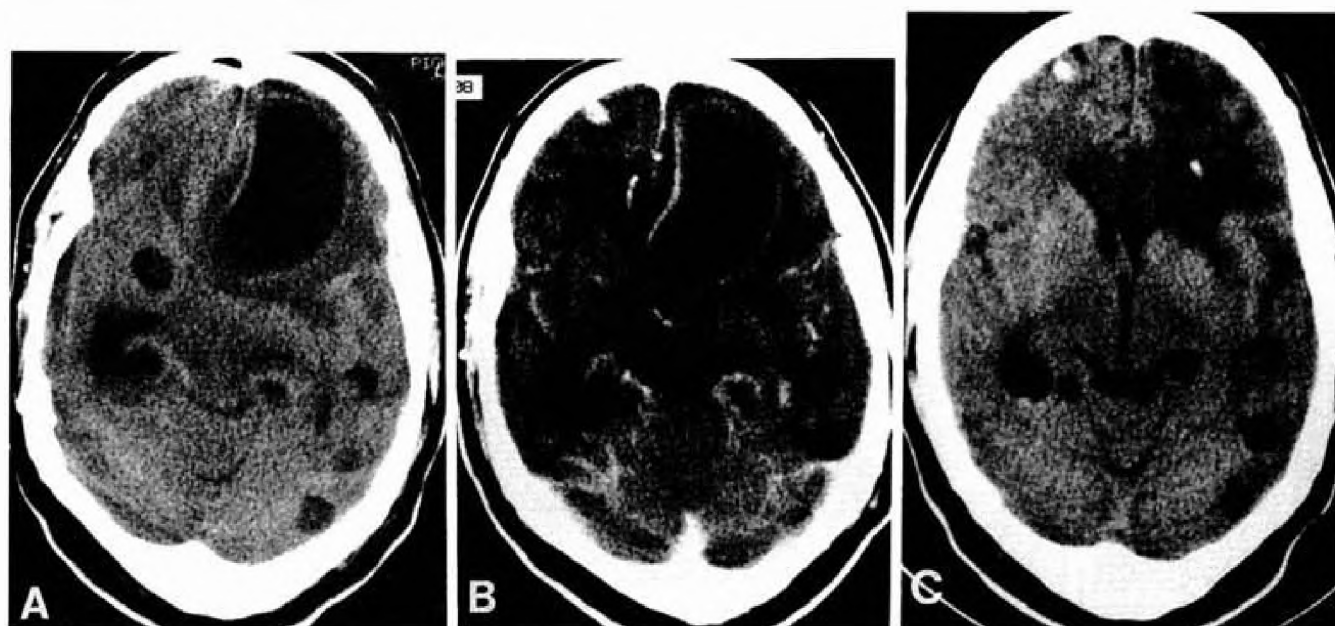


FIG. 1. A 43-year-old man with decerebrate posturing and a history of progressive headache and untreated seizures. An unenhanced CT scan (A) reveals a large left frontal cyst with marked mass effect. After administration of intravenous contrast (B), a thin enhancing cyst wall is evident, which suggests Stage 2 disease (dying cyst). Note the additional smaller asymptomatic cysts throughout the parenchyma. The meningeal enhancement indicates associated cysticerebral arachnoiditis. After stereotactic placement of a cyst catheter-reservoir, the cyst was progressively drained over a period of 1 week. A follow-up CT scan 2 weeks after admission (C) shows resolution of the large frontal cyst with the indwelling catheter. This patient was given praziquantel concurrently and had successful resolution of other intracranial cysts.

praziquantel, is exacerbation of existing symptoms produced by inflammation invoked by the dying cyst, usually manifest by transient headache, nausea, and seizures. This may, in part, be alleviated with the administration of corticosteroids (4, 6, 7). Vázquez et al. (43) have demonstrated a reduction of plasma levels of praziquantel by 50% with the administration of dexamethasone; thus, these authors advocate its use only if symptoms are severe (8). In the 4 patients in this series treated with praziquantel, symptoms rapidly progressed to require surgical intervention despite its use, but smaller asymptomatic parenchymal cysts were successfully eradicated. One liability in its use, therefore, is potential exacerbation of intracranial pressure and symptoms, especially during the first week of administration. This series has demonstrated the existence of a small subgroup of patients in which such a malignant clinical course may necessitate surgical intervention.

In the rare case of parenchymal cysts in which surgical intervention is required, there exist several potential surgical strategies: 1) cyst diversion to the subarachnoid space or peritoneal cavity to decrease local mass effect; 2) craniotomy with drainage of the cystic component and possible removal of the solid mural granuloma; and 3) stereotactic methodologies for the drainage of cyst contents and biopsy of the wall if deemed appropriate.

Primary cyst diversion has fallen from clinical favor for two reasons: the potential for seeding of the infection to other cranial or extracranial sites and the production of chemical arachnoiditis or peritonitis from spillage of toxic cyst contents. Craniotomy offers the potential advantage of open surgical excision of the entire cyst wall and scolex, thereby decreasing the rate of cyst recurrence. Although this seems appealing, clinical practice often finds intraparenchymal cysts adherent to surrounding neural and vascular structures, which may thwart attempts at total removal of the cysts without neuro-

logical compromise. As noted with intraventricular experience, preoperative imaging may provide evidence of the local inflammation surrounding parenchymal and cisternal cysts, thus predicting these potential problems in attempting cyst removal (2).

In recent years, image-directed stereotaxis has added a new perspective to the diagnosis and management of intracranial pathology. Newer stereotactic apparatus enables the precise placement of indwelling catheter-reservoirs for repeat aspiration of the cystic contents in the management of intrinsic cystic neoplasms and cysticerebral lesions (1). Realizing that the larval form or scolex has an extended life span (7–10 years) (24), and that there exists a potential for recurrent accumulation of the cyst if it is not totally removed (40), the placement of catheter-reservoirs for large intrinsic cysts is a viable alternative to craniotomy and results in less surgical (especially in deep or eloquent locations) and anesthetic (catheters routinely placed under local anesthesia) morbidity. In contrast to other types of cystic lesions, the cysticerebral walls themselves offer no difficulty in puncture, eliminating the need for the use of sharp probes that may increase the risk of vascular injury. Placement of indwelling catheter-reservoir systems offers a long-term solution to the problem of cyst recurrence; in addition, it provides a margin of safety by surgical decompression during the definitive treatment of the parenchymal disease by praziquantel or albendazole. In this series, the inherent benefit of the stereotactic method in treatment was illustrated by the single patient in whom a large cyst was managed initially by open craniotomy, defied excision, and subsequently recurred. This is in contrast to the patients managed stereotactically, none of whom required further surgical intervention for their parenchymal disease. We have accordingly adopted this technique as the primary surgical procedure in large symptomatic parenchymal cysts refractory to medical therapy.

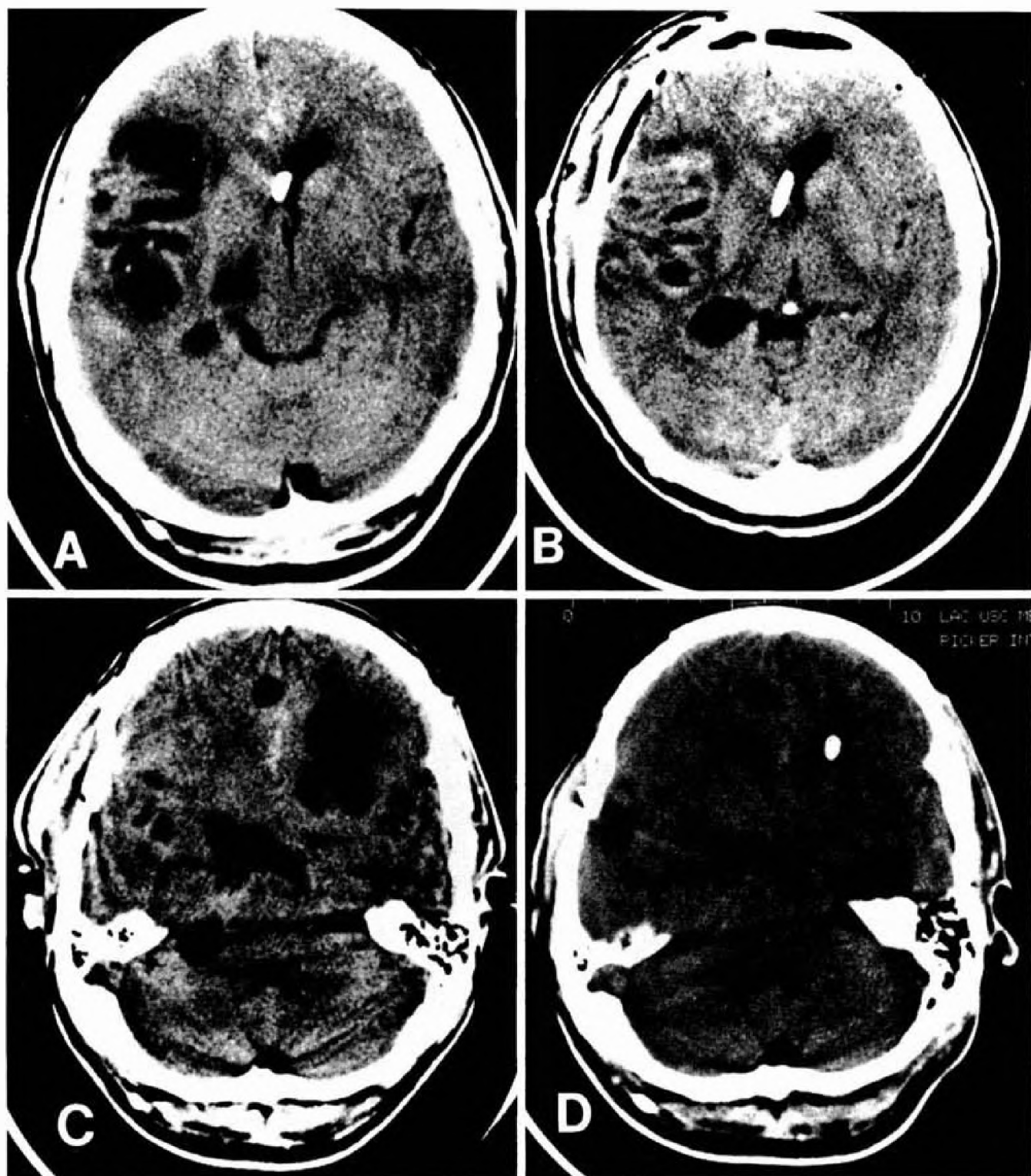


FIG. 2. A 49-year-old man with progressive headache and gait ataxia. The patient had previously undergone ventriculoperitoneal shunting for intraventricular involvement. A CT scan done at admission revealed large right Sylvian cisternal cysts (A). A right frontotemporal craniotomy was performed for removal of multiple cysts (B). Postoperatively, the patient's symptoms resolved, but he was admitted again after 8 weeks with progressive headache. A CT scan at that time demonstrated resolution of the Sylvian lesions but showed a large left frontal parenchymal cyst that had developed in the interim (C). Stereotactic aspiration and placement of a cyst catheter-reservoir was undertaken to decrease the mass effect. A follow-up CT scan 4 months after craniotomy demonstrated no recurrence of frontal or cisternal lesions (D).

Cisternal cysts

When larvae seed the subarachnoid space there is a more ominous prognosis; often, multiple cysts form in grape-like clusters that occupy the basilar cisterns, where they may produce basilar arachnoiditis with subsequent hydrocephalus, cranial neuropathies, and vasculitis (11, 17, 33). These so-called cysticercal racemose cysts may reach large proportions (several centimeters) and cause symptoms by local mass effect. Interestingly, the cysts contain no scolex; whether this represents a successful immunological response by the host is unknown.

The efficacy of praziquantel or albendazole in subarachnoid disease is limited in comparison with parenchymal lesions, but remission has been reported in some cases (9, 18). The 12 patients with cisternal involvement presented here all demonstrated a progressive tumor-like syndrome (in some cases, with neurological deficit) refractory to conservative therapy. Although the management of these large cisternal lesions is controversial, with several authors recommending primary surgical excision of the cysts (25, 30, 42), our experience would indicate that an initial trial of the drug is warranted in a clinically stable patient, recognizing its limitations in this form of infection. Furthermore, there should be no hesitation in proceeding with surgery should symptoms persist or progress.

If surgery is considered, the two viable options are open craniotomy and stereotactic drainage. In direct contrast to the patients harboring parenchymal cysts, all cisternal lesions in this series were removed readily by open craniotomy and drainage. In the 2 patients in which stereotactic aspiration was attempted, inadequate decompression was achieved because of the multiple (racemose) cysts characteristic of these locations. In the absence of radiographic evidence of inflammation (by contrast enhancement on CT scan), these basilar racemose cysts were resected with ease, using gentle irrigation and traction; in all but 4 cases, they were removed intact. Other reports, however, have acknowledged some difficulty using this approach with ring-enhancing cisternal lesions, but marsupialization may be possible (18, 30).

The surgical results of this small series of parenchymal and cisternal lesions compares favorably with those reported by Stepien (39), in which 63 Stage I patients (those with large cysts presenting as space-occupying tumors) were treated by primary craniotomy and attempted cyst removal (before the advent of praziquantel). A total of 74.5% of the patients improved or recovered, but with an associated 23.6% post-operative mortality.

In conclusion, our experience in the management of 20 cases of large symptomatic cisternal and parenchymal cysticercal cysts indicates that such large cysts may be amenable to surgery if they are rapidly progressive or refractory to medical therapy. Symptomatic intraparenchymal cysts are best managed by stereotactic methods with placement of cyst catheter-reservoirs to allow serial aspiration during a treatment course with praziquantel or albendazole. Large basilar cisternal cysts are best managed by open craniotomy and excision in the absence of radiographically discernible basilar arachnoiditis that would preclude their removal.

Received for publication, February 5, 1990; accepted, final form, August 29, 1990.

Reprint requests: Michael L. J. Apuzzo, M.D., 1200 North State Street, Suite 5046, Los Angeles, CA 90033.

REFERENCES

- Apuzzo MLJ, Chandrasoma P, Breeze R, Cohen D, Luxton G, Mazumder A: Applications of image-directed stereotactic surgery in the management of intracranial neoplasms, in Heilbrun MP (ed): *Stereotactic Neurosurgery*. Baltimore, Williams & Wilkins, 1988, pp 73-133.
- Apuzzo MLJ, Dobkin WR, Zee Chi-Shing, Chan JC, Giannotta SL, Weiss MH: Surgical considerations in treatment of intraventricular cysticercosis. *J Neurosurg* 60:400-407, 1984.
- Briceno F, Biagi F, Martinez B: Cysticercosis: Observaciones sobre 97 casos de autopsia. *Prensa Med Mex* 26:193-197, 1961.
- Ciferri F: Praziquantel for cysticercosis of the brain parenchyma. *N Engl J Med* 311:733, 1984 (letter).
- Dandy WE: Cysticercosis cellulosae, in Lewis D (ed): *Practice of Surgery*. Hagerstown, MD, WF Prior, 1932, vol 12, pp 377-382.
- De Ghetaldi LD, Norman RM, Douville AW: Cerebral cysticercosis treated biphatically with dexamethasone and praziquantel. *Ann Intern Med* 99:179-181, 1983.
- De Ghetaldi LD, Norman RM, Douville AW: Praziquantel for cysticercosis of the brain parenchyma. *N Engl J Med* 311:732-733, 1984 (letter).
- Del Brutto OH, Sotelo J: Neurocysticercosis: An update. *Rev Infect Dis* 10:1075-1087, 1988.
- Del Brutto OH, Sotelo J: Albendazole therapy for subarachnoid and ventricular cysticercosis: Case report. *J Neurosurg* 72:816-817, 1990.
- Dixon HB, Lipscomb FM: Cysticercosis: an analysis and follow-up of 450 cases. *Med Res Spec Rep* 299:1-58, 1968.
- Escobar A: The pathology of cysticercosis, in Palacios E, Rodriguez-Carbajal J, Taveras JM (eds): *Cysticercosis of the Central Nervous System*. Springfield, IL, Charles C Thomas, 1983, pp 27-54.
- Estanol B, Corona T, Abad P: A prognostic classification of cerebral cysticercosis: Therapeutic implications. *J Neurol Neurosurg Psychiatry* 49:1131-1134, 1986.
- Faust EC, Russell PF, Jung RC: *Clinical Parasitology*. Philadelphia, Lea and Febiger, 1970, ed 8.
- Gardner B, Goldberg M, Heiner D: The natural history of parenchymal central nervous system cysticercosis. *Neurology* 34 [Suppl 1]:90, 1984 (abstr).
- Grisiola J, Weiderholt W: CNS Cysticercosis. *Arch Neurol* 39:540-544, 1982.
- Hernandez Hernandez G: Cerebral cysticercosis. *Ariz Med* 17:390-393, 1960.
- Latovitski N, Abrams G, Clark C, Mayeux R, Ascherl G, Sciarra D: Cerebral cysticercosis. *Neurology* 28:838-842, 1978.
- Leblanc R, Knowles K, Melanson D, Maclean JD, Rouleau G, Farmer JP: Neurocysticercosis: Surgical and medical management with praziquantel. *Neurosurgery* 18:419-427, 1986.
- Lobato RD, Lamas E, Portillo JM, Roger R, Esparza J, Rivas J, Munoz M: Hydrocephalus in cerebral cysticercosis: Pathogenic and therapeutic considerations. *J Neurosurg* 55:786-793, 1981.
- Lombardo L, Mateos JH: Cerebral cysticercosis in Mexico. *Neurology* 11:824-828, 1961.
- Loo L, Braude A: Cerebral cysticercosis in San Diego. *Medicine* 61:341-359, 1982.
- Loyo M, Kleriga E, Estanol B: Fourth ventricular cysticercosis. *Neurosurgery* 7:456-458, 1980.
- Madrazo I, Garcia-Renteria JA, Sandoval M, Lopez Vega FJ: Intraventricular cysticercosis. *Neurosurgery* 12:148-151, 1983.
- Marques-Montes H: Cysticercosis, in Marcial-Rojas R (ed): *Pathology of Protozoal and Helminthic Disease*. Baltimore, Williams & Wilkins, 1971, pp 162-183.
- Martinez-Lopez M, Quiroz y Ferrari F: Cysticercosis. *J Clin Neuro Ophthalmol* 5:127-143, 1985.
- McCormick GF: Cysticercosis: Review of 230 patients. *Bull Clin Neurosci* 50:76-101, 1985.
- McCormick GF, Zee C, Heiden J: Cysticercosis cerebri: A review of 127 cases. *Arch Neurol* 39:534-539, 1982.
- Nieto D: Cysticercosis of the central nervous system. Diagnosis by means of the spinal fluid complement fixation test. *Neurology* 6:725-738, 1956.
- Obrador S: Cysticercosis cerebri. *Acta Neurochir (Wien)* 10:320-364, 1962.
- Ramina R, Hunhevicz S: Cerebral cysticercosis presenting as a mass lesion. *Surg Neurol* 25:89-93, 1985.
- Robles C, Sedano AM, Vargas-Tentori N, Galindo-Virgen S: Long term results of praziquantel therapy in neurocysticercosis.

- J Neurosurg 66:359-363, 1987.
32. Rosas N, Sotelo J, Nieto D: ELISA in the diagnosis of neurocysticercosis. Arch Neurol 43:353-356, 1986.
 33. Shanley JD, Jordan MC: Clinical aspects of CNS cysticercosis. Arch Intern Med 14:1309-1313, 1980.
 34. Sotelo J, Escobedo F, Rodriguez-Carbajal J, Torres B, Rubio-Donnadieu F: Therapy of parenchymal brain cysticercosis with praziquantel. N Engl J Med 310:1001-1007, 1984.
 35. Sotelo J, Escobedo F, Penagos P: Albendazole vs praziquantel for therapy for neurocysticercosis. Arch Neurol 45:532-534, 1988.
 36. Sotelo J, Guerrero V, Rubio F: Neurocysticercosis: A new classification based on active and inactive forms: A study of 753 cases. Arch Intern Med 145:442-445, 1985.
 37. Sotelo J, Penagos P, Escobedo F, Del Brutto OH: Short course of albendazole therapy for neurocysticercosis. Arch Neurol 45:1130-1133, 1988.
 38. Sotelo J, Torres B, Rubio-Donnadieu F, Escobedo F, Rodriguez-Carbajal J: Praziquantel treatment of neurocysticercosis: Long term follow-up. Neurology 35:752-755, 1985.
 39. Stepien L: Cerebral cysticercosis in Poland: Clinical symptoms and operative results in 132 cases. J Neurosurg 19:505-513, 1962.
 40. Stern WE: Neurosurgical considerations of cysticercosis of the central nervous system. J Neurosurg 55:382-389, 1981.
 41. Tandon PN: Cerebral cysticercosis. Neurosurg Rev 6:119-127, 1983.
 42. Torrealba G, Del Villar S, Tagle P, Arriagada P, Kase CS: Cysticercosis of the central nervous system: Clinical and therapeutic considerations. J Neurol Neurosurg Psychiatry 47:784-790, 1984.
 43. Vázquez JL, Jung H, Sotelo J: Plasma levels of praziquantel decrease when dexamethasone is given simultaneously. J Neurol 37:1561-1562, 1987.

COMMENT

Praziquantel and albendazole have had a major impact on the treatment of parenchymal neural cysticercosis. In this article, the authors have given us a good update on the role of surgical management of this disease in the era of effective medical management. The authors make a logical case for dividing intracranial cysticercosis into parenchymal and cisternal forms, for which primary surgical treatment is difficult. Their experience, although relatively limited, clearly supports their conclusion that parenchymal cysts requiring surgical treatment despite adequate medical therapy seem to be well treated by aspiration. The advice to place a catheter-reservoir system for repeated aspiration is well taken. The efficacy of open excision for cisternal disease is also reasonably well documented. Based on existing knowledge, the authors' advice on management seems appropriate. It will be interesting to see whether this experience is replicated in centers where the disease is more prevalent.

Stephen J. Haines
Minneapolis, Minnesota