

# Transnasal excerebration surgery in ancient Egypt

## Historical vignette

ANDREW A. FANOUS, M.D.,<sup>1</sup> AND WILLIAM T. COULDWELL, M.D., PH.D.<sup>2</sup>

<sup>1</sup>Department of Neurosurgery, University of Vermont, Burlington, Vermont; and <sup>2</sup>Department of Neurosurgery, Clinical Neurosciences Center, University of Utah, Salt Lake City, Utah

Ancient Egyptians were pioneers in many fields, including medicine and surgery. Our modern knowledge of anatomy, pathology, and surgical techniques stems from discoveries and observations made by Egyptian physicians and embalmers. In the realm of neurosurgery, ancient Egyptians were the first to elucidate cerebral and cranial anatomy, the first to describe evidence for the role of the spinal cord in the transmission of information from the brain to the extremities, and the first to invent surgical techniques such as trepanning and stitching. In addition, the transnasal approach to skull base and intracranial structures was first devised by Egyptian embalmers to excerebrate the cranial vault during mummification. In this historical vignette, the authors examine paleoradiological and other evidence from ancient Egyptian skulls and mummies of all periods, from the Old Kingdom to Greco-Roman Egypt, to shed light on the development of transnasal surgery in this ancient civilization. The authors confirm earlier observations concerning the laterality of this technique, suggesting that ancient Egyptian excerebration techniques penetrated the skull base mostly on the left side. They also suggest that the original technique used to access the skull base in ancient Egypt was a transthemoidal one, which later evolved to follow a transsphenoidal route similar to the one used today to gain access to pituitary lesions.

(<http://thejns.org/doi/abs/10.3171/2011.12.JNS11417>)

**KEY WORDS** • transnasal • transsphenoidal • transthemoidal • ancient Egypt • mummification • history of neurosurgery

THE reputation of Egyptian medicine in the ancient world was unmatched by that of any other civilization. Some of the first ruling pharaohs of dynastic Egypt were physicians, including Djer (3100–2890 BC), who wrote one of the earliest medical works, the “Practical Medicine and Anatomic Book.”<sup>7</sup> Other practitioners of medicine at the dawn of Egyptian civilization reached very high positions, such as Imhotep (2655–2600 BC), the father of Egyptian medicine, who served as chancellor to the pharaoh Djoser.<sup>26</sup> The caliber of Egyptian medicine was attested by Homer, who wrote in *The Odyssey*, “... for there [in Egypt] the earth, the giver of grain, bears the greatest store of drugs, many that are healing when mixed, and many that are baneful; there every man is a physician, wise above human kind.”<sup>26</sup> Kings and nobles throughout the ancient world looked to Egypt for medical expertise. Niqmaddu II, King of Ugarit, sent emissaries to the pharaoh Akhenaten (1375–1334 BC) to request an Egyptian physician.<sup>11</sup> Decades later, King Hattusili III of the Hittite Empire wrote to Ramses II (1300–1213 BC) asking for an Egyptian physician to cure his sister’s infertility.<sup>11</sup> Many centuries later, when Cyrus the Great of Persia had an eye injury, he requested an Egyptian ophthalmologist.<sup>28</sup> As Egypt passed into Ptolemaic dominion, all the knowledge of ancient Egypt was passed on to the Greek settlers. One of them, the famous Herophilus (335–280 BC), who studied at the medical school of Alexandria under the mentorship of Egyptian physicians,

discovered 7 of the cranial nerves, and gave his name to what we know today as the “torcular Herophili.”<sup>22</sup>

The ancient Egyptians were also the first to conceive of specialized medicine. In the 5th century BC, Herodotus wrote about the concept of specialized medicine in ancient Egypt, saying, “Medicine is practiced among [the Egyptians] on a plan of separation: each physician treats a single disease, and not more: thus the country abounds with physicians, some undertaking to cure the diseases of the eyes, others of the head, others again of the teeth, others of the intestine.”<sup>2</sup> Inevitably, one of these specializations was neurosurgery.

## Neurosurgery in Ancient Egypt

Depictions of neurosurgery in ancient Egypt represent the oldest evidence of neurosurgery in the African continent, and proof of brain surgery can be found in Egyptian papyrus writings. In fact, the first known mention of the word “brain” dates back to an Egyptian papyrus from the 17th century BC, whose original authorship is sometimes attributed to Imhotep.<sup>24</sup> This papyrus, part of the Edwin Smith collection of 48 trauma surgery cases in ancient Egypt, refers to the “ais ‘ndjennet,” literally, the

This article contains some figures that are displayed in color online but in black and white in the print edition.

“viscera of the skull.”<sup>22</sup> It also contains the first known description of cranial sutures, meninges, the falx cerebri, superficial cerebral anatomy, cerebrospinal fluid, and intracranial pulsations.<sup>22,31</sup> In addition, this remarkable papyrus includes the first description of the role of the spinal cord in transmission of information from the brain to the extremities, as it recounts a case of cervical spine injury associated with quadriplegia, priapism, incontinence, and paralytic ileus.<sup>22</sup> Furthermore, symptoms of different cases, including Bell palsy, coup-contracoup mechanism of injury, and hemiplegia secondary to a compound comminuted cranial fracture, are all accurately described in the papyrus.<sup>8,22,28</sup> Finally, the papyrus contains the first accounts of surgical stitching and various types of dressings used in surgical procedures.<sup>31</sup>

Ancient Egyptians were the pioneers in many neurosurgical techniques.<sup>8</sup> Egyptian skulls from the 12th and 18th dynasties, for instance, still bear witness to trepanning—the process of drilling a bur hole into the cranium—for which hammers, chisels, and a convex scraper with a wide radius were used.<sup>10,22,28</sup> In this historical vignette, we discuss another neurosurgical technique used by the ancient Egyptians, namely the transnasal removal of intracranial contents during mummification.

### Transnasal Excerebration in Ancient Egypt

#### *Mummification*

The tradition of mummification began in Egypt during the late 4th millennium BC.<sup>15,32</sup> Very early in their dynastic history, the ancient Egyptians realized that removal of internal organs could help prevent postmortem putrefaction;<sup>19</sup> however, preservation of the living appearance and facial features of the deceased was paramount for the “ba,” the Egyptian soul, to recognize the body and reunite with it in the afterlife.<sup>32</sup> Thus, wary of any damage to the visible features of the deceased body, ancient Egyptians performed postmortem transnasal surgery for removal of encephalic remnants without aesthetic alteration of the skull or face.<sup>29</sup> Evidence for the care taken to preserve the skull and face was recently demonstrated by a radiological study of 9 Egyptian mummies, which revealed intact calvariae and facial bones in at least 8 of the 9.<sup>14</sup> The Egyptians believed that the heart was the most important organ, the source of human wisdom, memory, love, and emotions. The heart was indeed the only organ left in place after death.<sup>19</sup> Little importance, however, was attributed to the brain, which was believed to be unnecessary for life. In fact, the only function of the brain was thought to be the passage of mucus into the nose, and it was discarded during mummification.<sup>12</sup> Such little importance was given to the brain that, at the zenith of the mummification art during the 21st dynasty (1085–945 BC), the lungs, liver, stomach, and intestines were desiccated in solid natron salt and carefully returned to the body cavity, while the brain was still discarded.<sup>19</sup> Molten resin eventually filled the intracranial vacuum left by the removal of the brain.

#### *Excerebration*

Excerebration, or brain removal, can be traced back

in Egyptian history to the Old Kingdom (3rd–6th dynasty, 2686–2181 BC), with evidence of skull base perforations in mummies from the 4th dynasty (2613–2498 BC) (Fig. 1).<sup>13,25,32</sup> Even in mummies of that period that lacked skull base defects, some authors have hypothesized that excerebration was performed through the foramen magnum.<sup>13</sup> Mummies from the Middle Kingdom (11th–12th dynasty, 2080–1773 BC) only show occasional evidence of skull base defects.<sup>32</sup> It was not until the dawn of the New Kingdom (18th–20th dynasty, 1550–1070 BC) that postmortem transnasal excerebration of Egyptian mummies became common practice.<sup>27</sup> It continued throughout later periods and well into Greco-Roman Egypt (332 BC to 641 AD).

Unfortunately, no primary written accounts have survived to describe the methodology of mummification. The first written document about this procedure was composed by Herodotus, who visited Egypt during the reign of the 27th dynasty (525–404 BC).<sup>12,20,22,32</sup> According to Herodotus in his book “Histories,” brain extraction was performed via an approach strikingly similar to that used in modern-day transsphenoidal surgery. The Egyptian embalmers would perforate the bone at the superior aspect of the nose with a chisel and subsequently insert a curved metal hook into the nasal cavity to break some cranial bones.<sup>6,15,17,25,32</sup> The hook inevitably created an artificial skull base defect in the cranial fossae that seldom exceeded 2 cm in diameter.<sup>22,25</sup> Cerebral components were subsequently removed with the hook or liquefied with a swirling motion of the hook and then poured out through the nose with the head tipped forward.<sup>3,12</sup> This allowed for easy evacuation of cerebral components of the anterior and middle cranial fossae. Posterior fossa elements were next extracted via an occipital defect or an enlargement of the foramen magnum.<sup>13,21</sup> In the 20th century, anthropologists experimentally demonstrated the possibility of excerebration using various ancient Egyptian spiral-ended or hook-shaped metal rods found in European museums.<sup>18,25,30</sup>

#### *Paleoradiological Evidence of Transnasal Excerebration*

Modern imaging techniques have proven invaluable for the study of skull defects in ancient Egyptian mummies. Plain radiographs have been taken of mummified Egyptian remains since the late 19th century,<sup>9,15</sup> but the field of paleoradiology was revolutionized with the advent of CT scanning. The first historical CT study was performed in 1976 at The Hospital for Sick Children in Toronto on the brain of a female mummy named Nakht from the 22nd dynasty (945–720 BC).<sup>5</sup> Subsequent scans of several Egyptian mummies initially demonstrated that transnasal excerebration was most commonly performed via a transthemoidal route (Fig. 2).<sup>12,15</sup> Unlike the modern-day transsphenoidal approach, which attempts to gain access to components of the sella turcica, the traditional Egyptian transthemoidal approach penetrated the skull base anterior to the sella, involving or immediately posterior to the cribriform plate. The earliest Egyptian skulls to exhibit such transthemoidal defects came from the Old Kingdom’s 4th dynasty and were first described by Léon Nicolaëff<sup>21</sup> in 1930.<sup>25</sup> The oldest known Egypt-

# Transnasal excerebration surgery in ancient Egypt




Fig. 1. Timeline illustrating the history of excerebration of mummies in ancient Egypt. Intern. = Intermediate.

tian mummy to have evidence of transnasal excerebration on CT scans was that of Djehutynekht, who dates back to the Middle Kingdom's 11th dynasty (2080–1991 BC) (Fig. 3).<sup>13</sup> This particular mummy exhibited complete removal of the ethmoid air cells. The skull base defect of the anterior cranial fossa extended anteriorly to involve the middle portion of the cribriform plate just posterior to the crista galli, while the sphenoid bone remained intact. Other mummies that date back to the Middle Kingdom exhibited similar features. For instance, CT scanning of the two Middle Kingdom mummies ROM I and ROM II studied by Yardley and Rutka<sup>32</sup> demonstrated destruction of the cribriform plates and ethmoidal labyrinths. The 3D reconstructed CT scans obtained in later mummies from the New Kingdom showed similar results. Two mummies from the 19th dynasty (1292–1186 BC) studied by Hoffman and Hudgins<sup>14</sup> showed evidence of destruction of the ethmoid air cells, as well as destruction of the ethmoid sinus roof at the level of the cribriform plate (Fig. 4). Moreover, endoscopic studies performed by Pirsig and Parsche<sup>25</sup> in 88 mummified skulls from the New Kingdom revealed destruction of the middle turbinate and adjacent ethmoidal cells, along with intact sphenoid sinuses in most of these specimens. In most of the skulls, the posterior part of the crista galli and cribriform plate had been removed. Only 5 of these skulls had destruction of the sphenoid sinuses. Consistent with these findings were observations made in the early 20th century by Oettekling,<sup>23</sup> who noted the presence of ethmoidal perforations in over 50% of 182 mummy skulls dating from the New Kingdom's 18th dynasty (1549–1292 BC).<sup>25</sup>

Although use of the transethmoidal route for excerebration was apparently common in the earlier dynasties, studies performed in mummies from the Third Intermediate and Late Periods seem to suggest access to the cerebrum that followed a more posterior route, leading to

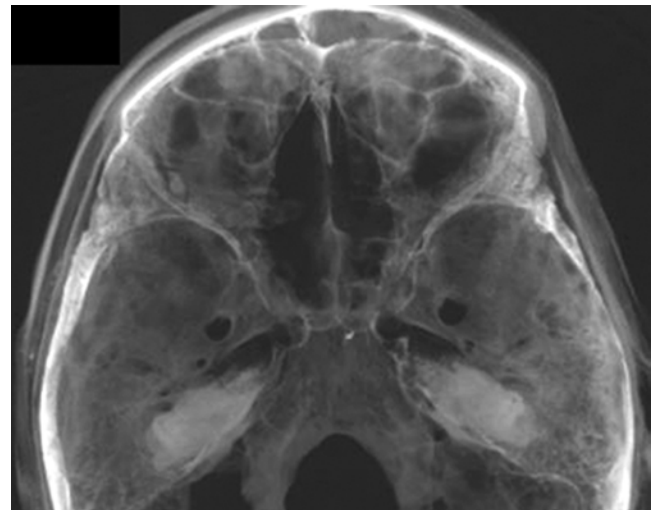
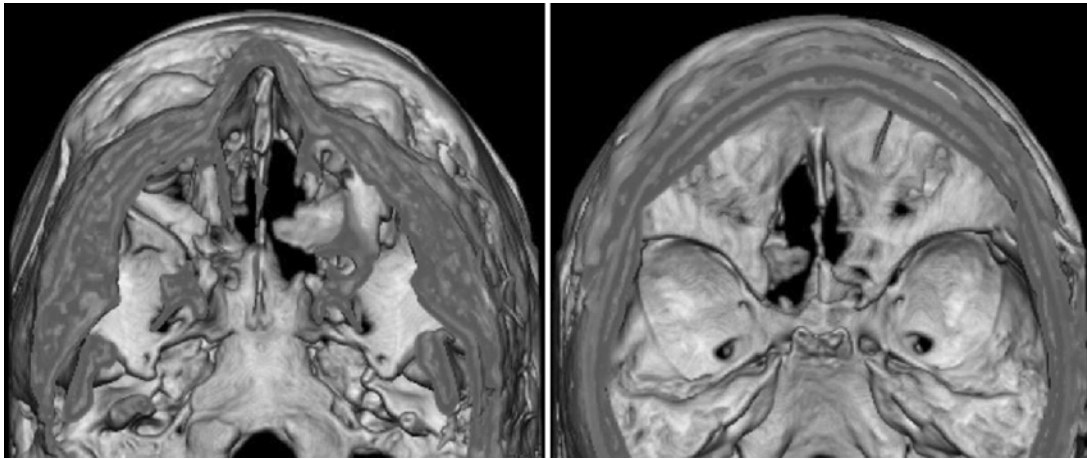


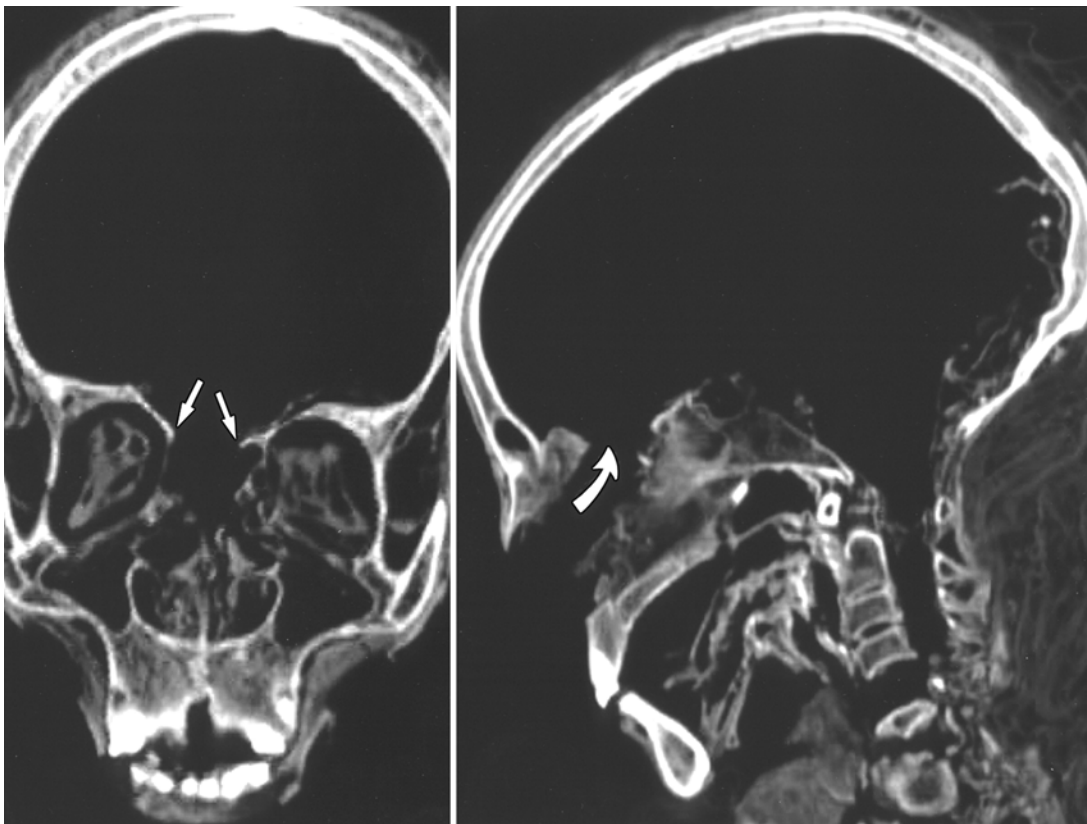
Fig. 2. A slightly transparent view from the top of the cranial vault showing anterior and middle cranial fossae. The defect in the cribriform plate is apparent, and through it, the contents of the nasal cavity can be partially visualized. Reproduced with permission from Gupta R, Markowitz Y, Berman L, Chapman P: High-resolution imaging of an ancient Egyptian mummified head: new insights into the mummification process. *AJNR Am J Neuroradiol* 29:705–713, 2008.



**Fig. 3.** Surface-rendered scans, inferior view looking up (**left**) and superior view looking down (**right**), showing the defect in the cribriform plate that establishes a communication between the nasal cavity and the intracranial space. Reproduced with permission from Gupta R, Markowitz Y, Berman L, Chapman P: High-resolution imaging of an ancient Egyptian mummified head: new insights into the mummification process. *AJNR Am J Neuroradiol* 29:705–713, 2008.

a widespread belief in the medical literature that the ancient Egyptians gained access to the brain transsphenoidally.<sup>8,19</sup> For instance, in 1 of the 9 mummies studied by Hoffman and Hudgins<sup>14</sup> that dates back to the 25th or 26th dynasty (732–525 BC), the cerebral contents seem to have been removed via a predominantly transsphenoidal

approach rather than a transthemoidal one. In this mummy, a fragment of the sphenoid bone could be identified in the posterior aspect of the skull. A different study performed on another mummy from the Third Intermediate Period showed evidence of excerebration via a combined transthemoidal-transsphenoidal approach.<sup>20</sup> In that mum-



**Fig. 4.** Coronal reformatted (**left**) and sagittal (**right**) CT scans of the skull obtained in a 21st dynasty mummy. Demonstrated is a defect in the roof of the ethmoid sinuses (*arrows*, left) of the anterior skull base that was created for excerebration via the transnasal route, shown with the *arrow* at right. Reproduced with permission from Hoffman H, Torres WE, Ernst RD: Paleoradiology: advanced CT in the evaluation of nine Egyptian mummies. *Radiographics* 22:377–385, 2002.

## Transnasal excerebration surgery in ancient Egypt

my, known as the “Lady Hudson” mummy, CT scans revealed indiscriminate defects in the skull base, extending from the crista galli into the sella turcica. A similarly combined transethmoidal-transsphenoidal approach may have been employed well into the Ptolemaic era, as suggested by a Ptolemaic-era skull studied by Isherwood et al.<sup>16,22</sup> In that skull, while the predominantly observed defect is one of the ethmoid bone at the region of the cribriform plate, a broken and detached part of the sella turcica was found in the posterior aspect of the skull. Insertion of a catheter penetrated the skull base at the region of the sella turcica.<sup>22</sup> This may very well be the first evidence of transsphenoidal pituitary gland extraction during the process of excerebration—removed at the time because it hindered access to the cerebrum. Taken together, these observations may indicate that the initial transnasal technique used by the Egyptians was a transethmoidal one, which migrated slowly and posteriorly through the millennia, finally to reach a transsphenoidal or a combined transethmoidal-transsphenoidal path by the time of the Third Intermediate Period. Thus, while embalmers from the Middle and New Kingdoms penetrated the skull base through a more anterior approach just posterior to the crista galli, later embalmers from the Third Intermediate and Late Periods performed excerebration through a more posterior point between the cribriform plate and the sella turcica, sometimes even perforating the latter.

### *Laterality of Transnasal Excerebration*

Another interesting aspect of the Egyptian transnasal surgical approach is the laterality of the skull base perforation. Yardley and Rutka’s study<sup>32</sup> of two Middle Kingdom mummies revealed bilateral destruction of cribriform plates and ethmoidal labyrinths. Later mummies from the 22nd to 26th dynasties demonstrated a predominantly left-sided approach, albeit with a few exceptions.<sup>14,19</sup> For instance, in 49 of the 88 New Kingdom skulls studied by Pirsig and Parsche,<sup>25</sup> skull base perforation occurred on the left side, whereas only 12 were right sided. The two 19th dynasty mummies studied by Hoffman and Hudgins<sup>14</sup> were exceptional in their demonstration of right-sided skull base perforation, which occurred through the right ethmoid sinuses. Subsequent skulls dating from the Ptolemaic era (305–30 BC) also exhibited evidence of excerebration through a left-sided approach.<sup>22</sup> Thus, it appears that the transnasal excerebration performed by the ancient Egyptians, whether transethmoidal or transsphenoidal, was predominantly undertaken through the left nasal septum and through a defect in the left skull base.

In their attempt to explain this predominantly left-sided laterality, Pirsig and Parsche<sup>25</sup> suggested that right-handed embalmers worked while standing by the right side of the deceased, making it easier for them to approach the intracranial contents through the left nasal cavity. However, with our knowledge of the Egyptian mummification process, wherein the deceased body was eviscerated through an incision in the left abdomen, and with the natural anatomical location of the heart in the left chest cavity, the possibility of a more religious aspect to our observation is not unlikely. Unfortunately, many of

the published paleoradiological studies of ancient Egyptian mummies failed to report the side of the skull base defect, making it difficult to draw conclusions based on the small number of studies that do.

### *Decline of the Art of Mummification*

The art of Egyptian mummification declined considerably under Roman occupation (30 BC–641 AD).<sup>19</sup> Mummies from that era no longer exhibited the sophistication of transnasal excerebration. For instance, the mummy of one young girl from Roman Egypt showed evidence of excerebration via large fractures made in the calvaria.<sup>19</sup> Certain mummies from this era show no evidence of excerebration.<sup>19</sup> With the advent of Christianity and the decline of the native Egyptian religion, the need for mummification ceased, and with it ended the necessity and practice of transnasal excerebration.

The use of the transnasal approach to access intracranial components was lost altogether until it was revived 2 millennia later, toward the end of the 19th century, thanks to the anatomical studies of Davide Giordano, chief surgeon at the Hospital of Venice in Italy.<sup>14</sup> It did not take long for the technique to be applied to living humans, and the first transsphenoidal surgery for removal of a pituitary adenoma was performed in 1907 by Hermann Schloffer, professor of surgery at the University of Innsbruck in Austria.<sup>4,17</sup>

## Conclusions

Ancient Egyptians were the pioneers of accessing the calvarial components via the transnasal route, which reached its climax in the 21st dynasty (1085–945 BC), but slowly declined thereafter. We believe that it is likely that the technical motives for performing this process were widespread and deliberate, particularly because of the long period over which the technique was used and the apparently gradual rather than haphazard modification of the technique. A review of the paleoradiological studies suggests that, with a few exceptions, excerebration techniques were carried out by penetrating the skull base on the left side. The technique of transnasal excerebration during mummification was thought to have been performed via a transsphenoidal approach; however, increasing evidence obtained from mummified skulls now suggests that the ancient Egyptians may have extracted the brain transethmoidally, suggesting that the original technique was indeed a transethmoidal one, but later evolved, around the time of the 25th and 26th dynasties, to follow a transsphenoidal route similar to the one used today to gain access to pituitary lesions. Whether this shift truly represents an evolution in the technique of mummification requires additional studies involving a larger number of specimens. Moreover, whether variations in geographical location within Egypt, as well as disparities in socioeconomic status, could have affected the approach to excerebration remains to be investigated.

## Disclosure

The authors report no conflict of interest concerning the materials or methods used in this study or the findings specified in this paper.

Author contributions to the study and manuscript preparation include the following. Conception and design: both authors. Acquisition of data: Fanous. Analysis and interpretation of data: Couldwell. Drafting the article: Fanous. Critically revising the article: both authors. Reviewed submitted version of manuscript: both authors. Approved the final version of the manuscript on behalf of all authors: Couldwell. Study supervision: Couldwell.

#### Acknowledgments

The authors would like to thank Dr. Salima Ikram, Professor of Egyptology and Archeology at the American University in Cairo, as well as Dr. Lisa Sabbahy, Associate Professor of Egyptology and Archeology at the American University in Cairo, for their tremendous assistance with reviewing and verifying the historical component of this article. The authors also thank Dr. Heidi Hoffman for her review and thoughtful comments. They acknowledge Kristin Kraus, M.Sc., for her excellent editorial assistance in preparing the article.

#### References

- Artico M, Pastore FS, Fraioli B, Giuffrè R: The contribution of Davide Giordano (1864-1954) to pituitary surgery: the translabellar-nasal approach. **Neurosurgery** **42**:909-912, 1998
- Atkinson AB: From then to now: lessons from developments in our understanding of the pituitary gland. **Ulster Med J** **79**: 89-94, 2010
- Brier B, Wade RS: Surgical procedures during ancient Egyptian mummification. **Z Egypt Sprache Alt** **126**:89-97, 1999
- Cappabianca P, de Divitiis E: Back to the Egyptians: neurosurgery via the nose. A five-thousand year history and the recent contribution of the endoscope. **Neurosurg Rev** **30**:1-7, 2007
- Chhem RK, Brothwell DR: **Paleoradiology: Imaging Mummies and Fossils**. New York: Springer, 2008
- Dunand F, Lichtenberg R: **Mummies: A Voyage Through Eternity**. Sharman R, transl. New York: Abrams, 1994
- Ebeid NI: **Egyptian Medicine in the Days of the Pharaohs**. Cairo: General Egyptian Book Organization, 1999
- El Gindi S: Neurosurgery in Egypt: past, present, and future-from pyramids to radiosurgery. **Neurosurgery** **51**:789-796, 2002
- Flinders Petrie WM, Griffith JH: **Deshasheh, 1897: Fifteenth Memoir of the Egypt Exploration Fund**. London: Egypt Exploration Fund, 1898
- Ghalioungui P: **The House of Life: Per Ankh. Magic and Medical Science in Ancient Egypt**. Amsterdam: BM Israel Boekhandel, 1973
- Ghalioungui P: **The Physicians of Pharaonic Egypt**. Cairo: Al-Ahram Center for Scientific Translations, 1983
- Grosvenor AE, Laws ER: The evolution of extracranial approaches to the pituitary and anterior skull base. **Pituitary** **11**:337-345, 2008
- Gupta R, Markowitz Y, Berman L, Chapman P: High-resolution imaging of an ancient Egyptian mummified head: new insights into the mummification process. **AJNR Am J Neuroradiol** **29**:705-713, 2008
- Hoffman H, Hudgins PA: Head and skull base features of nine Egyptian mummies: evaluation with high-resolution CT and reformation techniques. **AJR Am J Roentgenol** **178**:1367-1376, 2002
- Hoffman H, Torres WE, Ernst RD: Paleoradiology: advanced CT in the evaluation of nine Egyptian mummies. **Radiographics** **22**:377-385, 2002
- Isherwood I, Jarvis H, Fawcitt RA: Radiology of the Manchester mummies, in David AR (ed): **The Manchester Museum Mummy Project**. Manchester: Manchester University Press, 1979, pp 25-64
- Joshi SM, Cudlip S: Transsphenoidal surgery. **Pituitary** **11**: 353-360, 2008
- Leek FF: The problem of brain removal during embalming by the ancient Egyptians. **J Egypt Archaeol** **55**:112-116, 1969
- Marx M, D'Auria SH: CT examination of eleven Egyptian mummies. **Radiographics** **6**:321-330, 1986
- Nelson AJ, Conlogue G, Beckett R, Posh J, Chhem R, Wright E, et al: Multimodal analyses of variability in transnasal craniotomy lesions in Egyptian mummies, in **Paleopathology Association: Scientific Program & Abstracts 34th Annual Meeting (North America)**. Philadelphia, March 27-28, 2007, p 24 (Abstract)
- Nicolaëff L: Quelques données au sujet des méthodes d'excébration par les Égyptiens anciens. **Anthropologie** **40**: 77-92, 1930
- Nunn JF: **Ancient Egyptian Medicine**. London: British Museum Press, 1997
- Oetteking B: **Kraniologische studien an Altägyptern**. Braunschweig: F. Vieweg und Sohn, 1908
- Peltier L: **Fractures: A History and Iconography of Their Treatment**. San Francisco: Norman Publishing, 1990
- Pirsig W, Parsche F: Instruments for transnasal brain removal during embalming by the ancient Egyptians. **Int J Anthropol** **6**:67-74, 1991
- Pioreschi P: **A History of Medicine, ed 2**. Omaha: Horatius Press, Vol 1, 1995
- Raven MJ, Taconis WK: **Egyptian Mummies: Radiological Atlas of the Collections in the National Museum of Antiquities at Leiden**. Turnhout, Belgium: Brepols, 2005
- Selin H, Shapiro H: **Medicine Across Cultures: History and Practice of Medicine in Non-Western Cultures**. Dordrecht: Kluwer Academic Publishers, 2003
- Sindou M: **Practical Handbook of Neurosurgery: From Leading Neurosurgeons**. Vienna: Springer, Vol 3, 2009
- Sudhoff K: Aegyptische Mumienmacher-Instrumente. **Arch Gesch Med** **5**:161-171, 1911
- Wilkins RH: Neurosurgical Classic. XVII. **J Neurosurg** **21**: 240-244, 1964
- Yardley M, Rutka J: Rescued from the sands of time: interesting otologic and rhinologic findings in two ancient Egyptian mummies from the Royal Ontario Museum. **J Otolaryngol** **26**:379-383, 1997

Manuscript submitted March 10, 2011.

Accepted December 1, 2011.

Please include this information when citing this paper: published online January 6, 2012; DOI: 10.3171/2011.12.JNS11417.

Address correspondence to: William T. Couldwell, M.D., Ph.D., Department of Neurosurgery, Clinical Neurosciences Center, University of Utah, 175 North Medical Drive East, Salt Lake City, Utah 84132. email: neuropub@hsc.utah.edu.