

The natural history of cerebral cavernous malformations

DOUGLAS KONDZIOLKA, M.D., M.Sc., F.R.C.S.(C), L. DADE LUNSFORD, M.D.,
AND JOHN R. W. KESTLE, M.D., M.Sc., F.R.C.S.(C)

Department of Neurological Surgery, Presbyterian University Hospital, University of Pittsburgh, Pittsburgh, Pennsylvania; and Division of Neurosurgery, Research Consulting Unit, British Columbia's Children's Hospital, University of British Columbia, Vancouver, British Columbia, Canada

✓ To determine the natural history of brain cavernous malformations, the authors entered patients referred to their center into a prospective registry between 1987 and 1993. All patients underwent magnetic resonance imaging, which showed the typical appearance of this lesion, and conservative management was recommended in all. Patients or their referring physicians were contacted for follow-up data. The purpose of the study was to define the rate of symptomatic hemorrhage and to determine the outcome in those patients who had suffered seizures.

Follow-up data were available for 122 patients with a mean age at entry of 37 years (range 4-82 years). The malformation was located in the brainstem in 43 cases (35%), the basal ganglia/thalamus in 20 (17%), and a hemispheric area in 59 (48%). Fifty percent of patients had never had a symptomatic hemorrhage, 41% had one bleed, 7% had two, and 2% had three. Seizures were reported in 23% of patients and headaches in 15%. Lesions were solitary in 80% of patients and multiple in 20%. The retrospective annual hemorrhage rate (61 bleeds/4550.6 patient-years of life) was 1.3%.

The mean prospective follow-up period was 34 months. There were nine bleeds during this time, six with new neurological deficits. In patients without a prior bleed, the prospective annual rate of hemorrhage was 0.6%. In contrast, patients with prior hemorrhage had an annual bleed rate of 4.5% ($p = 0.028$). Patient sex ($p = 0.97$) or the presence of seizures ($p = 0.11$), headaches ($p = 0.06$), or solitary versus multiple lesions ($p = 0.15$) were not significant predictors of later hemorrhage. There was no difference in the rate of bleeds between brain locations. Four patients with seizures became seizure-free and four patients without seizures later developed seizures; only one patient developed intractable seizures. Fourteen patients (11%) underwent surgery (two after hemorrhage, five with seizures, and seven with progressive deficits), and five had radiosurgery. No patient died in the follow-up period. This study indicates that conservative versus operative management strategies may need to be redefined, especially in patients who present with hemorrhage and who appear to have a significantly increased risk of subsequent rehemorrhage.

KEY WORDS • cavernous malformation • angioma • hemorrhage • vascular malformation • seizure

CAVERNOUS malformations (cavernous angiomas and angiographically occult vascular malformations) are congenital vascular anomalies of the brain. Their recognition as incidental or symptomatic vascular malformations has been facilitated by magnetic resonance (MR) imaging.⁸ Along with arteriovenous malformations (AVMs), cavernous malformations constitute vascular malformations that are often symptomatic and require management by neurosurgeons or neurologists. They can be located in any brain region, be of varying size, and present with different clinical disorders. Histopathologically, they are characterized by dilated thin-walled vascular channels lined by a simple endothelium and thin fibrous adventitia; typically, no brain parenchyma is found within the lesion.

Management strategies for cavernous malformations remain complex. This report defines the natural history of these lesions to improve our base of knowledge upon which future management decisions are made. Robinson,

et al.,¹⁰ calculated the annual bleed rate in 57 patients as 0.7%, and Curling, *et al.*,¹ found an annual rate of 0.25% in their group of 32 patients. Zabramski, *et al.*,¹³ calculated an incidence of symptomatic hemorrhage of 1.1% per lesion per year in 31 patients with familial cavernous malformations. These hemorrhage rates are generally lower than those reported for AVMs.⁶

After the development of our stereotactic radiosurgery program in 1987, we evaluated an increasing number of patients with cavernous malformations. We entered all patients selected for conservative management into a registry designed to assess the prospective natural history of the disorder. Our goal was to obtain valuable information regarding the outcome of cavernous malformations and their collective rates of symptomatic hemorrhage, seizure development, and subsequent need for treatment. We planned to correlate preregistry clinical criteria with the observed prospective outcome.

Natural history of cavernous malformations

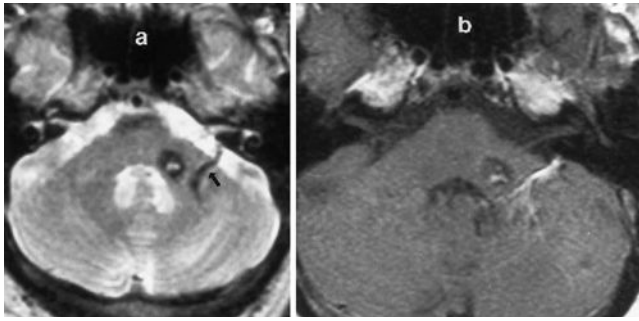


FIG. 1. Magnetic resonance images in a 38-year-old man with a cavernous malformation medial to a venous malformation within the left middle cerebellar peduncle. a: Long-TR image showing the mixed-signal cavernous malformation and a flow-void area within the transparenchymal draining vein (*arrow*) of the venous malformation. b: Short-TR image with contrast enhancement showing the radial collection of venous channels within the venous malformation.

Clinical Material and Methods

From 1987 through 1993, the records and imaging studies of 235 patients with cavernous malformations were reviewed at our multidisciplinary vascular malformation conference at the University of Pittsburgh, attended by neurosurgeons, neuroradiologists, and radiation oncologists. Conservative management was recommended for 162 patients, all of whom were entered immediately into a prospective natural history registry. We recommended conservative treatment if: 1) the patient had an asymptomatic lesion; 2) the malformation was associated with a medically controlled seizure disorder; 3) the malformation was located in a critical brain region but the patient had only one hemorrhage or minimal symptoms; 4) the patient was elderly or medically infirm; or 5) the patient had multiple cavernous malformations and the actual symptomatic lesion could not be determined. In the registry we recorded patient age, sex, number of prior hemorrhages, the presence or absence of seizures or headache, brain location, type of diagnostic imaging performed, date, and the name and address of the referring physician.

The diagnosis of cavernous malformation was based on high-resolution MR imaging, supplemented in many cases by computerized tomography. All patients had the typical MR imaging appearance of a cavernous malformation (mixed internal signal, surrounded by a margin of low signal thought to represent hemosiderin).^{7,8} In all patients who had angiograms (73 cases), no vascular abnormality was identified in the area of the lesion. All patients with prior symptomatic hemorrhage had confirmation of gross bleeding on imaging studies. Two patients had coexisting venous angiomas (Fig. 1). No patient who underwent angiography had an associated AVM or aneurysm.

In June 1994, follow-up questionnaires were mailed to all referring physicians. Patients without recent follow-up data were contacted by telephone. We obtained information on 122 patients (75%); 40 patients were lost to follow-up review and could not be contacted by us or their referring physicians. The following information was obtained: development of new symptoms; dates of symptomatic hemorrhage; development of seizures or control

of existing seizures; and whether microsurgery or radiosurgery was performed (in which case patients were censored at the time of treatment). The results of imaging studies performed at follow-up examinations were not assessed by us. The occurrence of hemorrhage was documented on imaging studies evaluated by the referring physicians.

The series was divided into retrospective and prospective (after the date of entry into the registry) information groups. Retrospectively, the hemorrhage rate per patient-year of observation was calculated assuming that the lesion was present from birth to the time of entry into the registry.¹ Hemorrhage rates were compared using a chi-square test. A logistic regression analysis was also performed. Baseline factors collected at the time of entry into the registry were used as independent variables (history of prior hemorrhage, seizures, headache, gender, number of lesions, and location). The dependent variable (outcome) was the presence (or absence) of symptomatic hemorrhage in the follow-up period. A forward stepwise selection of variables was performed using the likelihood ratio test. The data were analyzed by an independent bioepidemiologist (J.R.K.). Significance was defined as $p < 0.05$.

Results

Patient Characteristics

The study population of 122 patients consisted of 60 males and 62 females. Mean patient age was 37.3 years (range 4–82 years). Sixty-one patients (50%) had never sustained a clinically detectable hemorrhage. Fifty patients (41%) had one prior hemorrhage, nine (7%) had two hemorrhages, and two (2%) had three hemorrhages. Seizures were reported in 28 patients (23%) and headaches in 18 (15%). Solitary cavernous malformations were found in 97 patients (80%), whereas lesions were multiple in 25 patients (20%). We did not count the number of cavernous malformations in each patient with multiple lesions to try to calculate a “rate per lesion”; rather, we sought to determine the rate per patient in this multiple subgroup. Because the number of detectable cavernous malformations in some patients can increase over time (especially in familial cases), imaging studies alone are unlikely to determine the true number of malformations present.^{3,13}

Brainstem cavernous malformations were present in 43 patients (35%), 27 of whom had suffered a prior brainstem hemorrhage. Twenty patients (17%) had malformations in the basal ganglia or thalamus, and 59 patients (48%) had a cerebral or cerebellar hemispheric malformation. We combined cerebral and cerebellar hemisphere locations into one group because of their greater suitability for surgical resection in comparison to brainstem or diencephalic lesions.

Retrospective Hemorrhage Rate

Prior to entry into the natural history registry, this cohort of 122 patients had sustained 61 hemorrhages in 4550.6 patient-years of life. This equaled a hemorrhage

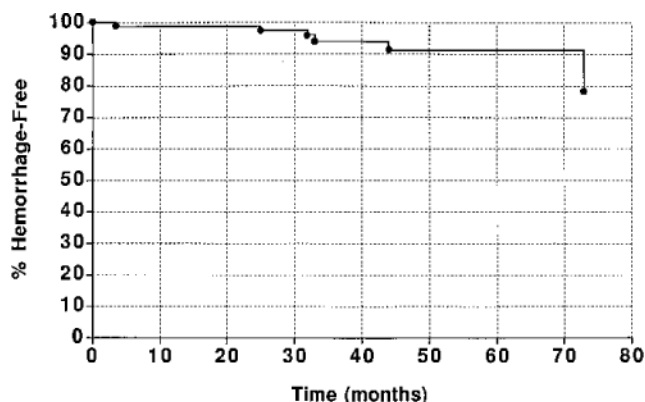


FIG. 2. Kaplan-Meier curve showing the percentage of patients without a symptomatic hemorrhage versus time (prospective assessment).

rate of 1.3% per year (under the assumption that the lesion had been present since birth).

Prospective Risk of Hemorrhage and Seizures

During the mean prospective follow-up interval of 34 months (range 1–82 months), nine hemorrhages occurred. Seven patients had one hemorrhage and one patient had two hemorrhages. Thus, nine hemorrhages in 341.6 prospective years of observation equaled a 2.63% annual hemorrhage rate in the overall patient group (Fig. 2). We found no difference in the hemorrhage rate between men and women (four in males, five in females, $p = 0.97$), between patients with or without seizures ($p = 0.11$), between patients with or without headaches ($p = 0.06$), or between patients with solitary versus multiple lesions ($p = 0.15$). In fact, no patient with multiple lesions had a hemorrhage in the follow-up period.

The most important risk factor for subsequent hemorrhage was the occurrence of a prior hemorrhage (Table 1). Of the 61 patients who had never had a symptomatic hemorrhage, only one sustained a hemorrhage in the follow-up period. This equaled a 0.6% annual hemorrhage rate in this group. In the 61 patients who sustained a hemorrhage before entry into the registry, eight hemorrhages in seven patients were found in the follow-up period, for an annual hemorrhage rate of 4.5% ($p = 0.028$). In the logistic regression model, the most important determinant of bleeding in the follow-up period was a history of prior hemorrhage. Report of headaches was also a significant predictor; however, the importance of such a report by the patient remains unclear, because headache was not specified as to type.

Brain location did not correlate with subsequent hemorrhage risk. Of the 43 patients with brainstem malformations, three sustained a hemorrhage in the follow-up period (prospective annual hemorrhage rate of 2.4%, Table 1). Two of 20 patients with basal ganglia/thalamic malformations had a later hemorrhage (annual rate of 2.9%). Two of 59 patients with hemispheric malformations sustained one hemorrhage and one suffered two hemorrhages (annual rate of 2.7%). In this patient group, with a brainstem location and a prior hemorrhage, we found a subsequent annual hemorrhage rate of 5.0%.

TABLE 1

Annual hemorrhage rates for cavernous malformations

Clinical Factors	Prospective Annual Hemorrhage Rate
no prior hemorrhage	0.6%
prior hemorrhage	4.5%
brainstem location	2.4%
basal ganglia/thalamus location	2.9%
hemisphere location	2.7%
brainstem location with prior hemorrhage	5.0%

Four (4.3%) of 94 patients without seizures developed seizures in the follow-up period and four (14%) of 28 patients with seizures became seizure-free. Only one patient developed intractable seizures.

Surgical Management

Fourteen patients (11%) had microsurgery in the follow-up interval. Two underwent resection of their malformation after sustaining a new hemorrhage, and five had surgery for a persistent seizure disorder. Seven underwent surgery because they suffered progressive neurological deterioration, perhaps due to repeated microhemorrhage within the cavernous malformation. No patient suffered additional major morbidity after resection. Five additional patients with recurrent hemorrhage had stereotactic radiosurgery during the follow-up period, all for management of recurrent hemorrhage. Four patients were treated with the gamma knife,⁴ and one had proton beam irradiation. No patient died in the follow-up period.

Discussion

The diversity of clinical presentations associated with cerebral cavernous malformations is well reported.^{1,5,7,9–14} The widespread availability of MR imaging led to the subsequent increased diagnosis of this vascular entity. Many reports have emphasized the importance of surgical resection in the management of patients with hemorrhage, poorly controlled seizures, or progressive neurological deficits.^{5,10,14} Most authors conclude that the challenge of cavernous malformation microsurgery is both finding the lesion and minimizing trauma to adjacent brain tissue, especially in areas of critical brain function. The actual removal of the malformation usually proceeds uneventfully. Before the value of surgical removal can be assessed, the natural history of an unoperated cavernous malformation must be known.

Value of MR Imaging for Diagnosis

All of the patients in the current series had MR images that showed the typical appearance of a cavernous malformation, agreed upon by neurosurgeons and neuroradiologists at our vascular malformation conference. Because neurosurgeons and neurologists will make management decisions based on an imaging appearance and not the histological appearance, we believe our reliance on imaging appearance alone for entry into this study was appropriate.

Many authors have stressed the differential diagnosis of this imaging-defined lesion, which includes thrombosed

Natural history of cavernous malformations

or patent AVMs,² venous malformations, mixed-type vascular malformations, and tumors in addition to cavernous malformations or angiomas.⁸ The hallmark is that they are angiographically occult. However, the great majority of lesions are pathologically confirmed to be cavernous malformations, as identified on histological preparations after surgery.^{5,12,14} Thus, we believe that the term "cavernous malformation" is useful and appropriate for these lesions, when high-quality MR imaging has been performed. Although we initially performed conventional angiography in all such patients to rule out an AVM or venous malformation, we have stopped using angiography when the MR appearance is typical.

Natural History

In 1991, Robinson, *et al.*,¹⁰ and Curling, *et al.*,¹ presented analyses of the natural history of cavernous malformations. In the series by Robinson, *et al.*, over 14,000 consecutive MR images performed at the Cleveland Clinic between 1984 and 1989 were reviewed. They identified 66 patients who had the typical MR appearance of a cavernous malformation and followed these for a mean 26 months. Most patients presented with a seizure; 16% were asymptomatic. Only one patient sustained a hemorrhage during the follow-up period, for an annual bleeding rate of 0.7%. The small number of patients and the short follow-up precluded an analysis of stratification variables for hemorrhage risk. Their study suggested that male and female patients had a different hemorrhage risk, but this was not confirmed in our study. The Cleveland Clinic report emphasized the role of MR imaging in diagnosis and provided a natural history profile indicating a low risk for overt hemorrhage.

Curling, *et al.*,¹ reported 32 patients who had 76 cavernous malformations; these patients were discovered in a review of 8131 MR images performed between 1986 and 1989. In their retrospective analysis, performed from the time of birth up to the time of MR imaging diagnosis, they calculated a symptomatic hemorrhage risk of 0.25% per year. Surgical resection was performed and pathology confirmed in seven of the 32 patients. They concluded that, because the risk of significant hemorrhage from a cavernous malformation was relatively low, hemorrhage prevention should not be an absolute indication for surgical resection. They also acknowledged that the risk of rebleeding after an initial hemorrhage was unknown.¹

Tung, *et al.*,¹² reported 13 patients with recurrent hemorrhages from cavernous malformations located in all brain regions. The median interval from first to second hemorrhage was 12 months. They noted that all surgical specimens showed histological evidence of chronic and recent hemorrhage. In many patients multiple microscopic hemorrhages occur, but are often not clinically detected.^{8,9,13} Only symptomatic hemorrhages were used to guide management. They recommended surgical removal for hemorrhagic malformations discovered in surgically accessible, noncritical brain locations.¹² Lesions found in critical locations were removed only if recurrent hemorrhage had occurred. Simard, *et al.*,¹¹ found a course of repeated hemorrhages in patients with brainstem cavernous malformations.

Zabramski, *et al.*,¹³ followed 31 patients with 128 familial cavernous malformations for a mean period of

2.2 years. The incidence of symptomatic hemorrhage was 1.1% per lesion per year. Six (29%) of 21 patients developed "new" lesions on serial MR images, at a rate of 0.4 new lesions per patient per year.¹³ The observation of increasing numbers of malformations in family members over multiple generations was also noted by Horowitz and Kondziolka.³ Zabramski, *et al.*, also reported the increased risk of rehemorrhage after an initial hemorrhage.

Prior natural history studies have been based on an analysis of consecutive MR images.^{1,10} In our series, patients were identified after referral to a tertiary care center with microsurgical and radiosurgical expertise. Our series may be affected by selection bias since our patients tended to have more complex clinical presentations or had presented difficulties in decision-making regarding therapeutic options. This may have resulted in a higher number of patients who had sustained prior hemorrhage in our study, or a larger proportion of patients with lesions that were symptomatic or in critical locations. However, because of the number of patients in this study, we still had 61 patients who never bled who constituted a large group with less complex presentations. In prospective analysis, we stratified patients into different groups based on their initial presentation. Our finding of a 0.6% annual hemorrhage rate in patients without prior hemorrhage is similar to the risk identified by Robinson, *et al.*,¹⁰ (0.7%) but slightly higher than that reported by Curling, *et al.*,¹ (0.25%). This finding is important because it provides evidence of the low risk for hemorrhage in patients with incidental malformations and in those patients who present with seizures only.

We and others¹² suspect that patients who present with a hemorrhage have an increased risk of subsequent hemorrhage. Our finding of an increased annual hemorrhage risk of 4.5% in this group supports this hypothesis. This risk is similar to that reported in the study of Ondra, *et al.*,⁶ in regard to the natural history for hemorrhage in symptomatic AVMs. Six of the nine subsequent hemorrhages in our series were associated with new neurological deficits, although none led to death. Our experience suggests the concept that rehemorrhage from a cavernous malformation may lead to increased deficits but rarely results in patient mortality.

Significant differences in the hemorrhage rates were not found when patients were grouped according to history of prior seizures, headaches, sex, lesion location, or number of malformations. The occurrence of prior hemorrhage defined a subgroup of patients with an increased risk of subsequent hemorrhage. Perhaps surgical removal should be considered for those patients who present with one hemorrhage, regardless of where the malformation is located. The role of stereotactic radiosurgery in the management of hemorrhagic, intraparenchymal, critically located malformations is currently being defined.⁴

Acknowledgments

The authors thank all referring physicians and patients who participated in this study and the dedicated staff of the Center for Image-Guided Neurosurgery, University of Pittsburgh.

References

1. Curling OD Jr, Kelly DL Jr, Elster AD, et al: An analysis of

- the natural history of cavernous angiomas. **J Neurosurg** **75**:702–708, 1991
2. Ebeling JD, Tranmer BI, Davis KA, et al: Thrombosed arteriovenous malformations: a type of occult vascular malformation. Magnetic resonance imaging and histopathological correlations. **Neurosurgery** **23**:605–610, 1988
 3. Horowitz M, Kondziolka D: Multiple familial cavernous malformations evaluated over three generations with magnetic resonance imaging. **AJNR** **16**:1353–1355, 1995
 4. Kondziolka D, Lunsford LD, Coffey RJ, et al: Stereotactic radiosurgery of angiographically occult vascular malformations: indications and preliminary experience. **Neurosurgery** **27**:892–900, 1990
 5. Lobato RD, Rivas JJ, Gomez PA, et al: Comparison of the clinical presentation of symptomatic arteriovenous malformations (angiographically visualized) and occult vascular malformations. **Neurosurgery** **31**:391–397, 1992
 6. Ondra SL, Troupp H, George ED, et al: The natural history of symptomatic arteriovenous malformations of the brain: a 24-year follow-up assessment. **J Neurosurg** **73**:387–391, 1990
 7. Preul MC, Villemur JG, LeBlanc R, et al: MR imaging diagnosis of brainstem cavernous angiomas presenting as tumours. **Can J Neurol Sci** **19**:376–382, 1992
 8. Rigamonti D, Drayer BP, Johnson PC, et al: The MRI appearance of cavernous malformations (angiomas). **J Neurosurg** **67**:518–524, 1987
 9. Rigamonti D, Hadley MN, Drayer BP, et al: Cerebral cavernous malformations. Incidence and familial occurrence. **N Engl J Med** **319**:343–347, 1988
 10. Robinson JR, Awad IA, Little JR: Natural history of the cavernous angioma. **J Neurosurg** **75**:709–714, 1991
 11. Simard JM, Garcia-Bengochea F, Ballinger WE Jr, et al: Cavernous angioma: a review of 126 collected and 12 new clinical cases. **Neurosurgery** **18**:162–172, 1986
 12. Tung H, Giannotta SL, Chandrasoma PT, et al: Recurrent intraparenchymal hemorrhages from angiographically occult vascular malformations. **J Neurosurg** **73**:174–180, 1990
 13. Zabramski JM, Wascher TM, Spetzler RF, et al: The natural history of familial cavernous malformations: results of an ongoing study. **J Neurosurg** **80**:422–432, 1994
 14. Zimmerman RS, Spetzler RF, Lee KS, et al: Cavernous malformations of the brain stem. **J Neurosurg** **75**:32–39, 1991

Manuscript received September 28, 1994.

Accepted in final form April 3, 1995.

Dr. Kondziolka is supported by National Institutes of Health Grant 1 K08 NS01723-01 from the National Institutes of Neurological Disorders and Stroke.

Address for Dr. Kestle: British Columbia's Children's Hospital, University of British Columbia, Vancouver, British Columbia, Canada.

Address reprint requests to: Douglas Kondziolka, M.D., Suite B-400, Presbyterian University Hospital, University of Pittsburgh Medical Center, 200 Lothrop Street, Pittsburgh, Pennsylvania 15213–2582.