

Optic Neuritis

Craig H. Smith

IDIOPATHIC AND PRIMARY DEMYELINATING OPTIC NEURITIS

Acute Idiopathic Demyelinating Optic Neuritis
 Chronic Demyelinating Optic Neuritis
 Asymptomatic (Subclinical) Demyelinating Optic Neuritis
 Neuromyelitis Optica (Devic's Disease)
 Optic Neuritis in Myelinoclastic Diffuse Sclerosis (Encephalitis Periaxialis Diffusa, Schilder's Disease)
 Encephalitis Periaxialis Concentrica (Concentric Sclerosis of Baló)

CAUSES OF OPTIC NEURITIS OTHER THAN PRIMARY DEMYELINATION

Optic Neuritis from Viral and Bacterial Diseases

Optic Neuritis After Vaccination

Optic Neuritis in Sarcoidosis

Syphilis

Optic Neuritis in HIV-Positive Patients and Patients with Aids

Optic Neuritis in Systemic Lupus Erythematosus and Other Vasculitides

Lyme Disease

Sinus Disease

Miscellaneous Causes of Optic Neuritis

BILATERAL OPTIC NEURITIS

OPTIC NEURITIS IN CHILDREN

NEURORETINITIS

OPTIC PERINEURITIS (PERIOPTIC NEURITIS)

Optic neuritis is a term used to refer to inflammation of the optic nerve. When it is associated with a swollen optic disc, it is called papillitis or anterior optic neuritis. When the optic disc appears normal, the term *retrobulbar optic neuritis* or *retrobulbar neuritis* is used. In the absence of signs of multiple sclerosis (MS) or other systemic disease, the optic neuritis is referred to as monosymptomatic or idiopathic, or as a clinically isolated syndrome. The pathogenesis of isolated optic neuritis is presumed to be demyelination of the optic nerve, similar to that seen in MS. It is likely that most cases of isolated acute optic neuritis are a *forme fruste* of MS. Optic neuritis, as a harbinger of a more diffuse demyelinating process, merits careful attention to an exact diagnosis and a thorough consideration of treatment paradigms.

Optic neuritis does not always present as acute loss of vision. It may develop as insidious progressive or nonprogressive visual dysfunction, and it may even be asymptomatic. Patients with asymptomatic optic neuritis have electrophysiologic evidence of optic nerve dysfunction and may also have subtle clinical evidence of optic nerve damage if appropriate clinical studies are performed.

Optic neuritis can be caused by disorders other than MS and related demyelinating diseases. In addition, two unusual variants of optic neuritis can occur. *Neuroretinitis* is a term used to describe inflammatory involvement of both the intra-

ocular optic nerve and the peripapillary retina. In addition to optic disc swelling, eyes with neuroretinitis show extensive retinal edema, vitreal inflammatory changes, hemorrhages, and hard exudates (lipid) in the macula in a star-shaped pattern. *Optic perineuritis*, also called perioptic neuritis, describes inflammatory involvement of the optic nerve sheath without inflammation of the nerve itself. Patients with this condition have optic disc swelling that may be unassociated with any visual complaints. In such cases, visual acuity is normal in the affected eye, and there is no visual field defect except for an enlarged blind spot. The disc swelling thus may be difficult to differentiate from papilledema, particularly when it is bilateral, without performing neuroimaging studies and lumbar puncture (discussed later).

Most of this chapter deals with acute demyelinating optic neuritis, occurring in isolation, in association with MS, or in association with other demyelinating diseases. The later sections of the chapter discuss other forms of demyelinating optic neuritis, optic neuritis caused by processes other than MS and related disorders, and the variants of optic neuritis: neuroretinitis and perioptic neuritis. Our knowledge of the immunopathogenesis and clinical aspects of optic neuritis has taken huge steps with the information provided by the Optic Neuritis Treatment Trial (ONTT) and ancillary development of the genetic and neuroimmunologic basis of MS.

IDIOPATHIC AND PRIMARY DEMYELINATING OPTIC NEURITIS

Despite remarkable advances in neuroimaging and electrophysiologic testing, the diagnosis of optic neuritis remains basically a clinical one. Nettleship (1) first described a syndrome characterized by "failure of sight limited to one eye, often accompanied by neuralgic pain about the temple and orbit and by pain in moving the eye; many recover but permanent damage and even total blindness may ensue; there is at first little, sometimes no, ophthalmoscopic change, but the disc often becomes more or less atrophic in a few weeks." Nettleship (1) also emphasized the tendency for the orbital pain to antedate the loss of vision and for the maximum visual field defect to be central in nature. Subsequently, Parinaud (2), Uhthoff (3), Buzzard (4), and Gunn (5) described similar patients.

Optic neuritis usually is a primary demyelinating process. It almost always occurs as an isolated phenomenon or in patients who either have, or will develop, MS. Patients in whom optic neuritis occurs as an isolated phenomenon have a higher risk of developing MS at some later date than the normal population. Optic neuritis is also part of the demyelinating syndrome called "neuromyelitis optica" or "Devic's disease," and it occasionally occurs in two other primary demyelinating diseases: myelinoclastic diffuse sclerosis (encephalitis periaxialis diffusa, Schilder's disease) and encephalitis periaxialis concentrica (concentric sclerosis of Baló). There are three forms of primary demyelinating optic neuritis: acute, chronic, and subclinical.

ACUTE IDIOPATHIC DEMYELINATING OPTIC NEURITIS

Acute demyelinating optic neuritis is by far the most common type of optic neuritis throughout the world. It is also the type that is best known and understood. Although the clinical syndrome of acute optic neuritis has been well recognized for many years, much information about optic neuritis was obtained from the ONTT (6–26), a multicenter controlled clinical trial funded by the National Eye Institute of the National Institutes of Health in the United States. This trial was the first in the field of MS research to look rigorously at a treatment outcome as well as to define metrics of outcome. The ONTT enrolled 455 patients with acute unilateral optic neuritis. Although the primary objective of the trial was to assess the efficacy of corticosteroids in the treatment of optic neuritis, the trial also provided invaluable information about the clinical profile of optic neuritis, its natural history, and its relationship to MS.

Entry criteria in the ONTT included a clinical syndrome consistent with unilateral optic neuritis (including a relative afferent pupillary defect and a visual field defect in the affected eye), visual symptoms of 8 days or less, no previous episodes of optic neuritis in the affected eye, no previous corticosteroid treatment for optic neuritis or MS, and no evidence of a systemic disease other than MS as a cause for the optic neuritis. Patients were randomly assigned to one of three treatment groups: (a) oral prednisone (1 mg/kg/d) for 14 days; (b) intravenous methylprednisolone sodium succinate (250 mg QID for 3 days) followed by oral prednisone

(1 mg/kg/d) for 11 days; or (c) oral placebo for 14 days. Each regimen was followed by a short oral taper.

Measurement of visual function was made at study entry, at seven follow-up visits during the first 6 months, yearly for 4 years, then at 5 and 10 years (as the Longitudinal Optic Neuritis Study [LONS]). Data collected at the 6-month follow-up visit served as the primary measure of visual outcome. Both the rate of visual recovery and long-term visual outcome were assessed by four measures:

1. Snellen acuity with a retroilluminated Bailey-Lovie chart at 4 meters
2. Color vision with the Farnsworth-Munsell 100-hue test
3. Contrast sensitivity with the Pelli-Robson chart
4. Perimetry with the Humphrey Field Analyzer (program 30-2) and Goldmann perimeter

A standardized detailed neurologic examination was performed at study entry, after 6 months, after 1 year, yearly for 4 years, and then at 5 and 10 years (in the LONS). Additional examinations were performed when patients developed new neurologic symptoms during the first 5 years, and brain magnetic resonance imaging (MRI) was obtained on all patients at 10 years who had initially had a normal brain MRI. Clinically definite multiple sclerosis (CDMS) was diagnosed when a patient developed new neurologic symptoms attributable to demyelination in one or more regions of the central nervous system (CNS), other than new optic neuritis in either eye, occurring at least 4 weeks after the optic neuritis at study entry and lasting more than 24 hours, with abnormalities documented on neurologic examination.

Demographics

Much of the following information on demographics, long-term risk of MS development, and visual outcome in optic neuritis comes from the ONTT/LONS. The annual incidence of acute optic neuritis has been estimated in population-based studies to be 1–5 per 100,000 (27–33). In Olmstead County, Minnesota, where the Mayo Clinic is located and where extensive and accurate studies of the incidence of various diseases have been performed, the incidence rate is estimated to be 5.1 per 100,000 person-years and the prevalence rate 115 per 100,000 (33).

Most patients with acute optic neuritis are between the ages of 20 and 50 years, with a mean age of 30–35 years. Females are affected more commonly than males. In the ONTT, 77% of the patients were female, 85% were Caucasian, and the mean age was 32 ± 7 years. Nevertheless, optic neuritis can occur at any age. It is well described in children in the first and second decades of life (34–38), and it can occur in adults in the sixth and seventh decades (39).

Symptoms

The two major symptoms in patients with acute optic neuritis are loss of central vision and pain in and around the affected eye. Other symptoms are much less common.

Loss of Central Vision

Loss of central visual acuity is the major symptom in most cases of acute optic neuritis, being reported by over 90% of patients (7). Loss of vision is usually abrupt, occurring over several hours to several days. Progression for a longer period of time can occur but should make the clinician suspicious of an alternative disorder. The degree of visual loss varies widely. In some cases visual acuity is minimally reduced; in others there is complete blindness with no perception of light. Most patients describe diffuse blurred vision, although some state that blurring is predominantly central. The visual loss is monocular in most cases, but in a few patients, particularly in children, both eyes are simultaneously affected.

Loss of Visual Field

Not all patients with acute optic neuritis complain of loss of central vision. Some complain of loss of peripheral vision, usually in a particular area of the visual field, such as the inferior or superior region, often to one side. Such patients may deny loss of central acuity and may be found to have 20/20 or better vision in the affected eye (40).

Ocular or Orbital Pain

Pain in or around the eye is present in more than 90% of patients with acute optic neuritis. It is usually mild, but it may be extremely severe and may even be more debilitating to the patient than the loss of vision. It may precede or occur concurrently with visual loss; usually is exacerbated by eye movement; and generally lasts no more than a few days (7,39,41–44). In the ONTT, pain was reported by 92% of patients, of whom 87% indicated that it was worsened by eye movement. Rose (45) theorized that the pain is caused by inflammation or swelling in the optic nerve sheaths that are innervated by small branches of the trigeminal nerve; however, Swartz et al. (46) hypothesized that the pain is initiated by inflammation of the optic nerve in the apex of the orbit, where the extraocular muscles are firmly attached to the sheaths of the nerve. In support of this hypothesis, Lepore (47) reported that among 101 eyes with optic neuritis, pain was more commonly present with retrobulbar neuritis than with papillitis; however, in the ONTT, pain was present in 93% of the 295 eyes with retrobulbar neuritis and in 90% of the 162 eyes with papillitis. The presence of pain is a helpful feature to differentiate it from nonarteritic anterior ischemic optic neuropathy (AION), particularly when it is severe and when it occurs or worsens during movement of the eyes. Swartz et al. (46) reported that the incidence of pain in patients with AION was only 12%, compared with a frequency of pain of 92% in the patients enrolled in the ONTT. Gerling et al. (48) reported a similar figure and also found that pain tended to be described as much more severe by patients with optic neuritis compared with patients with AION, and that patients with AION rarely experienced pain on movement of the eyes.

Positive Visual Phenomena

Patients with optic neuritis may experience positive visual phenomena, called photopsias, in addition to pain and visual

blurring, both at the onset of their visual symptoms and during the course of the disorder. These phenomena are spontaneous flashing black squares, flashes of light, or showers of sparks (39,49,50). These visual phenomena may be precipitated by eye movement (44,50) or certain sounds (51,52). Positive visual phenomena were reported by 30% of the patients in the ONTT.

Signs

Examination of a patient with acute optic neuritis reveals evidence of optic nerve dysfunction. Visual acuity is reduced in most cases. Contrast sensitivity and color vision are impaired in almost all cases. The reduction in contrast sensitivity often parallels the reduction in visual acuity (53), although in some cases it is much worse (7). The reduction in color vision is often much worse than would be expected from the level of visual acuity (54,55). Visual field loss can vary from mild to severe. A relative afferent pupillary defect is present and detectable with a swinging flashlight test in almost all unilateral cases. When such a defect is not present, either there is a coexisting optic neuropathy in the fellow eye or the visual loss in the affected eye is not caused by optic neuritis or any other form of optic neuropathy. Patients with optic neuritis also can be shown to have a reduced sensation of brightness in the affected eye simply by asking them to compare the brightness of a light shined in one eye and then another or by performing more complex testing with a flickering light, the frequency of which can be varied between 50 and 0 Hz (56–58).

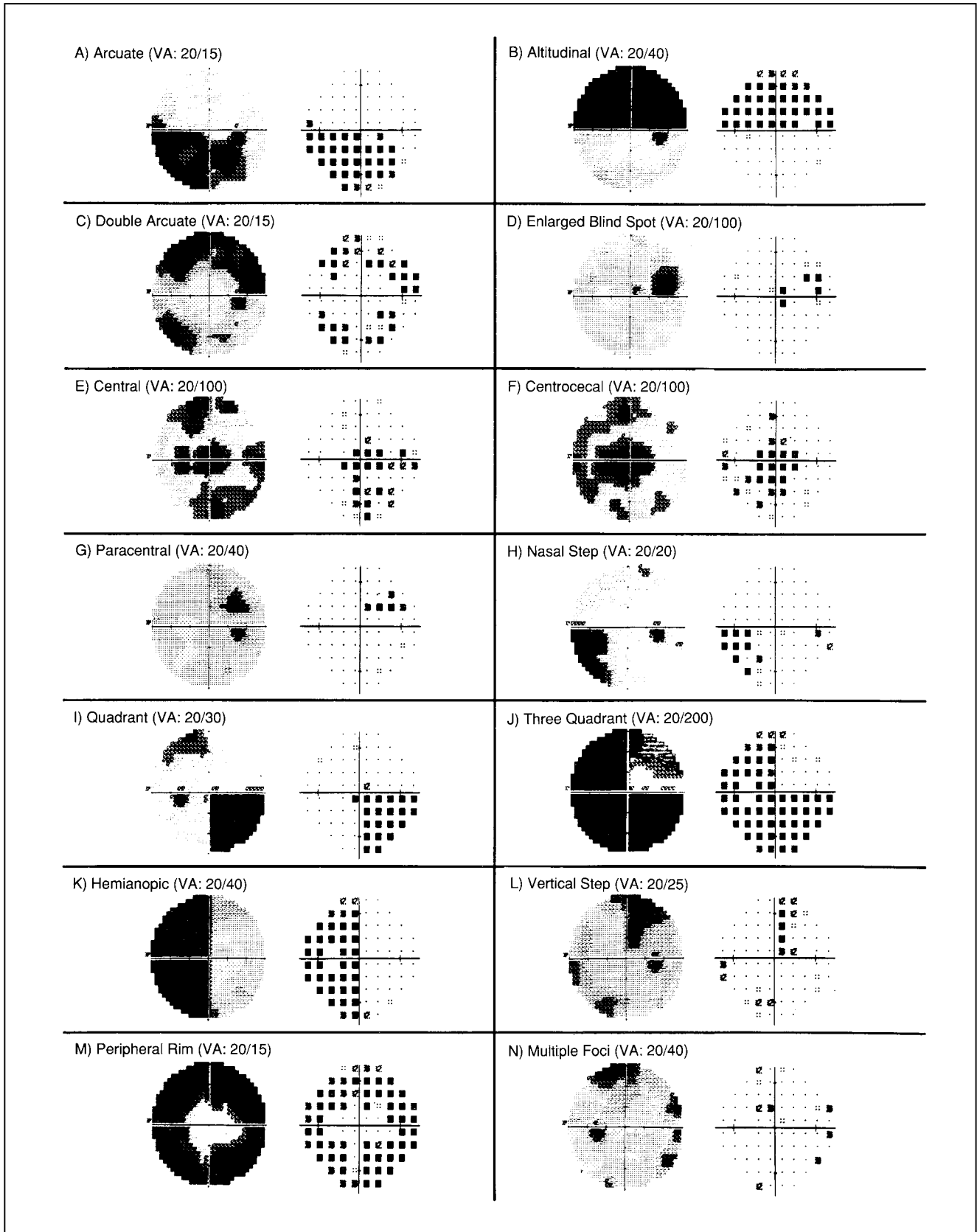
Slit-lamp biomicroscopy in eyes with demyelinating optic neuritis is almost always normal. There may be a few cells in the vitreous overlying the optic disc, but there is rarely any significant cellular reaction. In eyes with anterior optic neuritis (papillitis) from causes other than demyelination, such as sarcoidosis, tuberculosis, syphilis, or Lyme disease, a significant vitritis may be present (discussed later). The optic disc in optic neuritis may appear normal (retrobulbar neuritis) or swollen (papillitis), and if the patient has experienced a previous clinical or subclinical attack of optic neuritis in the eye, the disc may appear pale. Both the swelling and the pallor are nonspecific findings in optic neuritis, and neither is useful in distinguishing demyelinating optic neuritis from the optic neuritis that may accompany other inflammatory or infectious diseases.

Visual Acuity

The severity of visual acuity loss varies from a mild reduction to no light perception. In the ONTT, baseline visual acuity was $\geq 20/20$ in 11%, 20/25 to 20/40 in 25%, 20/50 to 20/190 in 29%, 20/200 to 20/800 in 20%, finger counting in 4%, hand motion in 6%, light perception in 3%, and no light perception in 3% (7).

Color Vision

Color vision is almost always abnormal in patients with optic neuritis and is usually more severely affected than visual acuity itself. Thus, testing of color vision may be particu-



larly helpful in diagnosing optic neuritis in patients with minor visual loss.

Ishihara pseudoisochromatic color plates can detect color vision defects in eyes with retrobulbar optic neuritis and normal-appearing optic discs and can detect evidence of optic nerve dysfunction in the eyes of patients with MS in whom retrobulbar neuritis is suspected. Another type of color plates, the Hardy-Rand-Rittler (HRR) pseudoisochromatic plates, was first printed in 1954 and was used by Steinmetz and Kearns (59) at the Mayo Clinic to detect acquired color vision defects in patients with presumed retrobulbar optic neuritis. Rosen (60) published the results of a study of 272 patients with MS tested with HRR plates and found that 100% of eyes with ophthalmoscopic evidence of definite optic disc pallor ($n = 24$) and 46% of eyes with possible pallor ($n = 39$) had abnormal color vision when tested with these plates. Based on these findings, he emphasized the usefulness of HRR plates in the early diagnosis of demyelinating optic neuritis and in the diagnosis of MS itself. Some patients with optic neuritis can see none or only some of the figures with the affected eye but all of the figures with the fellow eye. Other patients may see all of the figures correctly with each eye; however, when the patient is asked to look at a single plate, first with one eye and then with the other, he or she will note a striking difference in color and brightness between the two eyes. Although patients may have congenitally defective color vision, the pattern of color defects found in patients with congenital color blindness is much different from that of acquired color defects from optic neuropathy (60).

A more sensitive test of color vision, the Farnsworth-Munsell 100-Hue test, has been recommended for detection of various optic neuropathies, including optic neuritis (61–63). In the ONTT, Ishihara color plates were abnormal in the affected eye in 88%, whereas the Farnsworth-Munsell 100-Hue test was abnormal in 94% (7).

Visual Field

Griffith (64) and Gunn (65) considered the central field to be always affected in patients with optic neuritis, and both Berliner (66) and Carroll (67) recorded typical central and paracentral defects in their patients, although Carroll (67) recorded a few cases with an associated peripheral constriction or with extensions of a central defect to the periphery. Central or paracentral scotomas, with and without peripheral extension, represented over 90% of field defects in the cases reported by Marshall (68), and Hyllested and Moller (69) found such defects in 98.5% of their cases. Thus, the typical visual field defect in optic neuritis has always been thought to be a central scotoma (70). It has subsequently become

clear, however, that virtually any type of field defect can occur in an eye with optic neuritis, including an arcuate defect, a cecocentral scotoma, a superior or inferior altitudinal defect, and a temporal or nasal hemianopic defect. Among 100 patients with optic neuritis, Chamlin (71) found 44 patients with arcuate defects and 4 patients with peripheral defects. Perkin and Rose (39) found only 31% of their patients to have pure central defects alone. Vighetto et al. (72) reported similar results. Patients with optic neuritis may also simply have diffuse loss of sensitivity throughout the visual field. Among 415 patients in the ONTT with baseline visual acuity of hand motions or better, the predominant pattern of visual field loss was found to be focal in 52% and diffuse in 48% (73). Focal nerve fiber bundle type defects (altitudinal, arcuate, and nasal step) were present more frequently (20%) than pure central or cecocentral defects (8%). Other types of defects were present in 24% of patients, including hemianopic defects in 5% (73) (Fig. 6.1).

Pupillary Reaction

Despite reports to the contrary (74), a relative afferent pupillary defect is almost always present in patients with acute optic neuritis, whether anterior or retrobulbar (75–78). The only exception to this rule is the patient who has suffered a previous attack of optic neuritis in the fellow eye or who has subclinical (asymptomatic) optic neuritis in the fellow eye (discussed later). In such a case, damage to the optic nerve in the fellow eye may offset the damage from acute optic neuritis in the affected eye (even when there is asymmetry of visual function by clinical testing), and there will be no evidence of a relative afferent pupillary defect. In cases of apparent acute optic neuritis in which no relative afferent pupillary defect is detected by a swinging flashlight test, the use of neutral density filters may uncover such a defect (see Chapter 15).

Ophthalmoscopic Appearance

In most series, about 20–40% of patients with acute optic neuritis have some degree of disc swelling (3,39,68,69,74, 79–83). In the ONTT, optic disc swelling was observed in 35% of the patients (7). The optic disc may be slightly or markedly blurred (Fig. 6.2). At times, the disc swelling is so severe that it mimics the “choked disc” seen in patients with papilledema (Fig. 6.3). The degree of disc swelling does not correlate with the severity of either visual acuity or visual field loss (39). Disc or peripapillary hemorrhages are uncommon in eyes with acute optic neuritis, as opposed to AION, in which they more frequently accompany disc swelling. In the ONTT, disc or peripapillary hemorrhages were present in 6% of patients (7).

Figure 6.1. Visual field defects in acute optic neuritis. Fourteen types of localized monocular visual field defects that may occur in acute optic neuritis, as defined by static perimetry as performed with a Humphrey automated perimeter using a 30-2 program incorporating the full-threshold test strategy, a 31.5-apositlb background, and size III targets for the test and blind spot checks. The foveal threshold and fluctuation tests were turned on. Central, cecocentral, arcuate, altitudinal, quadrantic, and even hemianopic defects may develop. VA, visual acuity. (From Keltner JL, Johnson CA, Spurr JO, et al. Baseline visual field profile of optic neuritis. The experience of the optic neuritis treatment trial. *Optic Neuritis Study Group. Arch Ophthalmol* 1993;111:231–234.)

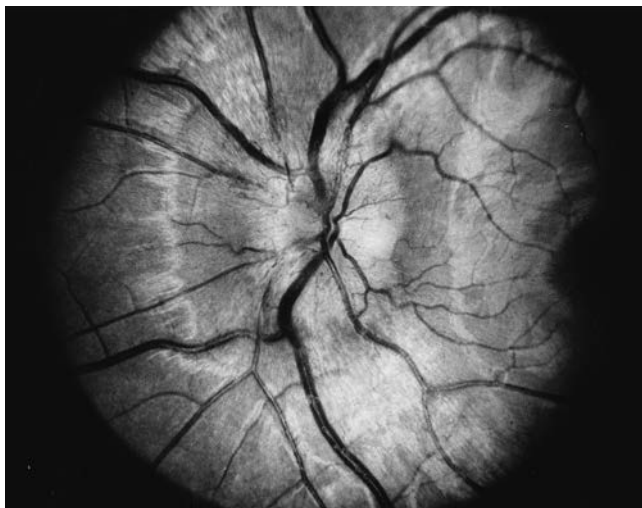

Figure 6.2. Anterior optic neuritis. There is significant swelling and hyperemia of the disc with dilated surface capillaries.

In some patients with anterior optic neuritis, a few vitreous cells may be observed, particularly in the vitreous overlying the optic disc. When the cellular reaction is extensive, etiologies other than MS should be considered (discussed later). Similarly, when macular or peripapillary hard exudates accompany the disk swelling, other conditions such as neuroretinitis should be considered (discussed later). Sheathing of retinal veins may occur in acute optic neuritis caused by certain conditions, including MS and sarcoidosis (84,85) (Fig. 6.4).

Most patients with idiopathic or demyelinating acute optic neuritis have a normal optic disc in the affected eye, unless they have had a previous attack of acute optic neuritis or

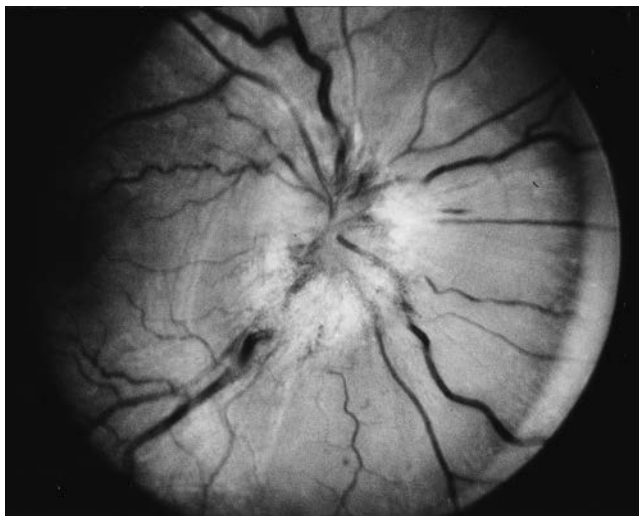


Figure 6.3. Severe optic disc swelling mimicking papilledema. Note hyperemia and elevation of the disc and several peripapillary retinal hemorrhages.

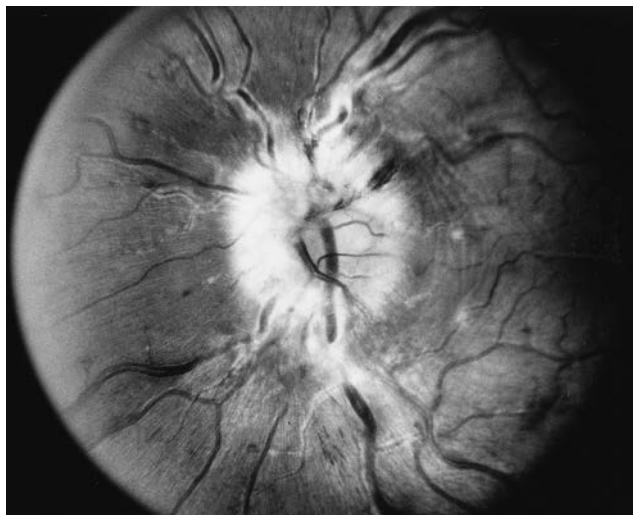

Figure 6.4. Anterior optic neuritis with venous sheathing. The patient was a 45-year-old man with sudden onset of reduced central vision in his left eye. Visual acuity was 8/200 with a large central scotoma.

have an ongoing chronic optic neuritis. With time, the optic disc becomes pale, even as the visual acuity and other parameters of vision improve (Fig. 6.5). The pallor may be diffuse or localized to a particular portion of the disc, most often the temporal region.

Other Tests of Optic Nerve Function

The results of other tests of optic nerve function, including contrast sensitivity (86), visual evoked potential (VEP), and other psychophysical tests, are almost always abnormal in patients with acute optic neuritis. For example, contrast sensitivity was abnormal in the affected eye at baseline in 98% of patients in the ONTT. Nevertheless, these tests rarely need be performed for diagnosis if other parameters are carefully evaluated. On the other hand, Froehlich and Kaufman (87) found that pattern electroretinography was useful in distinguishing anterior optic neuritis from AION. These authors reported that the amplitude of the N95 peak was abnormally reduced for every eye affected with AION, whereas it remained normal in eyes with acute anterior optic neuritis.

Visual Function in the Fellow Eye

Numerous studies have reported that asymptomatic visual dysfunction may be detected in the fellow eyes of a patient with acute unilateral optic neuritis (86–90). In the ONTT, abnormalities in the fellow eye were found on measurement of visual acuity in 13.8%, contrast sensitivity in 15.4%, color vision in 21.7%, and visual field in 48.0% of patients (7,11). Most of the fellow eye deficits resolved over several months, suggesting that such abnormalities may be caused by subclinical acute demyelination in the fellow optic nerve.

Diagnostic, Etiologic, and Prognostic Studies

Studies in patients with presumed acute optic neuritis are usually performed for one of three reasons:

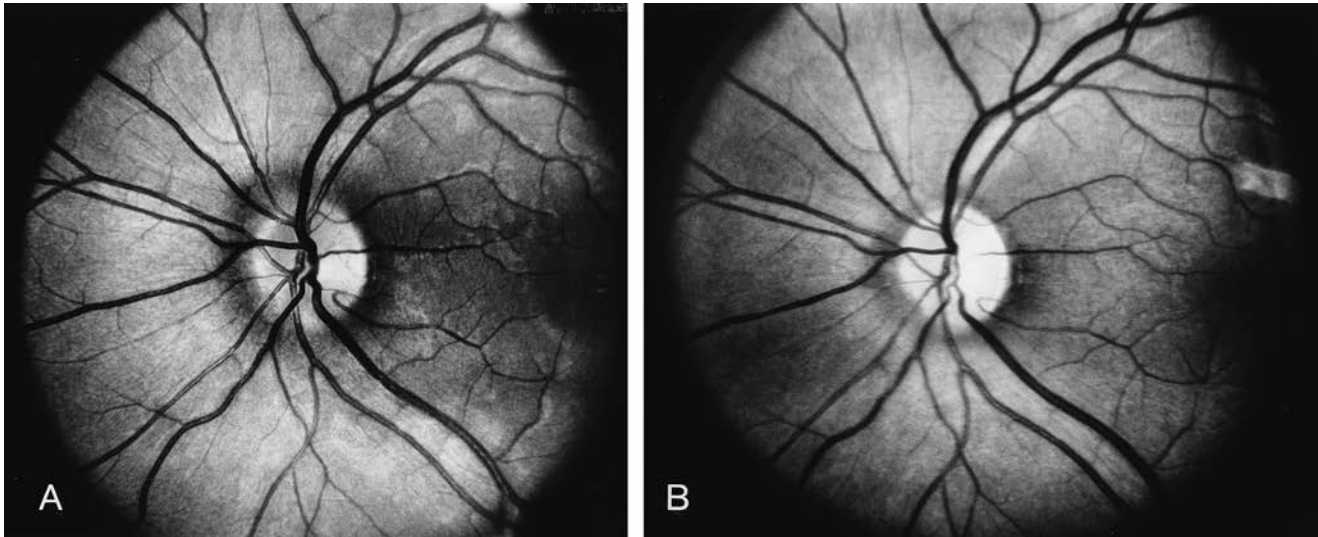


Figure 6.5. Optic atrophy after acute, retrobulbar optic neuritis. *A*, In acute phase, visual acuity in the left eye is 20/300 with a central scotoma, but the optic disc is normal. *B*, Three months later, visual acuity has returned to 20/30 but the optic disc is pale, particularly temporally, and there is mild nerve fiber layer atrophy.

1. To determine whether the cause of the acute optic neuropathy is something other than inflammation, particularly a compressive lesion
2. To determine whether a cause other than demyelination is responsible for the optic neuritis
3. To determine the visual and subsequent neurologic prognosis of optic neuritis; whether the patient will develop a more generalized demyelinating process.

Diagnostic Studies

The major concern of the physician who is evaluating a patient with acute visual loss and evidence of a unilateral optic neuropathy is whether the optic neuropathy truly is optic neuritis or is an acute manifestation of compression of the optic nerve by an intraorbital, intracanalicular, or intracranial mass. To eliminate this possibility, physicians typically perform neuroimaging studies, both computed tomographic (CT) scanning and magnetic resonance (MR) imaging, in such patients. In fact, neither study is probably warranted in patients with a typical history and findings suggesting optic neuritis.

With the widespread availability of MR imaging, CT scanning has little or no role in the evaluation of patients with presumed optic neuritis. Before MR imaging was available, CT scanning was used to detect causes of optic neuropathy other than inflammation, with positive results only occasionally. CT scanning reveals diffuse enlargement of the optic nerve in some cases of typical optic neuritis (91). The finding of an enlarged optic nerve by CT scanning in a patient with symptoms and signs most consistent with optic neuritis should not deter the physician from making that diagnosis.

MR imaging is more sensitive than CT scanning in detect-

ing lesions that compress the optic nerve in patients with presumed optic neuritis; however, the usefulness of MR imaging in detecting such lesions in patients with presumed acute optic neuritis is minimal. Among 455 patients enrolled in the ONTT with a presumptive diagnosis of acute optic neuritis, only 2 patients (0.4%) were found to have a compressive lesion that was responsible for the acute visual loss (7). One patient had an intracranial aneurysm that was not identified at the time of the initial MR imaging but that subsequently produced visual loss in the opposite eye. This, as well as worsening of the patient's visual acuity in the initially affected eye, led to a second MR study that identified the aneurysm (92). In the second patient, a pituitary adenoma was detected by initial MR imaging; however, it may be assumed that this lesion would have been diagnosed within several weeks by neuroimaging had such imaging not been performed initially, since it is likely that the patient's vision would not have improved over several weeks, as would be expected in a patient with true acute optic neuritis (discussed previously).

MR imaging can also detect demyelinating lesions of the optic nerve in patients with optic neuritis. Such lesions are seen as foci, sometimes quite extensive, of enhancement in various locations along the nerve (Fig. 6.6). Unfortunately, the appearance of these lesions is nonspecific, and a similar appearance can be observed in patients with infectious optic neuritis and radiation-induced optic neuropathy.

Although it would seem that the use of CT scanning or MR imaging to detect either a demyelinating optic nerve lesion or a compressive lesion causing acute visual loss in a patient whose symptoms suggest optic neuritis is unwarranted from the standpoint of both yield and cost effectiveness, there are more compelling reasons to obtain neuroimaging in this patient population. MR imaging should, as

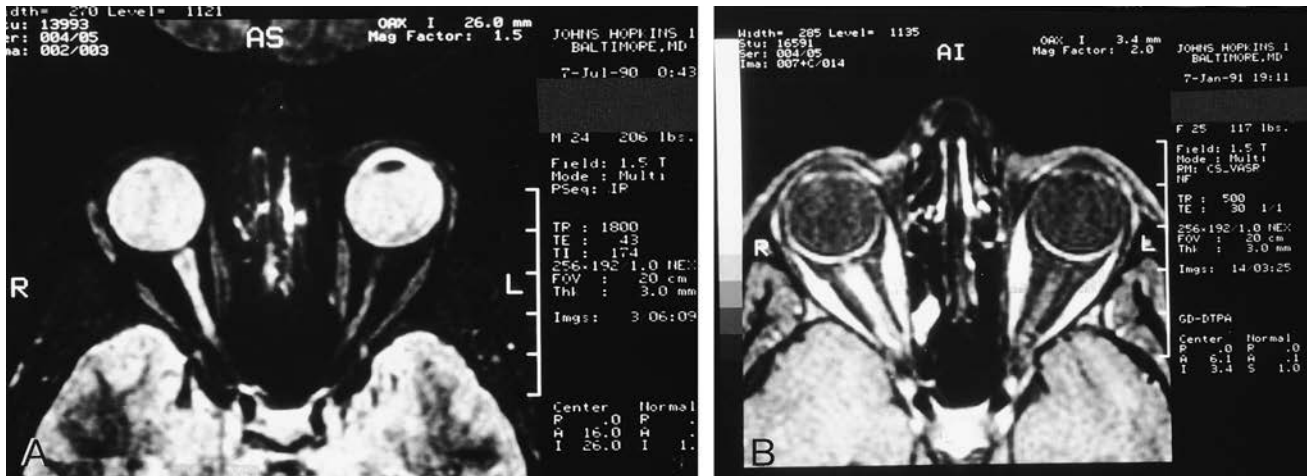


Figure 6.6. MR imaging of the optic nerve in acute demyelinating optic neuritis. *A*, Unenhanced proton density-weighted axial MR image in a 24-year-old man with right optic neuritis shows diffuse hyperintensity of the right optic nerve. *B*, T1-weighted axial MR image after intravenous injection of paramagnetic contrast material in a 25-year-old woman with right optic neuritis shows marked thickening and enhancement of the orbital portion of the right optic nerve.

noted below, be carried out primarily to look at the potential for future development of a more widespread demyelinating process in patients with a typical demyelinating optic neuritis; doing so assists clinicians in deciding on the potential use of immunomodulatory therapy.

Etiologic Studies

Although systemic and local infectious and inflammatory disorders can cause acute optic neuritis, the vast majority of patients with optic neuritis caused by such disorders can be identified simply by performing a thorough history. In patients without a history of (or consistent with) syphilis, sarcoidosis, Lyme disease, systemic lupus erythematosus, and so forth, the likelihood of such a condition being responsible for optic neuritis is low. In the ONTT, a comprehensive medical history was obtained from all patients, who then underwent blood testing for connective tissue disease (antinuclear antibody assay [ANA]) and syphilis (fluorescent treponemal antibody adsorbent test for syphilis [FTA-ABS]), and a chest radiograph to evaluate for sarcoidosis or tuberculosis (7). A lumbar puncture was optional. The key findings from this testing were as follows:

1. The ANA was positive in a titer less than 1:320 in 13% and 1:320 or more in 3%. Only one patient developed a diagnosable connective tissue disease in the first 2 years of follow-up. Visual and neurologic outcomes were no different in this subgroup.
2. The FTA-ABS was positive in six patients (1.3%), but none had active syphilis.
3. The chest radiograph did not reveal evidence of sarcoidosis or tuberculosis in any patient (8).
4. Analysis of cerebrospinal fluid (CSF) did not yield any unsuspected information in the 131 patients in whom it was performed (93).

We believe that neither serologic nor CSF studies are warranted in a patient with presumed acute optic neuritis, unless the history or examination suggests that the patient has an underlying systemic or local infection or inflammation or the patient's course does not follow that of typical optic neuritis (7).

For many years it has been postulated that a virus may play a role in the pathogenesis of MS. Numerous studies have also addressed this issue in patients with optic neuritis. Link et al. (94) found a marked increase in hemolysis-inhibiting measles virus antibody titers in the serum of patients with optic neuritis and oligoclonal immunoglobulin IgG, whereas Arnason et al. (95) were unable to find any difference in titers of hemagglutination-inhibiting measles virus antibody in patients with optic neuritis, compared with a normal population. Nikoskelainen et al. (74) studied both types of antibody in 33 patients with isolated optic neuritis and found elevated titers of both.

Antibodies against viruses other than measles have been studied in patients with optic neuritis. Nikoskelainen et al. (74) studied varicella-zoster, mumps, Coxsackie A3 and B5, polio 3, ECHO 6, cytomegalovirus, parainfluenza 1, Epstein-Barr virus, influenza A and B viruses, adenovirus, and herpes simplex antibody levels. No significant difference in viral titers was found among patients with optic neuritis, a control population, and a population with other neurologic disorders. These investigators performed serial estimations of titers in 17 patients over a period of several months and failed to find any changes in the levels. The role of a virus in the development of optic neuritis remains uncertain.

MR imaging can identify areas of inflammation within the optic nerve, thus supporting a diagnosis of optic neuritis (96–99). The most important application of MR imaging in patients with optic neuritis, however, is the identification of signal abnormalities in the white matter of the brain, usually in the periventricular region, consistent with demyelination.

Numerous studies have reported the prevalence of such abnormalities in patients with clinically isolated optic neuritis. Two or more lesions on brain MR imaging of patients with isolated optic neuritis were reported by Miller et al. (96) in 64% of 53 patients less than 50 years old who were scanned 1–40 weeks after onset. Frederiksen et al. (100) reported abnormal MR imaging in 62% of 50 patients aged 12–53 years scanned after 3–49 days, and Jacobs et al. (101) observed such abnormalities in 40% of 48 patients aged 12–61 years scanned between 3 weeks and 7 years after the onset of acute visual loss. In the ONTT, only 27% of patients had two or more signal abnormalities at least 3 mm in size (7,12), a lower percentage than reported in most other studies. The presence of multiple lesions on MR imaging in the periventricular or other white matter in the brain of a patient with presumed acute optic neuritis suggests that not only is the diagnosis of optic neuritis correct but also that the cause of the optic neuritis is demyelination.

Prognostic Studies

A substantial percentage of patients with isolated optic neuritis develop MS within months to years after the onset of the optic neuritis (discussed later). It would be helpful if there were certain studies that could be performed in a patient with isolated optic neuritis, as with any clinically isolated syndrome, that would allow the physician to accurately predict the chance of the patient developing MS. To this end, many investigators have performed serologic, CSF, and neuroimaging studies in an attempt to detect a correlation between the results of such studies and the eventual development of MS in patients with isolated optic neuritis. We will now explore that relevant information, much of which has come from the ONTT.

CSF STUDIES

The role of CSF analysis in the evaluation of patients with monosymptomatic optic neuritis is not clear. Although the presence of oligoclonal banding in the CSF is associated with the development of CDMS (102–104), the powerful predictive value of brain MR imaging for MS has reduced the role of lumbar puncture in the evaluation of a patient with optic neuritis. Whether CSF analysis can add to the predictive ability of brain MR imaging has not been definitively determined; however, results of the ONTT have helped elucidate this issue (discussed later).

Immunologic abnormalities in the CSF are common in patients with optic neuritis. Frederiksen et al. (103) reported that CSF abnormalities were present in 79% of 45 patients with isolated optic neuritis. A pleocytosis was present in 38%, increased IgG index in 36%, and oligoclonal bands in 69%. Söderström (105) reported that oligoclonal IgG bands were present in 69% of patients with optic neuritis. Other studies have reported similar results, with cell counts exceeding 4–5/mm³ in 15–51%, elevated protein concentration in 12–49%, elevated globulin in 18–40%, and oligoclonal bands in 17–51% (39,94,106–109). Rudick et al. (110) reported that free kappa-light chains in the CSF may be present in patients with optic neuritis.

In the ONTT, 131 patients underwent a lumbar puncture. Eighty-three of the patients had no clinical signs of MS at the time of optic neuritis and underwent the lumbar puncture within 24 hours of study entry (93). A pleocytosis of more than six white blood cells was present in 36% of patients; elevated levels of myelin basic protein (MBP) were present in 18%; the IgG ratio was increased in 22%; IgG synthesis was increased in 44%; oligoclonal bands were present in 50%; and kappa-light chains were present in 27%.

The predictive value of CSF oligoclonal banding for the development of CDMS within 5 years after optic neuritis was assessed in 76 patients enrolled in the ONTT (93). The presence of oligoclonal bands was associated with the development of CDMS ($P = 0.02$). However, the results suggest that CSF analysis is useful in the risk assessment of optic neuritis patients only when brain MR imaging is normal; it is not of predictive value when brain MR imaging lesions are present at the time of optic neuritis.

Of the 131 patients who had CSF testing in the ONTT cohort, 76 patients without a clinical diagnosis of probable or definite MS at trial entry who had a lumbar puncture and nonenhanced brain MR imaging performed within 24 hours of enrollment were then evaluated at 5 years into the study. The demographic characteristics of the 76 patients in this cohort were similar to the remaining ONTT patients: average age was 33 ± 7 years, 80% were female, and 91% were Caucasian. Oligoclonal band testing was performed at a local clinic laboratory for 26 of the patients and at a central laboratory for 50 (111). Brain MR imaging scans were graded by a previously published protocol (12). Neurologic examinations were performed at baseline, after 6 months, at 1 year, and yearly thereafter for 5 years. A demyelinating attack was defined as a patient-reported episode of symptoms attributable to acute demyelination in one or more regions of the CNS lasting more than 24 hours and separated from a previous attack by at least 4 weeks (112). Patients were diagnosed as having CDMS when a second attack (in addition to the optic neuritis at the time of study entry) was confirmed by an examination that detected a new neurologic abnormality. Recurrent episodes of optic neuritis in either eye were not considered in the diagnostic criteria for MS.

CDMS developed within 5 years in 22 (29%) of the 76 patients: in 16 (42%) of the 38 patients with oligoclonal bands present and in 6 (16%) of the 38 patients without bands (odds ratio [OR] = 3.88; 95% confidence interval [CI] = 1.18, 13.86; $P = 0.02$). Among the 54 patients not classified as having CDMS, 5-year follow-up was complete for 50 (93%).

The predictive value of CSF oligoclonal band assessment for the development of CDMS over and above that of brain MR imaging was apparent only among patients with no brain MR imaging lesions at study entry. Among the 39 patients with normal brain MR imaging, CDMS developed in 3 of 11 (27%) patients with oligoclonal bands present but in only 1 of 28 (4%) without oligoclonal bands. In contrast, among the 37 patients with abnormal brain MR imaging, CDMS developed in 13 of 27 (48%) with oligoclonal bands and in 5 of 10 (50%) without oligoclonal bands.

Brain MR imaging has been demonstrated to be a strong

predictor of CDMS among patients with monosymptomatic optic neuritis. In the ONTT, there was a 51% 5-year incidence of CDMS in patients who had abnormal brain MR imaging at the time of optic neuritis compared with a 16% incidence in those with normal brain MR imaging (22). These results indicated that performing a lumbar puncture to detect oligoclonal bands is not of added value for predicting the 5-year risk of CDMS in patients who have abnormal brain MR imaging at the time of development of monosymptomatic optic neuritis. However, the results suggested that oligoclonal band testing may be helpful in the risk assessment of optic neuritis patients with normal brain MR imaging.

That the value of CSF analysis would depend on the brain MR imaging findings is not surprising. Patients with abnormal brain MR imaging already have morphologic evidence of disseminated disease, and as such it is expected that most of these patients will eventually develop additional neurologic events sufficient for a diagnosis of CDMS. Therefore, there is no reason to expect that a CSF analysis would be predictive of MS among these patients. The group of patients with optic neuritis and normal brain MR imaging likely includes a subset of those destined to have MS and a subset of those who may have optic neuritis unassociated with MS. Among these patients, the finding of oligoclonal bands in the CSF does appear to increase the likelihood that CDMS ultimately will be diagnosed. Additionally and perhaps more importantly, the absence of oligoclonal bands in the CSF makes the development of CDMS within 5 years unlikely.

Although the number of patients whose CSF was studied in the ONTT was too small for definitive conclusions to be made with regard to the role of CSF analysis in the evaluation of patients with optic neuritis, the results suggest that a lumbar puncture has limited value in patients with typical monosymptomatic optic neuritis who have demyelinative changes on brain MR imaging. However, CSF analysis may help predict the development of CDMS when such MR imaging changes are not present. With longer follow-up of this cohort, a more definitive statement on the value of CSF analysis in the MR-normal patients will be possible.

IMMUNOLOGIC STUDIES

Nyland et al. (109) studied T and B lymphocytes in the blood and CSF of 10 patients with acute optic neuritis (3 with anterior optic neuritis and 7 with retrobulbar optic neuritis). These investigators found that although the percentage of T lymphocytes in the patients' blood was significantly decreased compared with controls, absolute numbers of T lymphocytes, and both relative and absolute B-lymphocyte concentrations, were not significantly different from controls. However, the percentage of T lymphocytes in the CSF of the 10 patients was significantly elevated compared with control subjects.

Frick and Stickl (113) reported that the presence of MBP in the CSF of a patient with otherwise isolated optic neuritis and no history of previous neurologic symptoms or signs nevertheless is highly predictive of the development of MS in the future, a conclusion supported by the findings of Söder-

ström et al. (114) of anti-MBP and anti-MBP peptide antibody-secreting cells in the CSF of patients with both acute optic neuritis and MS. The presence of multiple oligoclonal bands in the CSF of a patient with isolated optic neuritis also seems to be highly predictive of the future development of MS (94,115–118). Finally, Deckert-Schlüter et al. (119) detected increased concentrations of several different cytokines in the serum, CSF, or both of 20 patients with isolated optic neuritis who eventually developed MS, and Link et al. (120) reported similar results. The presence of these substances suggests an activation of the T lymphocytes of the immune system both within and outside the CNS and suggests that either their presence alone or their particular concentration may be used to predict the ultimate development of MS in these patients.

GENETIC STUDIES

There is considerable evidence that genetic factors play a role in the development of MS (121). This is based on the familial incidence of the disease (122), twin studies (123), and HLA typing patterns (108,124–127). Because T cells bind antigen only in association with a cell surface molecule encoded by the major histocompatibility complex (MHC), genes encoded by the MHC, and class II MHC genes in particular, have long been considered as candidate susceptibility loci in MS (128,129). Although an overrepresentation of A3, B7, and DR2 alleles is common in MS patients of Northern European ancestry (124,130), other MHC alleles may be present in other ethnic groups with MS. Indeed, association studies suggest that specific DR- or DQ-related restriction fragment length polymorphisms (RFLP) influence susceptibility in some patients (131–133).

Having stated that various HLA haplotypes are found with increased frequency in patients with MS compared with controls, we must also state that HLA type does not seem to strongly influence the risk of MS in patients with isolated optic neuritis (134). Hely et al. (135) reported that the relative risk for MS in patients with optic neuritis was 2.7 for those with the DR2 haplotype, 4.8 for those with the B7/DR2 type, 1.4 for those with DR3, and 0.2 for patients with the DR4 haplotype. Francis et al. (130) compared the frequency of HLA types in optic neuritis patients who developed MS compared with those who did not. HLA DR2 was present in 57% of the 58 patients who developed MS compared with 44% of those who did not. DR3 was present in 36% and 16% of the two groups, respectively ($P < 0.05$). DR2 and DR3 together were present in 14% of the MS group and 2% of the non-MS group (relative risk = 6.7; $P < 0.05$). Sandberg-Wollheim et al. (102) found that MS developed in 42% of 45 patients with optic neuritis who had the HLA DR2 haplotype and in 34% of 41 patients without this haplotype.

Among 33 patients with optic neuritis, 23 with isolated spinal cord syndromes, and 14 with an isolated brain stem disturbance, Kelly et al. (127) reported that clinical MS developed within a mean follow-up period of 5.3 years in 67% of 30 DRB1*1501-positive patients compared with 38% of 40 negative patients; 62% of DQA1*0102-positive patients

compared with 32% of negative patients; and 67% of DQB1*0602-positive patients compared with 35% of negative patients. Patients who did not progress to MS appeared to be similar to the controls. The predictive value of HLA typing in relation to brain MR imaging also was evaluated in this study. MR imaging was found to be a much stronger indicator of risk than HLA, but the combination of MR imaging and HLA haplotype DRB1*1501 increased the predictive ability. Compston et al. (125) found that positive typing for the HLA BT101, winter onset of the initial attack of optic neuritis in BT101-positive patients, and recurrent attacks of optic neuritis were associated with an increased incidence of MS.

A substantial body of data indicates that MS is a complex genetic disorder (136). This complexity may reflect polygenic inheritance (e.g., multiple susceptibility genes in a given individual), locus heterogeneity (e.g., different genes in different patients), and possibly etiologic heterogeneity as well (e.g., more than one underlying cause). To date, the most consistently observed genetic influence on MS arises from a gene or genes linked to the MHC at chromosome 6p21 and associated with haplotypes of DR2 (molecular designation DRB1*1501, DQA1*0102, DQB1*0602) (136). Several exceptions exist to the general finding of the DR2 association with MS, most notably MS in Asians (137) and MS in Sardinians (138). A recent genetic analysis of the MHC in an American MS population reported that linkage was confined to DR2-positive multiplex families; thus, locus heterogeneity exists in MS, with one DR2-associated form and one or several others unassociated with DR2 (139).

The association of the HLA-DR2 allele with brain MR imaging signal abnormalities and with the development of MS was assessed in 178 patients enrolled in the ONTT. HLA haplotype DR2 was present in 85 (48%) of the 178 patients. Its presence was associated with increased odds of probable or definite MS at 5 years (OR = 1.92, 95% CI 1.01–3.67, $P = 0.04$). The association was most apparent among patients with signal abnormalities on baseline brain MR imaging (140).

A high prevalence of DR2 was present in the ONTT cohort of patients with acute unilateral optic neuritis. This finding is consistent with earlier studies of HLA genes in which the DR2 association was nearly as strong for optic neuritis as for MS (141). The ONTT also confirmed that DR2 is associated with evolution of optic neuritis to MS, as reported in some but not all earlier reports (141). The predictive power of HLA typing in optic neuritis was weak compared with abnormal MR imaging, an expected observation considering the relatively high prevalence of DR2 in healthy Caucasians, and the specificity of MR imaging abnormalities for MS. Unexpected was the strong association observed between DR2 and MS among optic neuritis patients with abnormal baseline MR imaging, and the absence of this association in patients whose MR imaging was normal. Although derived from a relatively small number of observations, which limits the statistical power, this nevertheless suggests that multifocal disease at onset may be influenced by the HLA status of the individual, specifically by DR2 itself or by another gene in linkage disequilibrium with DR2.

Disease heterogeneity is an important emerging concept in MS. Neuropathologic studies support the concept that more than one form of MS exists, defined by whether the oligodendrocyte or the myelin sheath is the initial target of injury, and by whether evidence of antibody-mediated tissue damage is present (142,143). One clinical example of a restricted variant of MS is primary progressive MS, which in Caucasians is characterized by common occurrence in men, little inflammation, few cerebral lesions, frequent spinal cord disease, and a prominent axonal pathology (144). In another example, two clinical forms of MS have been described in Japan. The first, a disseminated disorder with widespread brain lesions detected by MR imaging, resembles MS in Caucasians and is associated with DR2. The second, a relapsing-remitting or progressive disorder with predominant spinal cord and optic nerve involvement, is not DR2 associated (137). Thus, at least in some situations, DR2-negative individuals may have a propensity to develop topographically restricted forms of demyelinating disease.

A better understanding of the predictive value of these and other serum and CSF findings for the development of MS awaits further development in the arenas of neuroimmunology and the genetics of demyelinating disease. Nevertheless, there appear to be certain serologic and CSF risk factors that increase the likelihood that a patient with isolated optic neuritis will eventually develop MS.

MR IMAGING

In the previous sections, we emphasized that MR imaging in patients with presumed acute optic neuritis is probably not warranted with respect to the identification of a lesion that is compressing the optic nerve and producing a compressive optic neuropathy that is mimicking optic neuritis. Similarly, one does not necessarily need to perform MR imaging to confirm a diagnosis of optic neuritis. On the other hand, it is certainly clear that the results of MR imaging correlate with the eventual development of MS.

The presence of multiple lesions in the periventricular and other white matter on MR imaging, a phenomenon noted in 30–70% of patients with isolated optic neuritis (7,12,145, 146), appears to be the most significant risk factor associated with an increased likelihood of developing MS (13,103,147, 148). MS was reported by Jacobs et al. (101) to have developed in 6 of 23 patients (26%) with abnormal brain MR imaging, compared with only 3 of 25 patients (12%) with a normal scan within a mean follow-up of 4 years. Martinelli et al. (149) diagnosed MS in 7 of 21 patients (33%) with isolated optic neuritis and an abnormal MR scan compared with none of 16 patients with optic neuritis and a normal scan within a mean follow-up of 2.7 years. Frederiksen et al. (100) diagnosed MS in 7 of 30 (23%) patients with optic neuritis and an abnormal MR scan compared with none of 20 patients with optic neuritis and a normal scan within mean follow-up of 0.9 years. Finally, Morrisey et al. (150) reported the development of MS in 23 of 28 (82%) optic neuritis patients with an abnormal scan compared with only 1 of 16 (6%) patients with a normal scan over a mean follow-up of 5.5 years. The study by Morrisey et al. (150) is particularly

important because it suggested that with sufficiently long follow-up, most, if not all, patients with acute optic neuritis who have silent brain MR imaging signal abnormalities ultimately develop additional clinical manifestations sufficient for a diagnosis of definite MS. Among patients with isolated optic neuritis in the ONTT, the cumulative percentage developing MS within 4 years of the onset of the optic neuritis was about 13% in patients with normal MR imaging, 35% in patients with only one or two lesions, and 50% in patients with more than two lesions (20). By 10 years, patients who had one or more typical MR lesions had a 56% risk and those with no baseline lesions had a 22% risk (23) (Fig. 6.7). Higher numbers of lesions did not increase the risk of MS.

MR imaging has taken on an increasingly important role in the diagnosis and monitoring of patients with MS (151). Current MS diagnostic criteria following a monosymptomatic presentation incorporate changes in serial MR findings as documentation of dissemination in time (152). Accordingly, the long-term MR characteristics of monosymptomatic optic neuritis patients not developing MS on clinical grounds are of great interest. Continued follow-up of the cohort of participants enrolled in the ONTT has provided the opportunity to evaluate brain MR scans 10 to 14 years after optic neuritis in patients who have not developed CDMS. The objective of this study was to determine the proportion of such patients who manifest new brain MR lesions on follow-up scans (26).

In the ONTT, among 61 patients with normal baseline MR scan who had not developed clinical evidence of MS after 10 years, 27 (44%) exhibited at least one new lesion of more than 3 mm on follow-up brain MR scans (23,26). Subclinical demyelination is the most logical explanation for the new MR findings within this relatively young population, although for some of the patients it is possible that the lesions

were present at the time of the initial scan but were not detected due to the scan technique. On the other hand, the fact that 34 patients (56%) did not develop clinical signs or MR evidence of demyelination after 10 years suggests that there are many cases of optic neuritis that may be unrelated to MS.

Among the 35 patients whose baseline MR scan showed at least one T2 lesion measuring at least 3 mm, 26 (74%) developed at least one new lesion larger than 3 mm on follow-up imaging in the absence of a clinical diagnosis of MS (26). This phenomenon merely underscores the well-known dissociation between MR findings and clinical expression of MS. The fact that an abnormal baseline MR scan was more likely to show additional lesions than a normal baseline MR scan emphasizes the predictive value of the initial scan. The presence of even a single lesion predicted the development of further lesions. However, the development of new lesions does not necessarily indicate that the patient will develop clinical signs of MS even after 10 years.

Among the 12 patients with only punctate T2 hyperintensities on baseline imaging, 9 (75%) exhibited changes on long-term MR scanning, a frequency similar to that in the patients with at least one lesion measuring more than 3 mm on the baseline MR scan (26). This finding suggests that a focal signal abnormality of any size may predict that additional signal abnormalities will occur in this population.

The data from the ONTT follow-up patients have several limitations. MR technology continues to advance, and multicenter, serial MRI studies are often forced to compare images obtained with different magnets, field strengths, and protocols. Repositioning error on serial imaging is also a source of potential difference between baseline and follow-up MR scans. The use of magnets with higher field strength and smaller slice thickness scans at follow-up may have overestimated MR changes over time. However, changes in these parameters appear to affect the assessment of lesion volume more than lesion numbers. The addition of good-quality spinal cord imaging may also increase the percentage of patients with asymptomatic demyelinating lesions. Imaging confined to the brain would, therefore, underestimate the total burden of T2 changes over time. It is possible that not all the T2 MR changes over time were the result of demyelination. Vasculopathic risk factors such as advanced age, diabetes, and hypertension may contribute to T2 MR lesions, but this seems unlikely to explain a significant portion of the change observed in this relatively young cohort. Despite the limitations on interpretation of the results imposed by the differences in MR technique from baseline to follow-up scans in the ONTT cohort studied, it is important to recognize that these differences affect only the incidence of new lesions and not the observed proportion of patients who have remained lesion-free after 10 years.

The ONTT experience is unique in reporting the long-term MR changes following monosymptomatic optic neuritis in the absence of the development of clinical signs of MS. The results support the notion that not all cases of monosymptomatic optic neuritis are related to MS, since a subset of patients manifested neither clinical signs nor MR evidence of demyelination after more than 10 years of follow-up (23,26). In addition, the results indicate that MR signal ab-

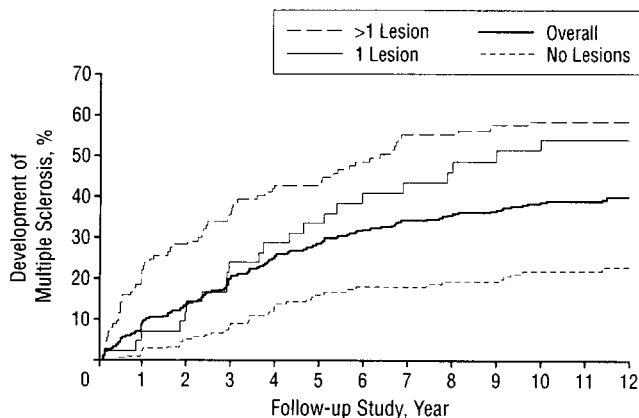


Figure 6.7. The cumulative probability of multiple sclerosis was statistically significantly higher in patients with one or more lesions seen on the baseline MR scan of the brain than in patients with no brain lesions ($P < 0.001$, log rank test) but was not significantly different between patients with a single brain lesion and patients with multiple lesions ($P = 0.22$, log-rank test). (From Optic Neuritis Study Group. High- and low-risk profiles for the development of multiple sclerosis within 10 years after optic neuritis: experience of the optic neuritis treatment trial. *Arch Ophthalmol* 2003;121:944-949.)

normalities may accumulate without causing any clinical manifestations of MS, even when the patient is followed for over a decade. Although treatment decisions should take this fact into account, it should be emphasized that MS is a life-long disease, and the majority of disability is encountered following 10–15 years of disease involvement.

VITREOUS FLUOROPHOTOMETRY

Braude et al. (153) evaluated vitreous fluorophotometry in six patients with acute retrobulbar optic neuritis. These investigators found an acute increase in posterior vitreous fluorophotometric readings in one or both eyes of all six patients. They speculated that the abnormally high vitreous fluorophotometric findings in the patients are caused by an increased permeability of the blood–ocular barrier, presumably the result of inflammation in the retrolaminar portion of the optic nerve and possibly in the posterior pole vasculature. As with other tests that have been suggested as aids in the diagnosis of optic neuritis, further testing is necessary to determine the accuracy and clinical usefulness of this procedure.

Treatment

In 1949, Hench et al. (154) described the beneficial effects of systemic corticosteroids in the treatment of rheumatoid arthritis. Following this report, physicians began to consider other disorders, including optic neuritis, that might respond to similar treatment or to treatment with adrenocorticotrophic hormone (ACTH). The first systematic attempt to address this issue was a double-blind prospective study of the treatment of 50 patients with acute retrobulbar neuritis with either ACTH or placebo (155,156). The study showed that the group treated with ACTH recovered vision faster, but at 1 year the mean visual acuities in the two groups were not significantly different from each other.

In the Cooperative Multiple Sclerosis Study (157), there were 41 cases in which optic neuritis was the primary manifestation of MS for which patients were entered into the study. The 22 patients treated with ACTH improved faster than the 19 patients treated with placebo, but there was no long-term follow-up. Bowden et al. (158) performed a prospective clinical trial in 54 patients with acute optic neuritis. The study showed no benefit on visual acuity of ACTH compared with placebo in these patients.

Gould et al. (159) performed a prospective single-blind controlled clinical trial in which 74 patients with optic neuritis either received a retrobulbar injection of triamcinolone or were randomized to a control group that received no treatment. Visual acuity in the affected eyes of the treated patients improved faster than did visual acuity in the affected eyes of patients who received no treatment, but there was no difference in mean visual acuity between the two groups after 6 months. Trauzettel-Klosinski et al. (160) subsequently performed a study in which 50 patients with acute optic neuritis were randomized to receive either oral corticosteroids or placebo. There was a suggestion of a slightly more rapid recovery of vision in the patients treated with steroids compared with patients in the placebo group, but there was no

difference in vision between groups at 12 months. In the meantime, Spoor (161) and Spoor and Rockwell (162) described rapid recovery of vision in two small series of patients with optic neuritis treated with intravenous methylprednisolone.

As noted previously, patients with acute optic neuritis who enrolled in the ONTT were randomized to one of three treatment groups: (a) oral prednisone (1 mg/kg/day) for 14 days; (b) intravenous methylprednisolone sodium succinate (250 mg qid for 3 days followed by an oral prednisone 1 mg/kg/day) for 11 days; and (c) oral placebo for 14 days. Each regimen was followed by a short oral taper (6,8). Most patients in all three treatment groups had a good recovery of vision (8). After 6 months of follow-up, the median visual acuity in each group was 20/16, and less than 10% of the patients in each group had visual acuity of 20/50 or worse. One year after the onset of visual symptoms, there was no significant difference in mean visual acuity, color vision, contrast sensitivity, or visual field (by mean deviation) among the three groups (14,15). On the other hand, patients treated with the regimen of intravenous methylprednisolone followed by oral prednisone recovered vision considerably faster than patients treated with oral placebo (8) (Fig. 6.8). The benefit of this treatment regimen was greatest in the first 15 days of follow-up and decreased subsequently.

Patients treated with oral prednisone alone did not recover vision any faster and had no better vision at the end of a 6-month follow-up period than patients treated with oral placebo (8). Unexpectedly, patients treated with oral prednisone alone had an increased rate of recurrent attacks of optic neuritis in the previously affected eye and an increased rate of new attacks of optic neuritis in the fellow eye compared with patients in the other two groups (8) (Fig. 6.9). Thus, oral prednisone in a dose of 1 mg/kg/day did not speed recovery of vision compared with no treatment, did not improve ultimate visual acuity compared with no treatment, and produced a higher rate of recurrent and new attacks of optic neuritis than no treatment.

The ONTT also evaluated the rate of development of clinical MS in the three treatment groups and found that the patients treated with the intravenous followed by oral corticosteroid regimen had a reduced rate of development of clinically definite MS during the first 2 years (13,19). The benefit of treatment was seen only in patients who had significantly abnormal brain MR imaging at the onset of the optic neuritis. The 2-year risk of MS was too low in those with normal brain MR imaging to assess the value of treatment in such patients. The clinical benefit of the intravenous treatment lessened over time, such that at 3 years of follow-up there was no significant difference in the rate of development of MS among treatment groups.

In the acute phase of optic neuritis, no treatment other than corticosteroids or related agents such as ACTH have been shown to be efficacious; however, intravenous immunoglobulin (IVIg) has been demonstrated in animals to promote remyelination of the CNS in experimental allergic encephalomyelitis (163–165) and in Theiler's virus model of MS (166–169).

In a small pilot study, it was suggested that IVIg may

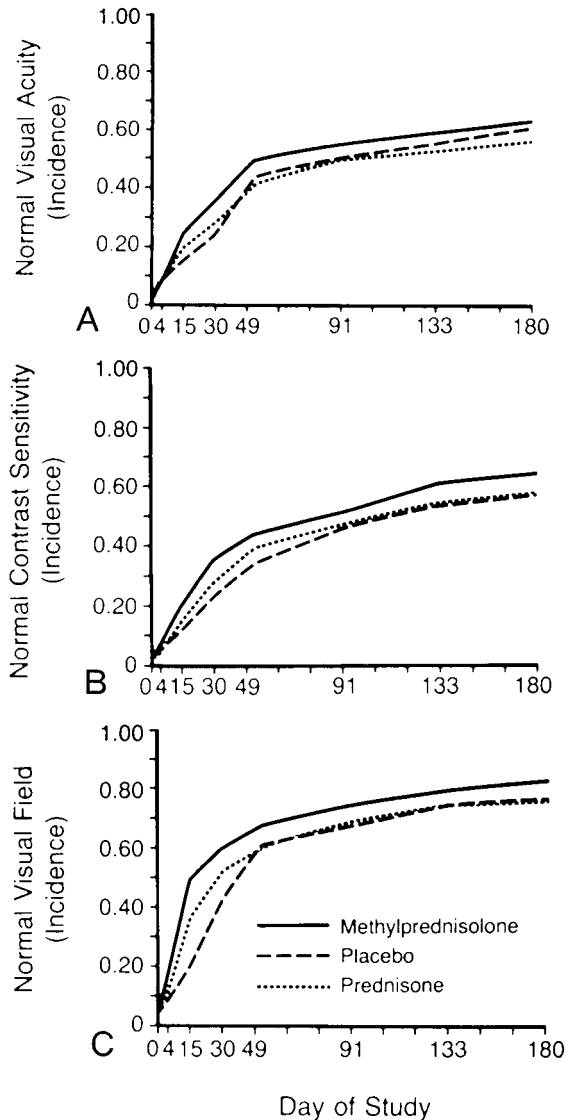


Figure 6.8. Speed of visual recovery in patients with acute optic neuritis treated with intravenous high-dose methylprednisolone (1 g/day for 3 days), followed by a 2-week course of oral prednisone (1 mg/kg/day) (solid line), compared with patients treated with oral prednisone alone (dotted line) and untreated patients (given placebo) (dashed line) in the Optic Neuritis Treatment Trial. Improvement in visual acuity (A), contrast sensitivity (B), and visual field (C) occurred more rapidly in patients treated with the intravenous regimen than in patients given either low-dose oral prednisone or in untreated patients. (From Beck RW, Cleary PA, Anderson MM Jr, et al. A randomized, controlled trial of corticosteroids in the treatment of acute optic neuritis. The Optic Neuritis Study Group. *N Engl J Med* 1992; 326:581–588.)

have some benefit in patients with resolved optic neuritis who have significant residual visual deficits (170). Noseworthy et al. (171) looked at whether IVIg reverses chronic visual impairment in MS patients with optic neuritis. In a double-blind, placebo-controlled phase II trial, 55 patients with persistent acuity loss after optic neuritis were random-

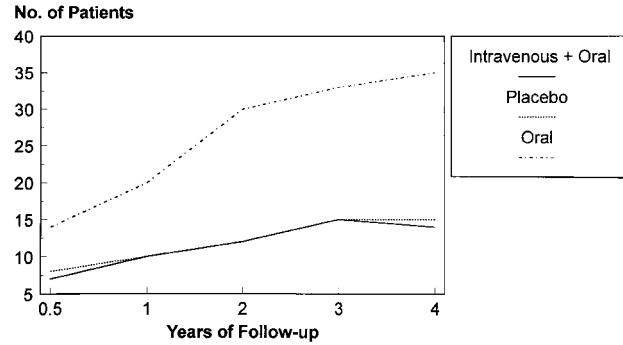


Figure 6.9. Incidence of recurrent attacks of optic neuritis in the previously affected eye and new attacks of optic neuritis in the fellow eye of patients enrolled in the Optic Neuritis Treatment Trial and Longitudinal Optic Neuritis Study by treatment groups. Patients treated with oral prednisone alone, in a dose of 1 mg/kg/day for 14 days, had a much higher incidence of such attacks than patients given oral placebo or patients treated with intravenous methylprednisolone in a dose of 250 mg q6h for 3 days, followed by an 11-day course of oral prednisone in a dose of 1 mg/kg/day.

ized to receive either IVIg 0.4 g/kg daily for 5 days followed by three single infusions monthly for 3 months, or placebo. The trial was terminated by the National Eye Institute because of negative results when 55 of the planned 60 patients had been enrolled. Fifty-two patients completed the scheduled infusions, and 53 patients completed 12 months of follow-up. Analysis of these data indicated that a difference between treatment groups was not observed for the primary outcome measure, improvement in logMAR visual scores at 6 months ($P = 0.766$). Exploratory secondary analyses suggested that IVIg treatment was associated with improvement in visual function (including logMAR visual scores at 6 months and visual fields at 6 and 12 months) in patients with clinically stable MS during the trial. It was the conclusion of the investigators that IVIg administration does not reverse persistent visual loss from optic neuritis to a degree that merits general use.

On the basis of the above data, we believe there is no treatment for acute demyelinating optic neuritis that can improve the ultimate visual prognosis compared with the natural history of the disorder (9,10,20,21). A short course of intravenous methylprednisolone (250 mg every 6 hours for 72 hours) followed by a 2-week course of oral prednisone given orally (11 days of 1 mg/kg/day followed by a 3-day taper) may result in an increase in the speed of recovery of vision by 2–3 weeks compared with no treatment when the steroids are begun within 1–2 weeks of the onset of visual loss (8,172), but the ultimate visual function at 1 year will be the same as it would have been if no treatment were given (14). The use of oral corticosteroids alone, when given to patients with acute optic neuritis at a dosage of 1 mg/kg/day, not only does not improve visual outcome or speed recovery but is also associated with a significantly higher incidence of recurrent attacks of optic neuritis in the same eye and new attacks in the contralateral eye than in patients who either are not treated or receive intravenous corticoste-

roids before a short oral course of steroids (8). In view of these findings, we and others believe it is inappropriate to treat any patient with acute demyelinating optic neuritis with oral corticosteroids alone at this dosage (8–10,20,21). It is possible that a high dose of prednisone, given orally, might have the same effect as intravenously administered methylprednisolone.

Visual Prognosis

The natural history of acute demyelinating optic neuritis is to worsen over several days to 2 weeks, and then to improve. The improvement initially is fairly rapid. It then levels off, but further improvement can continue to occur 1 year

after the onset of visual symptoms (14,18,39,41,82) (Fig. 6.10). Among patients enrolled in the ONTT who received placebo, visual acuity began to improve within 3 weeks of onset in 79% and within 5 weeks in 93%. For most patients in this study, recovery of visual acuity was nearly complete by 5 weeks after onset (8,14). The mean visual acuity 12 months after an attack of otherwise uncomplicated optic neuritis is 20/15, and less than 10% of patients have permanent visual acuity less than 20/40 (14). Other parameters of visual function, including contrast sensitivity, color perception, and visual field, improve in conjunction with improvement in visual acuity (16,41,55,173–175).

The visual improvement that occurs in patients with acute optic neuritis tends to do so regardless of the degree of visual

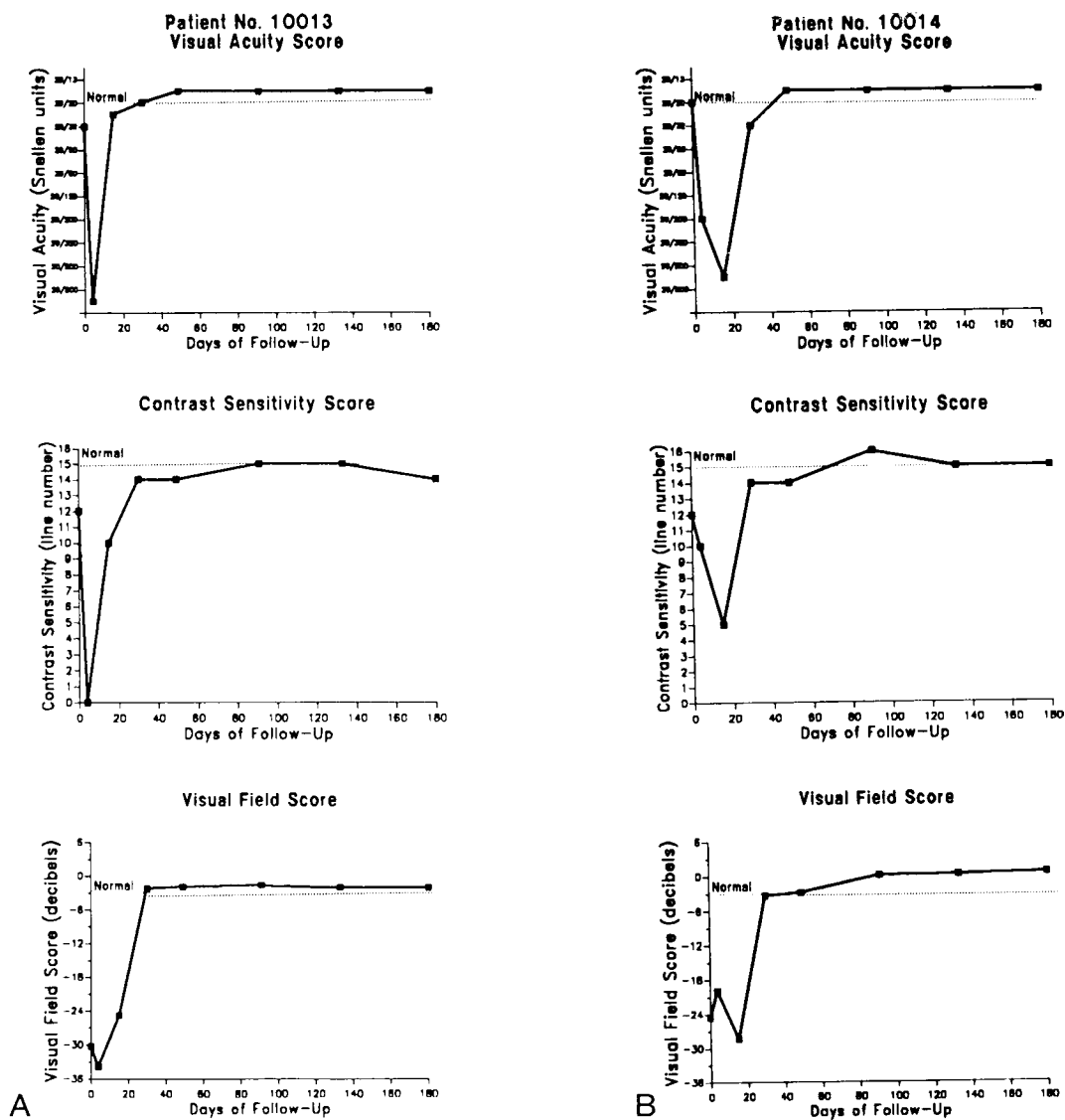


Figure 6.10. Time course of improvement in visual function after an attack of acute demyelinating optic neuritis in two different patients, neither of whom was treated with systemic corticosteroids. Note the rapid drop in visual function over several days followed shortly thereafter by concomitant improvement in visual acuity, contrast sensitivity, and visual field. Improvement in visual function initially was rapid but then leveled off.

loss, although there is some correlation between the severity of visual loss and the degree of eventual recovery. Factors such as age, gender, optic disc appearance, and pattern of the initial visual field defect do not appear to have any appreciable effect on the visual outcome (18,39,82,176). Bradley and Whitty (82) evaluated 73 patients with acute optic neuritis and found that among patients with initial visual acuity of 20/200 or worse, about 60% had acuity of 20/30 or better at 6 months compared with about 70% in patients whose initial visual acuity was better than 20/200. Cohen et al. (51) found that in 24 patients with acute unilateral optic neuritis and initial visual acuity worse than 20/200, the visual acuity remained at that level in only 9 eyes. Slamovits et al. (177) reported that of 12 patients with acute optic neuritis whose vision became reduced to no light perception, all 12 showed some improvement; indeed, visual acuity improved to 20/40 or better in 8 and 20/20 or better in 5. Of 167 eyes of patients enrolled in the ONTT in which the baseline visual acuity was 20/200 or worse, only 10 (6%) had this level of vision or worse 6 months later (8,15). Of 28 patients whose initial visual acuity in the affected eye was light perception or no light perception, 18 (64%) recovered to 20/40 or better (8,15).

Even though the overall prognosis for visual acuity after an attack of acute optic neuritis is extremely good, some patients have persistent severe visual loss after a single episode of optic neuritis (8,14,15,41,178,179). Even those patients with improvement in visual function to "normal" may complain of movement-induced photopsias and may have persistent visual deficits when tested using more sensitive clinical, electrophysiologic, or psychophysical tests (58,60,180–194).

Continued follow-up of the cohort of patients who were enrolled in the ONTT has provided a unique opportunity to assess the long-term course of vision following an episode of acute optic neuritis. In most patients, once visual acuity stabilized after the initial episode of optic neuritis (as determined from the acuity measurement 1 year after the episode), it remained remarkably stable for more than 10 years (24). After 10 years, 69% of patients had acuity of 20/20 or better in each eye, whereas 1% were worse than 20/200 in both eyes. As was reported after 5 years of follow-up, visual function was worse in those patients with MS than in those without MS (22,24). Further attacks of optic neuritis in either eye occurred in 35% of all patients and were twice as common among patients diagnosed with MS at baseline or who developed MS during the follow-up period. As a group, the ONTT patients had lower (worse) quality of life scores as measured on the National Eye Institute Visual Function Questionnaire (NEI-VFQ) compared with a reference group (24). A reduction in NEI-VFQ scores was strongly related to a measured reduction in visual acuity and to the presence of MS. Among patients with acuity in each eye of 20/20 or better and among patients who did not have MS, the scores were quite similar to the reference group.

There are few long-term follow-up data in the literature for comparison with the results of the ONTT. The finding that after more than 10 years of follow-up 86% of the affected eyes had visual acuity of 20/25 or more and 91% had

acuity of 20/40 or more (24) is comparable to that of Bradley and Whitty (82), who reported that 86% of 66 patients were 20/25 or more (mean follow-up after episode of optic neuritis of 10.2 years, range 6 months to 20 years), and Cohen (51), who reported that 82% of 60 patients had visual acuity of 20/40 or more (mean follow-up 7.1 years after optic neuritis, range 5–12 years). The 10-year ONTT recurrence rate of 35% is similar to that reported by Cohen (42%) (51) but higher than that reported in other studies with extended follow-up such as those by Bradley and Whitty (18%) (82), Hutchinson (24%) (83), and Rodriguez (16%) (33).

Over time, some attrition of the original ONTT cohort has occurred. This has more impact on the vision assessment than it does on the neurologic assessment, since for the latter the investigators were able in many cases to determine whether MS had developed through either phone contact with the patient or medical records, whereas the former requires the completion of specific visual function tests. Patients who were no longer being followed in the cohort had slightly worse baseline acuity in the affected eye both at baseline and at the time of the last completed visit. The ONTT reported vision results for the patients completing the examination are likely to be slightly biased toward those with better vision. The results of the ONTT can be used by clinicians to advise patients that the long-term visual prognosis is good following an episode of optic neuritis. Follow-up of this cohort will continue with the support of the National Eye Institute, and patients will be examined again in 2006 (24).

Residual Visual Deficits After Resolution of Optic Neuritis

Following an attack of acute optic neuritis, disturbances in visual acuity (15–30%), contrast sensitivity (63–100%), color vision (33–100%), visual field (62–100%), stereopsis (89%), light brightness sense (89–100%), pupillary reaction to light (55–92%), optic disc appearance (60–80%), and the VEP (63–100%) may all persist. Kirkham and Coupland (195) examined 93 patients with previously diagnosed optic neuritis and submitted the results of several diagnostic tests in these patients to linear stepwise multiple regression analysis. The analysis indicated that the most common findings after an attack of acute optic neuritis were optic atrophy, defective color vision, and a prolonged pupil cycle time. Other findings in these patients included a relative afferent pupillary defect, an abnormal response to the Pulfrich test, and an abnormal VEP.

Visual Acuity

Most patients recover to normal or near-normal visual acuity. Bradley and Whitty (82) found that 50% of patients recovered vision to 20/30 or better within 1 month of initial visual loss, and 75% recovered to 20/30 or better within 6 months. In the series reported by Perkin and Rose (39), 87% of patients with optic neuritis recovered vision better than 20/40, and only 8% had vision worse than 20/200 after a minimum follow-up period of 6 months. In the ONTT, after 12 months of follow-up visual acuity was more than 20/20

in 69%, 20/40 or more in 93%, and 20/200 or less in only 3%. The results in each treatment group were similar (14).

Color Vision

Persistent disturbances of color vision are present in a high percentage of eyes with otherwise resolved optic neuritis. Wybar (196), for instance, found disturbances of color vision in 56% of 25 cases of resolved optic neuritis using Ishihara pseudoisochromatic plates, whereas Lynn (197) reported a figure of 84% among 143 cases. Burde and Gallin (181) reported an abnormal Farnsworth-Munsell 100-Hue color test in three of nine eyes in which visual acuity had recovered to normal after an attack of retrobulbar neuritis. Griffin and Wray (63) tested 30 eyes with resolved retrobulbar neuritis that recovered visual acuity to 20/40 or better. Color vision testing using Ishihara pseudoisochromatic plates was abnormal in 15 of 22 patients tested, and assessment of color vision using the Farnsworth-Munsell 100-Hue test revealed abnormalities in all 30 patients. Perkin and Rose (39) reported finding defects in color vision in 50% of 112 eyes with resolved optic neuritis. Kirkland and Coupland (195) found that defective color vision was one of the most common findings in eyes with a history of well-documented acute optic neuritis. Fleishman et al. (90) tested 27 patients with resolved optic neuritis and found abnormalities in 34% of eyes tested with Ishihara color plates and 63% of eyes tested with the Farnsworth-Munsell 100-Hue test. In the ONTT, color vision measured by the Farnsworth-Munsell 100-Hue test was normal within 6 months in only 60% of patients (8). In our experience, the percentage of eyes with color vision disturbances is related in large part to the sensitivity of the test that is used to detect such defects.

Visual Field

Residual visual field defects are usually present in eyes after resolution of acute optic neuritis, even when visual acuity has returned to 20/20 or better. Using a Friedman Visual Field Analyzer, Bowden et al. (158) found defects in 67% of 35 eyes tested; Van Dalen and Greve (198) in 86% of 14 eyes; and Perkin and Rose (39) in 72% of 120 eyes. Nikoskelainen (107) performed kinetic perimetry using a Goldmann perimeter and found abnormalities in the visual field in 62% of 167 eyes that had experienced an attack of acute optic neuritis. Burde and Gallin (181) reported normal kinetic perimetry but abnormal static perimetry in each of nine eyes with a good recovery of visual acuity following an attack of acute retrobulbar optic neuritis. Fleishman et al. (90) reported visual field defects in 26% of eyes that had normal visual acuity after an attack of acute optic neuritis. Among patients enrolled in the ONTT, the mean deviation of the visual field performed using a Humphrey Field Analyzer was abnormal at 6 months in 32% (8).

Contrast Sensitivity

Contrast sensitivity provides a measure of the ability of an eye to detect a difference in luminosity between an object and its background. Numerous studies using various meth-

ods of measuring contrast sensitivity have shown that contrast sensitivity remains abnormal regardless of the degree of visual recovery in most eyes after resolution of acute optic neuritis. Arden and Gucukoglu (86) reported abnormal contrast sensitivity using hand-held grating plates in 70% of 57 eyes with resolved optic neuritis, and both Zimmern et al. (199) and Sjöstrand and Abrahamsson (200) reported abnormal contrast sensitivity in 100% of eyes with 20/20 visual acuity after an attack of acute optic neuritis. Using an automated system, Sanders et al. (53) found abnormal contrast sensitivity over a wide range of spatial frequencies in 63% of 64 eyes with resolved optic neuritis. In this study, the subjective visual complaints of the patients correlated better with impaired contrast sensitivity than with any other measure of visual function, including visual acuity, color vision, and visual field. Beck et al. (88) reported abnormal contrast sensitivity in 78% of 51 eyes with recovered optic neuritis. Among 33 of these eyes with visual acuity of 20/25 or better, contrast sensitivity was still abnormal in 67%. Fleishman et al. (90) found abnormalities in contrast sensitivity in 75% of 27 eyes with recovered optic neuritis and good visual acuity. Drucker et al. (201) tested 25 eyes with good visual acuity (20/30 or better) following optic neuritis with the Regan Low Contrast Letter Chart. Contrast sensitivity was abnormal (defined as two standard deviations below the normal group mean determined as part of the study) in 84% of the affected eyes. In the ONTT, contrast sensitivity measured with the Pelli-Robson chart was abnormal at 6 months in 56% (8).

Contrast sensitivity is often abnormal in cases of MS in which there has not been overt acute optic neuritis (202,203) and in some fellow eyes in cases of apparent unilateral optic neuritis (53,86,88). These findings suggest that these eyes have subclinical optic nerve demyelination that was not necessarily detected by testing of other types of visual function.

Stereopsis

Stereopsis is a binocular function that is defined as the ability to discern a separation in the distance of two static objects. Patients with reduced stereopsis often complain of a loss of depth perception. Friedman et al. (204) tested stereopsis using the Titmus test in patients with various optic neuropathies and found that it was worse relative to the reduction in visual acuity in most of these patients. In the 13 patients they tested with visual acuity of 20/40 or better, 11 had stereopsis worse than predicted by the level of acuity. Fleishman et al. (90) found stereopsis to be reduced in 89% of 19 patients with a history of unilateral optic neuritis and in 75% of 8 patients with a history of bilateral optic neuritis.

Light-Brightness Sense

Patients often complain that vision appears dimmer in one eye compared with the other after resolution of optic neuritis. Sadun and Lessell (205) developed an instrument that could quantify this reduction in brightness. Among 15 patients with acute unilateral optic neuritis of less than 3 months' duration, 12 of whom had recovered visual acuity to 20/20 in the affected eye, all noted a reduction in perceived light

brightness in the previously affected eye compared with the unaffected eye. Fleishman et al. (90) found light brightness to be reduced in a high percentage (89%) of patients with resolved unilateral optic neuritis.

Pupillary Reaction

Many patients with unilateral acute optic neuritis have a persistent relative afferent pupillary defect on the affected side, even when excellent recovery of vision has occurred. In the ONTT, 54% of the patients without a past history of optic neuritis in the fellow eye had a relative afferent pupillary defect 6 months after the onset of visual symptoms (8).

Burde and Gallin (181) detected a relative afferent pupillary defect in five of nine eyes following a good recovery from acute unilateral optic neuritis. Using pupillometry, Ellis (77) found a relative afferent pupillary defect in each of 13 patients with resolved optic neuritis. All of the 13 eyes also had a persistent reduction in the amplitude of the VEP. Perkin and Rose (39) noted a relative afferent pupillary defect in 55% of 139 eyes after acute optic neuritis, Bynke et al. (206) in 41% of 31 patients. Cox et al. (78) detected a relative afferent pupillary defect by the swinging flashlight test in 92% of 50 patients with resolved optic neuritis.

Optic Disc Appearance

Optic disc pallor is almost always present when visual recovery has been incomplete and is often present even when recovery has been excellent (Figs. 6.5 and 6.11). The pallor is usually temporal, but it may be generalized. Wybar (196) noted optic disc pallor in 67% of 33 eyes with resolved optic neuritis, whereas Lynn (197) reported it in 80% of 160 eyes, Bowden et al. (158) in 70% of 54 eyes, Nikoskelainen (107)

in 60% of 167 eyes, Burde and Gallin (181) in 5 of 9 eyes, and Perkin and Rose (39) in 62% of 165 eyes. In the ONTT, 63% of patients had evidence of optic disc pallor at 6 months (8).

Perhaps more common than optic atrophy is the development of defects in the retinal nerve fiber layer after an attack of acute optic neuritis (207). Most patients develop such defects, which may be diffuse, localized to the papillomacular bundle, or isolated defects in the arcuate regions.

Visual Evoked Potentials (VEPs)

The VEP is an electroencephalographic recording over the occipital lobe in response to visual stimulation. It is occasionally used as an objective measure of conduction in the afferent visual system (see Chapter 2). After resolution of acute optic neuritis, most patients have a prolonged latency, indicating impaired optic nerve conduction. Shahrokhi et al. (208) reported an abnormal VEP in 95% of 58 eyes with resolved optic neuritis, Bynke et al. (206) in 71% of 42 cases, and Wutz et al. (209) in each of 19 patients. In cases of optic neuritis with visual recovery to 20/40 or better, Griffin and Wray (63) reported an abnormal VEP in 93% of 30 eyes, Arden and Gucukoglu (86) in 63% of 24 eyes. Halliday et al. (210) and Asselman et al. (211) found abnormal visual evoked potentials in all 24 and 15 cases, respectively, of resolved optic neuritis occurring in patients with MS. Halliday et al. (212) reported that when visual acuity returned to 20/20, the amplitude of the VEP often was normal, but the latency was virtually always still abnormal.

Subjective Visual Complaints

Despite the often-excellent measured recovery of visual function after an attack of acute optic neuritis, many patients

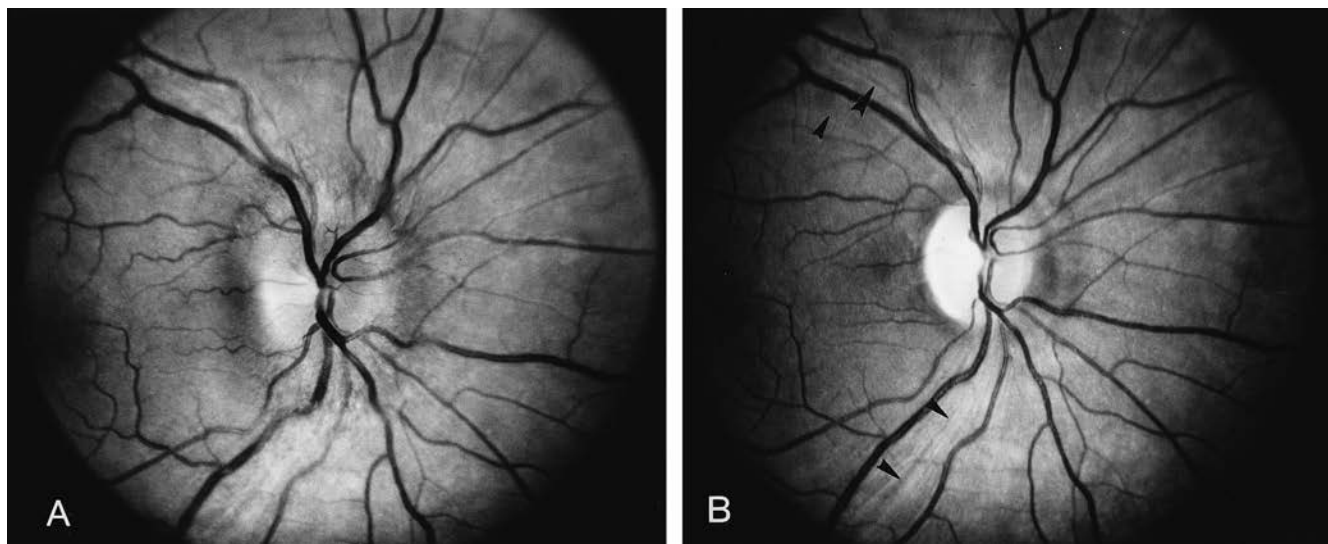


Figure 6.11. Optic atrophy after acute, anterior optic neuritis. *A*, Mild optic disc swelling. Visual acuity is 20/400, and there is a central scotoma in the right eye. *B*, Two months after initial visual loss, disc swelling has resolved. Visual acuity has returned to 20/20, but the optic disc now shows temporal pallor, and there are defects in the peripapillary retinal nerve fiber layer (*arrowheads*).

still complain of difficulties with vision. As noted above, it is important to realize that many patients with optic neuritis whose visual acuity returns to normal (20/20 or better) nevertheless have clinical and laboratory evidence of significant optic nerve dysfunction (89,90,135), particularly when using tests of color vision (60,107,197) or measuring the VEP (206,208,211,212). Such patients will state that their vision is "not right" or that it remains "fuzzy." This difficulty with fine visual function may cause disability in some patients with resolution of optic neuritis who try to return to vocations requiring detailed visual function.

In the ONTT, a questionnaire was completed after 6 months by 382 of the patients (213). Persistent visual symptoms were reported by 56% of the patients. Among the 215 patients who perceived their vision in the eye affected by optic neuritis to be somewhat or much worse than before optic neuritis, visual acuity was nevertheless normal in 66%, contrast sensitivity in 30%, color vision in 55%, and the mean deviation of the visual field in 58%.

One cause of symptoms in these patients is probably related to subtle abnormalities in the visual field that may be difficult to detect with standard static perimetry in which patients experience abnormally rapid disappearance of focal visual stimuli and abnormally rapid fatigue in sensitivity. Patients in whom such abnormalities are present typically complain that when they look at something, it appears as if they have "holes" in their field of vision. If they continue concentrating on the object, some holes fill in, whereas new holes appear elsewhere in the field. Ellenberger and Ziegler (183) called this phenomenon the "Swiss cheese" visual field. It occurs not only in optic neuritis but also in other types of optic neuropathy.

Uhthoff's Symptom

Following an episode of optic neuritis, some patients describe transient visual blurring during exercise, during a hot bath, or during emotional stress (3,214–216). This phenomenon, called Uhthoff's symptom, is most common in patients with other evidence of MS but is also experienced by otherwise healthy patients after optic neuritis, by patients with Leber's optic neuropathy (217), and by patients with optic neuropathies from other causes (218). Some patients with Uhthoff's symptom note that their visual symptoms improve in colder temperatures or when drinking cold beverages. Indeed, we have a patient who reported that she kept ice and ice water at her bedside at all times. Whenever she wanted to read something or see clearly at distance, she would place an ice cube in her mouth or drink the ice water. She would then see clearly for several minutes or longer. On examination, her visual acuity improved from 20/400 to 20/40 in both eyes about 2 minutes after she placed an ice cube in her mouth. Scholl et al. (219) reported that when Uhthoff's symptom was present following optic neuritis, MR imaging of the brain was more likely to be abnormal and MS was more likely to develop. Uhthoff's symptom was reported after 6 months by about 10% of patients enrolled in the ONTT (213).

Although the patient studied by Goldstein and Cogan

(216) developed visual blurring during exercise despite a stable body temperature, most investigators agree that Uhthoff's symptom is most often associated with an elevation of body temperature (220). Two major hypotheses regarding this phenomenon are that elevation of body temperature interferes directly with axon conduction and that a rise in body temperature releases a chemical substance that interferes with conduction. Although several studies appear to demonstrate humoral factors capable of blocking nerve conduction (221–224), Zweifach (225) examined three patients with Uhthoff's symptom and found that blood removed from the patients at the time of maximal visual loss and readministered in the normothermic state did not reproduce the symptom. Tasaki (226) postulated a safety factor for nerves that he defined as the ratio of the action current generated by the nerve impulse to the minimum amount of current needed to maintain conduction; if the safety factor is decreased by injury, disease, or pharmacologic insult, a small additional insult could be sufficient to block conduction. Davis (227) and Rasminsky (228), using severely demyelinated peripheral nerve fibers, found that reversible conduction block can be induced by increasing the temperature as little as 0.5°C. Increased temperature increases the threshold for excitation for a nerve and also decreases the duration of the action, presumably reducing the safety factor in the nerve. It is likely that this direct temperature effect explains Uhthoff's symptom in most cases (229); however, although temperature elevation may be the primary factor responsible for Uhthoff's symptom, it may not be the only factor. Persson and Sachs (230) studied the effects of physical exercise on the pattern-reversal VEP in patients with MS, with and without a history of Uhthoff's symptom, and in normal subjects. These investigators found that physical effort produced a short-lasting reduction in the amplitude of the VEP and in the visual acuity of patients with MS with a history of Uhthoff's symptom; however, there was no significant change observed in the already prolonged latency of VEP. In patients with MS without a history of Uhthoff's symptom, and in normal subjects, neither visual acuity nor any aspect of the VEP was affected. The authors interpreted their results as an indication that Uhthoff's symptom results from a reversible conduction block in impulse transmission by demyelinated nerve fibers, supporting the work of Davis (227) and of Rasminsky (228); however, changes in oral temperature were very slight or nil in these patients. Selhorst et al. (231) studied the monocular pattern-reversal VEP in four patients with MS, well-compensated optic neuritis, and Uhthoff's symptom during and after peddling a lightly loaded ergometer bicycle. These investigators found no change in either oral or tympanic membrane temperature at a time when visual acuity became reduced and the VEP showed absence or reduction in amplitude of the P2 wave. Because all patients studied showed a slight decline in venous pH and a rise in lactic acid, Selhorst et al. (231) postulated that the demyelinated nerves may be susceptible not only to temperature changes but also to metabolic changes in the environment. Uhthoff's symptom can occur not only in patients who have experienced an attack of acute optic neuritis but also in patients who have chronic or subclinical optic neuritis (discussed later).

Neurologic Prognosis

Both retrospective and prospective studies have been performed in an effort to determine the prognosis for the development of MS in patients who experience an attack of acute optic neuritis (232). Retrospective studies provide figures ranging from 11.5% to 85% in both adults (28,32,82,83,118,197,315) and children (35,233–235). The marked discrepancy in these figures may result from biases common to almost all retrospective studies, including criteria for diagnosis of MS and optic neuritis, the nature and length of follow-up, and the care with which neurologic and visual testing was performed. Most prospective studies seem to support higher figures, indicating that the risk of developing MS in patients who experience an attack of acute optic neuritis is only about 30% in patients followed 5–7 years after the attack of optic neuritis (51,135) but eventually increases to about 75% in women and 34% in men with longer follow-up (102,130,236). Rodriguez et al. (33) reported that among 95 incident cases of optic neuritis occurring in Olmstead County, the estimated risk of MS was 39% by 10 years, 49% by 20 years, 54% by 30 years, and 60% by 40 years. Again, the risk of MS was higher in women than in men in this study. The reason for the apparent difference in neurologic prognosis between women and men is unclear, particularly since there seems to be no difference in the clinical disease or its course between the two sexes (10). The average time interval from an initial attack of optic neuritis until other symptoms and signs of MS develop varies considerably; however, most authors find that the majority of persons who develop MS after an attack of optic neuritis do so within 7 years of the onset of visual symptoms (32,96,102,236). Even patients who live in tropical and subtropical regions of the world have a substantial risk of developing MS after an attack of isolated optic neuritis (237), although this risk may be lower in Japan (238) and in some Latin American countries (239). It therefore seems appropriate to consider most cases of optic neuritis a limited form of MS (240) and to counsel patients appropriately (147,241–243).

As noted above, there appear to be certain risk factors that increase the likelihood that a patient with isolated optic neuritis will eventually develop MS. Compston et al. (125) found that positive typing for HLA BT101, winter onset of the initial attack of optic neuritis in BT101-positive patients, and recurrent attacks of optic neuritis were associated with an increased incidence of MS. Frick and Stickl (113) reported that the presence of MBP in the CSF of a patient with otherwise isolated optic neuritis and no history of previous neurologic symptoms or signs nevertheless is highly predictive of the development of MS in the future, a conclusion supported by the findings of Söderström et al. (114) of anti-MBP and anti-MBP peptide antibody-secreting cells in the CSF of patients with both acute optic neuritis and MS. Multiple oligoclonal bands in the CSF of a patient with isolated optic neuritis also seems to be highly predictive of the future development of MS (94,115–118).

Among patients with isolated optic neuritis enrolled in the ONTT, a positive family history of MS, a history of previous neurologic symptoms, and a history of a previous attack of

optic neuritis in the fellow eye increased the risk of the development of MS; however, at least one lesion in the periventricular white matter on MR imaging, a phenomenon noted in 30–70% of patients with isolated optic neuritis (7,12,145,146), was the most significant risk factor associated with an increased likelihood of developing MS (13,23).

Deckert-Schlüter et al. (119) detected increased concentrations of several different cytokines in the serum, CSF, or both of 20 patients with isolated optic neuritis who eventually developed MS, and Link et al. (120) reported similar results. The presence of these substances suggests an activation of the T lymphocytes of the immune system both within and outside the CNS, and suggests that either their presence alone or their particular concentration may be used to predict the eventual development of MS in these patients.

Some authors believe that patients in whom optic neuritis is the initial manifestation of MS tend to have a more benign course than patients in whom MS presents with no visual symptoms and signs (51,82,244–247). Other investigators, however, have found no difference in the eventual outcome of the disease (248–251).

In the ONTT (23), the 10-year risk of MS was 38%. Patients ($n = 160$) with one or more typical lesions on the baseline brain MR scan had a risk of 56%; those with no lesions ($n = 191$) had a risk of 22% ($P < 0.001$). The presence of more than one lesion did not appreciably increase that risk (23–26). Even when brain MR lesions were present, over 40% of patients did not develop clinical MS after 10 years. The 10-year risk of development of MS, based strictly on conventional clinical criteria, was 38%, compared with a 5-year risk of 30% (22–26). Thus, although these patients continued to develop MS with each passing year, most did so within the first 5 years after the initial episode of optic neuritis. These results have applicability not only to optic neuritis but also to patients presenting with a first demyelinating event of the brain stem or spinal cord because the three presentations share a common pathogenesis and have been reported to have similar risks for MS (83). The finding, in the ONTT cohort of patients, of a 38% 10-year risk of MS after optic neuritis is similar to that of several prior reports (33,102,236) and lower than that of other reports (83,130,252), all of which had smaller sample sizes. Differences in risk estimates across studies can also be attributed to differences in patient inclusion criteria, retention rates, and diagnostic criteria for MS.

The most potent predictor of MS in the ONTT was the presence of white matter lesions on the baseline brain MR scan (23). The presence of one such lesion at least 3 mm in diameter more than doubled the 10-year risk of MS (from 22% to 56%). However, the presence of one or more lesions did not signify that the patient was destined to develop MS. Among patients with brain MR lesions, the 10-year probability of remaining free of MS was 44%. Conversely, the absence of brain MR lesions did not eliminate the risk of developing MS; in the absence of any lesions, the 10-year probability of MS was 22%.

There are certain gender and optic disc appearance characteristics that help predict whether a patient with optic neuritis

Table 6.1
Gender and Optic Disc Appearance Combined as Predictors of Multiple Sclerosis in Patients with No Brain Lesions on MR Imaging at Study Entry

	N	Number Developing Multiple Sclerosis	10-Year Risk of Multiple Sclerosis ^a	Hazard Ratio (95% CI) ^b
Female				
Disc normal	85	26	31%	1.0
Disc edema	57	9	16%	0.42 (0.20–0.89)
Male				
Disc normal	25	3	15%	0.36 (0.11–1.19)
Disc edema	24	1	5%	0.14 (0.02–1.00)

^a Kaplan-Meier estimate of cumulative probability.

^b From proportional hazards model.

(From Optic Neuritis Study Group. Long-term brain MRI changes after optic neuritis in patients without clinically definite multiple sclerosis. *Arch Neurol* 2004 [in press].)

will subsequently develop MS (Table 6.1) (26). In the ONTT, among patients with one or more brain MR lesions, no demographic characteristics or clinical features of the optic neuritis were useful in further defining the risk (23–26). But among patients without brain MR lesions, the risk was three times lower in males than in females, consistent with the well-documented lower prevalence of MS in males than in females and consistent with studies conducted prior to the availability of brain MR imaging. The risk was also lower when the optic neuritis was associated with a swollen rather than a normal optic disc. Among females with no brain MR lesions, those with optic disc edema had a risk of MS that was half as great as those without optic disc edema. The risk of MS when no baseline brain MR lesions were present was zero among the small group of patients who had any one of the following findings: no light perception vision in the affected eye, optic fundus findings including severe optic disc edema, peripapillary hemorrhages, retinal exudates, or the absence of periocular pain (24–26). Thus, when there are no brain MR lesions, the presence of any of these clinical features appears to predict a very low risk of MS. In patients who bear these atypical features, the optic neuritis may not be part of a multifocal demyelinating CNS illness.

The difference in the risk profile between patients with and without brain MR lesions is not surprising (24–26). Patients with MR lesions already have imaging evidence of disseminated disease, the pathogenesis of which is almost certainly related to MS. Therefore, there is no reason to expect to be able to identify true risk factors for future development of MS. On the other hand, the group of patients with optic neuritis and a normal brain MR scan likely includes a subgroup destined to have MS and another subgroup not destined to have MS.

With regard to the predictive role of MR lesions, the only study comparable to the ONTT (252,253) enrolled 131 patients with an acute demyelinating event in which optic neuritis constituted half of the cohort. Ten-year follow-up was achieved in 81 (62%) patients and 12- to 16-year follow-up

in 72 (55%). After 10 years, MS was present in 83% of those with entry MR lesions and in 11% of those without entry MR lesions. Differences between these results and the ONTT may be related to the former study's smaller sample size and lower follow-up rate. That study found, as the ONTT/LONS did, that once there is at least one MR lesion, an increasing number of lesions does not appreciably amplify the long-term risk of MS.

The eligibility criteria of the ONTT/LONS were sufficiently broad that the results should be applicable to most patients presenting with optic neuritis as a first demyelinating event. Having incomplete data for 13% of the original cohort was unlikely to be a source of appreciable bias. However, because the patients with incomplete follow-up had a lower prevalence of brain MR scans with one or more lesions than did the patients with complete follow-up, the computed 10-year risk of MS could be a slight overestimate.

The results of the ONTT/LONS long-term follow-up are important to the clinician in several respects (23,650). First, they reaffirm the prognostic value of a brain MR scan performed at the time of a first episode of optic neuritis. The presence of a single brain MR white matter lesion of at least 3 mm in diameter markedly increases the risk of developing MS; higher numbers of lesions do not appreciably increase that risk. Second, they establish that even when MR lesions are present, clinically defined MS does not develop within 10 years in over 40% of patients. Third, the results highlight the importance of an ophthalmologic examination for patients whose brain MR scan is normal, because ophthalmoscopy can identify features (severe optic disc swelling, hemorrhages, and exudates) associated with a very low risk of developing MS. This natural history information is a critical input for estimating a patient's 10-year MS risk and for weighing the benefit of initiating prophylactic treatment at the time of optic neuritis or other first demyelinating events in the CNS.

Recurrent Optic Neuritis

Patients in whom idiopathic acute optic neuritis occurs, whether anterior or retrobulbar, may experience a recurrence in the eye at a later date or may experience a similar attack in the fellow eye. Recurrent attacks occurred in 11.3% of the patients reported by Marshall (68), in 14% of the patients studied by Classman and Phillips (254), in 20.6% of the patients in the series reported by Lynn (197), in 24% of Hutchinson's patients (83), and in 16.7% of the patients studied by Perkin and Rose (39). The 10-year ONTT recurrence rate of 35% was similar to that reported by Cohen (42%) but higher than that reported in other studies with extended follow-up such as those by Bradley and Whitty (18%), Hutchinson (24%), and Rodriguez (16%). Although it has been believed that the likelihood of visual acuity returning to normal decreases with each recurrence (83,197), the experience of the ONTT has shown that long-term visual function is generally good despite this recurrence rate.

Management Recommendations for Patients with Presumed Acute Optic Neuritis

In a patient with typical features of optic neuritis, a clinical diagnosis can be made with a high degree of certainty with-

out the need for ancillary testing. Brain MR imaging is a powerful predictor of the long-term probability of MS (for at least the first 10 years); this information, as outlined above, when coupled with clinical trial outcomes suggesting significant efficacy of early immunomodulatory therapy in patients with clinically isolated demyelinating syndromes and abnormal MR scans, should be helpful to clinicians in planning long-term therapy as prophylaxis.

Based on the results of the ONTT, it is reasonable to consider treatment with intravenous methylprednisolone, 250 mg q6h for 3 days or 1 g/day in a single dose \times 3 days, followed by a 2-week course of oral prednisone, 1 mg/kg/day, with a rapid taper for patients with acute optic neuritis, particularly if brain MR imaging demonstrates multiple signal abnormalities in the periventricular white matter consistent with MS, or if a patient needs to recover vision faster than the natural history of the condition. Since the potential beneficial effects on the visual and neurologic courses are short term and not lasting, prescribing no treatment is also a reasonable approach. However, oral prednisone alone in standard dosages (e.g., less than 1 mg/kg/day) should be avoided. As noted above, the visual recovery is excellent without treatment and the long-term vision is not any better when corticosteroids are prescribed.

Pathology

There is little material available regarding the pathologic findings in the optic nerves of patients with acute isolated optic neuritis. What pathology exists has been in optic nerves from patients with acute MS and shows active demyelinating plaques similar to those in the brain (255–258). In such plaques, the inflammatory response is marked by perivascular cuffing, T cells, and plasma cells. Initially there is swelling of nerve tissue in the area of demyelination, following which the myelin sheaths begin to break down into fat droplets. As degeneration proceeds, the nerve fibers themselves are destroyed, with the degeneration occurring in both the proximal and distal segments. As the inflammatory reaction subsides, fat-laden macrophages become numerous, and there is glial proliferation. Gartner (259) examined 14 eyes from 10 patients in whom a diagnosis of MS had been made clinically and confirmed at postmortem examination. An attack of optic neuritis had been diagnosed during life in only two of the cases, and all cases were in an advanced state of the disease by the time of their death. Gartner (259) found only optic atrophy, predominantly in the temporal portion of the nerve. Although the papillomacular bundle was primarily affected, the peripheral fibers were also damaged. There was an increase in cellularity of the nerve, especially with respect to glial cells. The surface of the optic discs showed extensive gliosis, and the blood vessels on and near the disc were thickened and sclerosed. The retina showed atrophy of the nerve fibers and ganglion cells, most readily observed at the macula. de Preux and Mair (260) described the ultrastructure of the optic nerves of a patient who developed Schilder's disease and bilateral demyelinating optic neuritis. Both nerves contained areas of complete, as well as partial, demyelination. No oligodendrocytes were present in the areas of

complete demyelination, and the naked axons contained swollen, vacuolated mitochondria in these areas. There were some oligodendrocytes in areas of partial demyelination, and axon architecture was maintained in these regions. In all areas, there was an excess of fibrous astrocytes.

Several experimental animal models of demyelinating optic neuritis can be produced for study of pathologic changes and other features of the condition. Rao et al. (261) produced experimental allergic optic neuritis in guinea pigs by sensitization with isogenic spinal cord emulsion in complete Freund's adjuvant. The optic neuritis produced in this manner has two major forms: (a) a "retrobulbar" form, with a diminished pupillary response to light despite a normal-appearing retina and optic disc, and (b) a "neuroretinitis," with a diminished pupillary response associated with hyperemia and swelling of the optic disc and edema of the peripapillary retina. Histopathologic study of animals with retrobulbar neuritis reveals a mononuclear cell infiltrate localized to the retrobulbar portion of the optic nerve and chiasm with multiple foci of axial and periaxial demyelination. Similar pathologic changes are present in animals with experimental neuroretinitis, but in these animals, the lesions are located just behind the lamina cribrosa, with marked swelling of axons in the prelaminar portion of the optic nerve, identical with that seen in human disc swelling. In addition, Hayreh et al. (262) observed acute optic neuritis with variable degrees of optic disc swelling in adult rhesus monkeys with experimental allergic encephalomyelitis. Histopathologic examination of the optic nerves of these animals revealed inflammatory infiltrates, extensive demyelination, and axon degeneration, without inflammation in the retina or optic nerve head. Okamoto (263) observed macrophages in the subarachnoid space in rabbits with experimental allergic optic neuritis. He suggested that these macrophages may digest the myelin debris in the subpial spaces of the affected optic nerves. It is likely that these models will facilitate future studies of pathogenetic mechanisms of demyelinating diseases of the human optic nerve (264).

Sergott et al. (265) injected the serum from 17 patients with MS and 3 patients with isolated optic neuritis into the optic nerves of guinea pigs. These investigators then sacrificed the animals and examined the optic nerves. They found demyelination in the optic nerves injected with the serum from 12 of the 17 MS patients and in the optic nerves injected with serum from all 3 of the optic neuritis patients. There were areas in which axons were relatively spared within the areas of demyelination, similar to those seen in the brains of patients with MS.

It is believed that demyelination of nerve fibers leads to complete conduction block, slowing of conduction, or a failure to transmit a rapid train of impulses (256,266,369).

Relationship of Optic Neuritis to MS

Optic neuritis occurs in about 50% of patients with MS and in about 20% it is the presenting sign (39). Available evidence suggests that the pathogenesis of isolated optic neuritis is no different than that of MS in general. In fact, a strong case can be made for optic neuritis being a *forme*

fruste of MS, based on similarities between the two in incidence, CSF findings, histocompatibility data, results of MR imaging, and family history as well as other features (240). For instance, both isolated optic neuritis and MS are more common in northern latitudes and in females compared with males. Immunologic changes in the CSF similar to those in MS may also occur in optic neuritis (267) (discussed previously). Feasby and Ebers (115) found that 75% of 36 patients with isolated optic neuritis had abnormalities on somatosensory evoked potentials, brain stem evoked potentials, or CSF protein electrophoresis, and Sanders et al. (251) found that 67% of 30 patients had similar abnormalities. As noted above, 25–60% of patients with isolated optic neuritis have changes in the brain on MR imaging consistent with areas of demyelination. Ebers et al. (268) described 10 patients with isolated optic neuritis who had a family member with MS, which also suggests an etiologic association between the two, and similar HLA types (108,125) are also present in both optic neuritis and MS.

Although Kurland et al. (269) did not find age at onset of optic neuritis to be a risk factor in the eventual development of MS, and Hely et al. (135) reported that there was no difference in the age range of those patients with optic neuritis who developed MS compared with those who did not, most studies indicate that the younger the age at which optic neuritis develops, the greater the risk for the development of MS. Bradley and Whitty (82) first suggested that the risk of MS increased with increasing age, but they did not provide any supportive data. Kahana et al. (30), however, reported that 39% of patients who were less than 39 years old when they had an initial attack of optic neuritis eventually developed MS, compared with 21% of patients who eventually developed MS after they developed optic neuritis when they were older than 40. Mapelli et al. (270) reported similar findings. These investigators reported that 31% of 26 patients who were less than 40 years of age when they experienced a first attack of optic neuritis eventually developed MS, compared with only 14% of 14 patients who were older than 40 years of age when they experienced their first attack. Rizzo and Lessell (236) reported that the relative risk for MS increased by 1.7 for each decade less than 54 years. Like Bradley and Whitty (82), Sandberg-Wollheim et al. (102) suggested that younger age at onset of optic neuritis was a risk factor in the development of MS but provided no supportive data. Age at onset was not found to be statistically related to ultimate development of MS in the ONTT/LONS (24–26).

There is some controversy as to whether gender is a risk factor for the development of MS after optic neuritis. Some investigators report no difference in the incidence of MS after optic neuritis (30,82,237,270). Rodriguez et al. (33) also found no gender differences in their study: 38% of 26 men and 40% of 66 women developed MS at 10 years after onset of optic neuritis. On the other hand, Hely et al. (135) reported that the relative risk of MS was almost three times greater in women compared with men. Rizzo and Lessell (236) reported that MS developed in 69% of 47 women and 33% of 20 men within 14.9 years of their initial attack of optic neuritis, and Sandberg-Wollheim et al. (102) reported

that 46% of 54 females and 28% of 32 men developed MS within a mean of 12.9 years after their attack. In the ONTT with 10 years of follow-up, no gender difference in risk for development of MS was observed (23) when the presenting MR scan was found to be abnormal. In contrast, among the 191 patients without MR lesions, certain features did alter the risk of MS (Table 6.1), with the risk of MS lower in males than in females.

Kurland et al. (269) found no difference between whites and nonwhites in his comparison of United States servicemen, but this study had low power to observe such a difference if, indeed, one existed. Alter et al. (271) compared the Asian and Caucasian populations in Hawaii and found no significant differences in the rate of development of MS after optic neuritis between the two races. Although the 2-year data from the ONTT suggested that Caucasians are at higher risk than African-Americans (13), results from this study at 10 years had insufficient statistical significance to comment on this variable. Among Caucasians in the study, 14% of 331 developed MS within 2 years compared with 5% of 58 non-Caucasians, most of whom were African-American. This difference was still present at 4-year follow-up (20).

Kurland et al. (269) found neither birthplace nor residence to be a risk factor for MS in a study of U.S. veterans with optic neuritis, but the study by Kahana et al. (30) of optic neuritis in Israel found that MS developed in 23% of 35 patients born in Europe, 32% of 25 patients born in Asia or Africa, and 44% of 25 patients born in Israel. There is increasing epidemiologic evidence suggesting that the place of residence in regard to distance from the equator during the first 15 years of life is a major risk factor for the development of MS after optic neuritis. Indeed, it seems clear that persons who migrate from one country or region to another during childhood (i.e., under 15 years of age) take on the risk of the country of destination (272–274). It is less clear whether persons who migrate later in life retain the risk of their country of origin or take on the risk of their new place of residence.

Kurland et al. (266) and Bradley and Whitty (82) reported that season of onset of optic neuritis was not a risk factor for the subsequent development of MS but provided no data. Sandberg-Wollheim et al. (102), however, reported that MS developed in 43% of 42 patients with onset of optic neuritis between October and March, compared with 29% of 44 patients with onset of optic neuritis between April and September.

There are few data available on the features of optic neuritis that relate to the subsequent risk of MS. Kurland et al. (266) did not find any aspects of optic neuritis to be risk factors; however, Bradley and Whitty (82), without any supporting data, reported that optic disc appearance and severity of visual loss were not risk factors for MS but that the presence of pain and a typical visual field defect were risk factors. Kahana et al. (30) found that MS developed in only 13% of 45 patients with anterior optic neuritis, compared with 60% of 30 patients with retrobulbar optic neuritis.

Data from the ONTT confirm the findings of Kahana et al. (30) that the presence of severe disc swelling reduces the likelihood that MS will develop, particularly when the pa-

tient also has normal brain MR imaging (13,23–26). In the ONTT, among the 22 patients with severe disc swelling and normal brain MR imaging at baseline, none developed clinical signs of MS in 10 years of follow-up. In patients of both genders without brain MR lesions, MS did not develop in any patients whose visual loss was painless ($n = 18$) or total (no light perception, $n = 6$) or in those who had ophthalmoscopic findings of severe disc swelling ($n = 22$), hemorrhage of the optic disc or surrounding retina ($n = 16$), or retinal exudates ($n = 8$) (Table 6.1). In the 191 patients without MR lesions, the risk of MS was lower when the optic disc was swollen (anterior optic neuritis, papillitis) than when it was not swollen (retrobulbar neuritis). Among females, the risk of MS was halved when optic disc swelling was present. Among males, only 1 of 24 patients with optic disc swelling developed MS. One hundred seventy-nine of the 191 patients with no brain MR lesions had no prior history of neurologic symptoms or optic neuritis in the fellow eye and would be considered to have monofocal optic neuritis; their 10-year risk of MS was 20%.

In most series, adult patients with bilateral simultaneous optic neuritis are said to have the same risk of developing MS as patients with unilateral optic neuritis (82,269,275); however, Hutchinson (83) found an increased incidence of MS in patients who developed bilateral optic neuritis either simultaneously or whose second eye became affected within 2 weeks of the first eye. In the ONTT/LONS, when the criteria for MS were expanded to include the occurrence of optic neuritis in the fellow eye, the 10-year risk of MS was 45%: 31% in patients with no baseline brain MR lesions and 60% in patients with one or more lesions (23). Most authors believe that ultimate visual acuity after optic neuritis has no bearing on the subsequent development of MS (23–26, 39,82).

Although it might be expected that recurrent optic neuritis would increase the risk for MS, the reports on this provide mixed results, with some authors reporting an increased risk (33,83,102,267) and others not (130,236). Data from the ONTT do not show a strong relationship between recurrent optic neuritis and the early development of MS (13,20,23–26).

Evidence of immunologic dysfunction (e.g., oligoclonal banding) in the CSF is common in patients with MS. Whether the presence of these abnormalities in patients with clinically isolated optic neuritis increases the risk that such patients will develop MS in the future is controversial (discussed previously). Nikoskelainen et al. (267) studied 48 patients with isolated optic neuritis, 27 (56.3%) of whom developed probable MS during a 7- to 10-year follow-up. Although increased relative IgG, abnormal electrophoresis, or an abnormal ratio of measles antibody titer in the serum compared with the CSF at the time of presentation correlated with the development of clinical signs of disseminated disease, 6 of 11 (54.5%) patients with normal CSF values on every laboratory study developed MS. Stendahl-Brodin and Link (117) reported that 9 of 11 (81.8%) patients with isolated optic neuritis but with abnormal CSF developed MS within a mean follow-up of 11 years. During this period only 1 of 19 (5.3%) similar patients with normal CSF developed

MS. Anmarkrud and Slettnes (118) reported that 15 of 19 (78.9%) patients with optic neuritis who had abnormal CSF but only 1 of 10 (10%) patients with optic neuritis and normal CSF developed MS within a mean follow-up of 5.8 years. Sandberg-Wollheim et al. (102) reported that 26 of 55 (47.3%) patients with optic neuritis who had abnormal CSF and 7 of 31 (22.6%) patients with normal CSF developed MS over a mean follow-up of 12.9 years. These studies indicate that 25–50% of patients with isolated acute optic neuritis and abnormal CSF remain free of neurologic manifestations of MS for many years (if not for life), whereas 10–50% of patients with optic neuritis and normal CSF nevertheless develop other manifestations of MS during the same period. In view of these findings, it seems likely that CSF abnormalities alone are not a primary risk factor in determining whether a patient with acute optic neuritis eventually develops clinical evidence of disseminated demyelination.

No long-term study has evaluated the added value of the detection of CSF abnormalities in conjunction with MR imaging of the brain; however, data from the ONTT suggest that the presence of CSF abnormalities has little predictive value for the development of MS over and above the powerful predictive value of MR imaging (discussed previously) (13,93,276,277).

The predictive value of CSF oligoclonal banding for the development of CDMS within 5 years after optic neuritis was assessed in 76 patients enrolled in the ONTT. In the patients followed in the ONTT for 5 years, the following findings were noted:

1. Oligoclonal bands were present in 50% of the patients (73% of the 37 patients with abnormal brain MR and 28% of the 39 patients with normal brain MR).
2. CDMS developed within 2 years in 29% of the 38 with oligoclonal bands and in 5% of the 38 patients without oligoclonal bands ($P = 0.015$).
3. The association of oligoclonal bands and the development of CDMS was attenuated when adjusted for brain MRI (P [adjusted for MRI] = 0.09).
4. There were 11 patients with normal brain MR scans who had oligoclonal bands, two of whom had developed CDMS by 2 years (93).

CDMS developed within 5 years in 22 (29%) of the 76 patients: in 16 (42%) of the 38 patients with oligoclonal bands present and in 6 (16%) of the 38 patients without bands (OR = 3.88; 95% CI = 1.18, 13.86; $P = 0.02$). Among the 54 patients not classified as CDMS, 5-year follow-up was complete for 50 (93%). The predictive value of CSF oligoclonal band assessment for the development of CDMS over and above that of brain MR imaging was apparent only among patients with no brain MR lesions at study entry. Among the 39 patients with normal brain MR imaging, CDMS developed in 3 of 11 (27%) patients with oligoclonal bands present but in only 1 of 28 (4%) without oligoclonal bands ($P = 0.06$). In contrast, among the 37 patients with abnormal brain MR imaging, CDMS developed in 13 of 27 (48%) with oligoclonal bands and in 5 of

10 (50%) without oligoclonal bands ($P = 1.00$). The positive predictive value of oligoclonal bands was 42% and the negative predictive value was 84%. Among the 39 patients with normal brain MR imaging, the positive and negative predictive values were 27% and 96%, respectively, whereas among the 37 patients with abnormal brain MR imaging, the values were 48% and 50%, respectively.

Brain MR imaging has been demonstrated to be a strong predictor of CDMS among patients with monosymptomatic optic neuritis. In the ONTT there was a 51% 5-year incidence of CDMS in patients who had abnormal brain MR imaging at the time of optic neuritis compared with a 16% incidence in those with normal brain MR scans (22). These results indicate that performing a lumbar puncture to detect oligoclonal bands is not of added value for predicting the five-year risk of CDMS in patients who have abnormal brain MR scans at the time of development of monosymptomatic optic neuritis. However, the results suggest that oligoclonal band testing may be helpful in the risk assessment of optic neuritis patients with normal brain MR scans.

That the value of CSF analysis would depend on the brain MR findings was not felt to be surprising (277). Patients with abnormal brain MR scans already have morphologic evidence of disseminated disease, and as such it is expected that most of these patients will eventually develop additional neurologic events sufficient for a diagnosis of CDMS. Therefore, there is no reason to expect that a CSF analysis would be predictive of MS among these patients. The group of patients with optic neuritis and normal brain MR imaging likely includes a subset of those destined to have MS and a subset of those who may have optic neuritis unassociated with MS. Among these patients, the finding of oligoclonal bands in the CSF does appear to increase the likelihood that CDMS ultimately will be diagnosed. Additionally and perhaps more importantly, the absence of oligoclonal bands in the CSF makes the development of CDMS within 5 years unlikely. Although the number of patients in the ONTT was too small for definitive conclusions with regard to the role of CSF analysis in the evaluation of patients with optic neuritis, according to the authors the results suggested that a lumbar puncture has limited value in patients with typical monosymptomatic optic neuritis who have demyelinating changes on brain MR imaging (277).

CHRONIC DEMYELINATING OPTIC NEURITIS

It was once stated that for all intents and purposes chronic optic neuritis does not occur. The reason for this dogmatic statement was that too many patients with mass lesions compressing the intracranial portion of the optic nerve were being diagnosed as having chronic optic neuritis, leading to delayed treatment of the underlying lesion with resultant permanent visual loss. Thus, the statement that chronic optic neuritis was never a tenable diagnosis was made in an effort to raise the consciousness of the majority of physicians to look for another, potentially treatable, cause of unilateral progressive optic neuropathy.

In fact, chronic optic neuritis not only occurs but is not uncommon. In any group of patients with MS, one can find

numerous patients who have no history of acute visual loss (painful or otherwise) but who nevertheless complain that the vision in one or both eyes is not normal and who have evidence of unilateral or bilateral optic nerve dysfunction (198,254,278–285). Such patients may complain of a static disturbance of vision, a slowly progressive loss of vision in one or both eyes, or, occasionally, a stepwise loss of vision unassociated with periods of recovery.

Some patients with MS complain of blurred or distorted vision even though visual acuity is 20/20 or better in both eyes. Such patients often are found to have evidence of chronic optic neuritis by clinical testing (e.g., color vision, visual fields, ophthalmoscopy) (Fig. 6.12), electrophysiologic testing (visual evoked responses), psychophysical testing (e.g., contrast sensitivity), or a combination of these methods (202,286–289). Regan et al. (202), for example, used sine wave gratings to test contrast sensitivity for narrow, broad, and intermediate-width bars in a group of 48 patients with MS and resolved optic neuritis. These investigators found that in 20 of the 48 patients with MS in whom Snellen acuity fell within normal limits, contrast sensitivity to gratings of broad and/or intermediate bar width was abnormally low, whereas sensitivity to narrow bars was normal.

Most patients with chronic unilateral or bilateral demyelinating optic neuritis develop visual symptoms after other signs and symptoms of MS have developed, and this is why the percentage of patients with MS and evidence of chronic progressive optic neuritis increases the longer the patients are followed (278,281). Nevertheless, slowly progressive visual loss or complaints of blurred or distorted vision are the first symptoms of the underlying neurologic disease in some patients (278,281). We are unaware of any treatment for chronic progressive demyelinating optic neuritis.

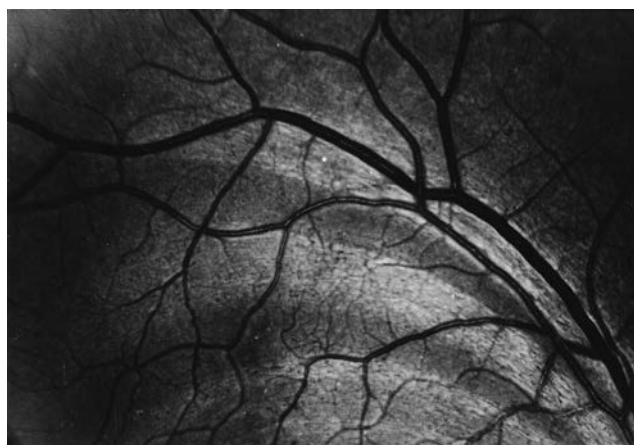

Figure 6.12. Retinal nerve fiber bundle defects in the right eye of a patient with bilateral chronic optic neuritis in the setting of multiple sclerosis. The patient had never experienced any episodes of acute loss of vision. Instead, she stated that her vision was slightly blurred and had been slowly worsening for the past 6–8 months. Visual acuity was 20/20 OU; however, color vision was slightly diminished in both eyes when tested using Hardy-Rand-Rittler pseudoisochromatic plates. Visual fields were normal by kinetic perimetry. There was no relative afferent pupillary defect. Both optic discs were mildly pale.

ASYMPTOMATIC (SUBCLINICAL) DEMYELINATING OPTIC NEURITIS

A substantial percentage of patients with MS have clinical or laboratory evidence of optic nerve dysfunction even though they have no visual complaints and believe their vision to be normal (194,198,282,283,285,290–292). The Optic Neuritis Study Group (7,11) found that 48% of patients with apparently unilateral optic neuritis and no history of previous optic neuritis in the contralateral eye nevertheless had an abnormal visual field unexplained by intraocular pathology in their asymptomatic, fellow eye. A substantial percentage of these eyes also had disturbances of visual acuity, color vision, and contrast sensitivity. These findings are consistent with the pathologic finding of demyelination in the optic nerves in patients who never had visual complaints during life (293). Miller (294) reported having evaluated a 21-year-old woman who came to the Wilmer Eye Institute for a routine examination. Visual acuity was correctable to 20/15 OU, color vision was normal, and kinetic perimetry was normal in both eyes using both a tangent (Bjerrum) screen and a Goldmann perimeter. Ophthalmoscopy revealed normal-appearing optic discs and peripapillary nerve fiber layer with no evidence of atrophy; however, the patient had a definite right relative afferent pupillary defect. It was decided to perform a CT scan. Shortly after the patient received an intravenous injection of contrast, she experienced a seizure and then had cardiorespiratory arrest from which she could not be resuscitated. Postmortem examination revealed no brain neuropathologic findings; however, the right optic nerve showed several small areas of demyelination and secondary atrophy consistent with a previous attack of subclinical optic neuritis (Fig. 6.13). Although this patient

had no evidence of MS, this case emphasizes that patients with and without evidence of MS may experience an attack of subclinical optic neuritis.

Evidence for optic neuritis in a patient who is visually asymptomatic may be clinical, electrophysiologic, psychophysical, or a combination of these (40,188,291,292). A careful clinical examination may reveal that despite having visual acuity of 20/20 or better, the patient has a subtle disturbance of color perception when tested with color plates, the Farnsworth-Munsell 100-Hue test, or some other method (8,60,126,187,188,190,295,296). There may be subtle visual field defects in one or both eyes detected using automated perimetry (194,297,298). A relative afferent pupillary defect may be present (299), or the patient may have subtle optic nerve or nerve fiber layer atrophy (191,286,300–302) (Fig. 6.14). In some cases, MR imaging shows enhancement of the optic nerve in question (Fig. 6.15).

Visually asymptomatic patients suspected of having or known to have MS may be shown to have disturbances of the visual sensory pathways by electrophysiologic testing. VEPs seem to be a particularly sensitive indicator of optic nerve and other visual sensory pathway disturbances in such patients (40,188,190,191,210,289,291,292,296,303–305).

Psychophysical tests of visual function, such as contrast sensitivity using a Pelli-Robson chart, Arden gratings, oscilloscope screen projections, or similar techniques, may reveal abnormalities in patients with MS and other disorders who are visually asymptomatic (40,58,189,192,202,283,287,289,291,292,306,307). Some psychophysical tests, such as measurements of sustained visual resolution (308) and assessment of chromatic, luminance, spatial, and temporal sensitivity (309–313), give similar results but are too complex

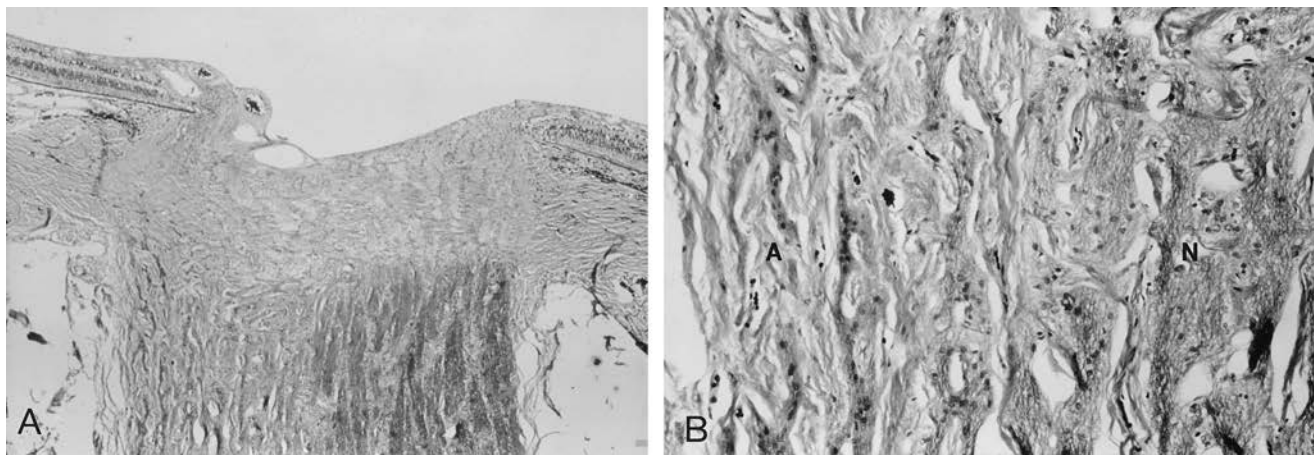


Figure 6.13. Pathology of probable subclinical optic neuritis. The patient was a 21-year-old woman with no previous history of systemic disease, neurologic disease, ocular disease, or trauma who was noted during a routine eye examination to have a right relative afferent pupillary defect. The patient had no visual complaints once her refractive error was corrected, and she had visual acuity of 20/15 OU, normal color perception in both eyes, using Hardy-Rand-Rittler pseudoisochromatic plates, and normal visual fields by kinetic perimetry. The patient subsequently suffered a fatal cardiac arrest during CT scanning, possibly related to a toxic reaction to contrast material. *A*, Section through the right optic disc and anterior portion of the right optic nerve shows segmental optic atrophy. Masson trichrome. *B*, Higher-power view of the right optic nerve shows the atrophic area (*A*) adjacent to normal nerve fiber bundles (*N*). Masson trichrome.

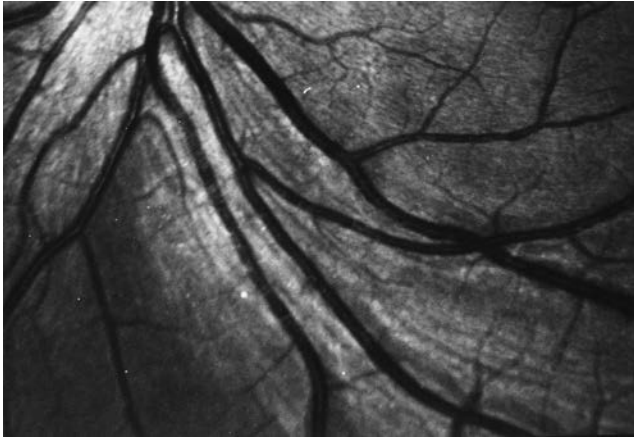


Figure 6.14. Retinal nerve fiber bundle defects in the asymptomatic eye of a patient with multiple sclerosis. Note numerous curvilinear dark streaks in the inferior arcuate nerve fiber bundle of the left eye.

and time-consuming to be of use in screening patients in clinical practice. Other tests, such as assessing the presence or absence of the Pulfrich phenomenon (314), and the “flight of colors” test (316–319), give little more information than one can obtain by an otherwise complete clinical and electrophysiologic examination.

NEUROMYELITIS OPTICA (DEVIC’S DISEASE)

The association of acute or subacute loss of vision in one or both eyes caused by acute optic neuropathy preceded or followed within days to weeks by a transverse or ascending myelitis was initially described by Allbutt (320) and later by Devic (321). Devic called the condition neuromyelitis optica, but it subsequently became known as “Devic’s dis-

ease” through the efforts of his pupil, Gault (322), who devoted his thesis to the subject.

Devic’s disease (neuromyelitis optica [NMO]) is an idiopathic inflammatory demyelinating disease of the CNS, characterized by attacks of optic neuritis and myelitis. The co-occurrence of optic neuritis and myelitis is seen in patients with MS, acute disseminated encephalomyelitis, systemic lupus erythematosus (SLE), and Sjögren’s syndrome; it can also occur in association with viral and bacterial infections (Table 6.2). Often, however, no underlying cause can be found. NMO may occur as a monophasic illness that is either fulminant and fatal or associated with varying degrees of recovery. A polyphasic course, characterized by relapses and remissions, also occurs (323).

Although Devic’s disease has been acknowledged as a unique type of optic neuritis for over 130 years, only recently has the pathologic appearance of this unique form of demyelinating process been more clearly elucidated. Much debate has revolved around whether NMO is a distinct disease, and what its relationship is to MS and other autoimmune disorders.

Epidemiology

NMO constitutes less than 1% of demyelinating disease in Western countries (324,325) and may be more prevalent than typical MS in Japan (326–329). NMO occurs primarily in children and young adults (330–336), but all ages may be affected, and the condition has been described in patients over 60 years of age (331,337,338). Both sexes are equally affected. It does not seem to be inherited, although McAlpine (339) reported its occurrence in monozygotic twins. Although most patients who develop this condition are otherwise healthy, NMO has been reported in patients with SLE (340,341), pulmonary tuberculosis (342–344), and after chickenpox (345,346). Hainfellner et al. (347) reported the case of a previously healthy 40-year-old woman who developed both NMO and myelinoclastic diffuse sclerosis (Schilder’s disease; discussed later). This case gives some credence to those who believe that both disorders are variants of MS.

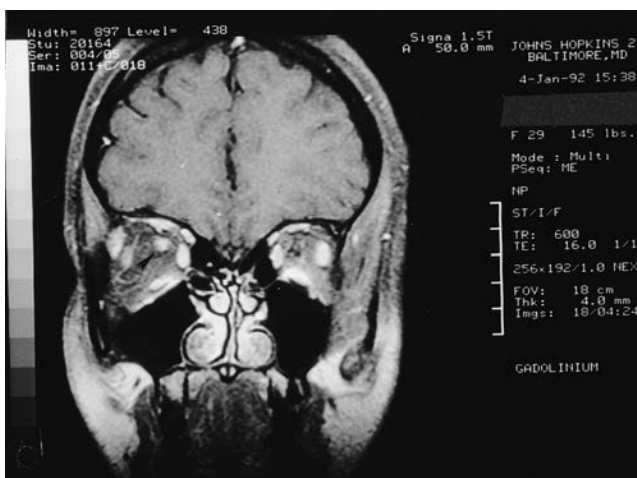


Figure 6.15. MR imaging in subclinical optic neuritis. T1-weighted coronal MR image after intravenous injection of paramagnetic contrast material in a 29-year-old woman with a history of left optic neuritis but no visual symptoms or signs of optic neuropathy in the right eye shows enhancement of the orbital portion of the right optic nerve (arrowhead).

Table 6.2
Neuromyelitis Optica and Associated Systemic Diseases

Autoimmune disorders
Systemic lupus erythematosus (340,341,526–530,635)
Sjögren’s syndrome (636–639)
P-ANCA (640,641)
Anticardiolipin antibody syndrome (642,643)
Mixed connective tissue disease (644,645)
Infectious disease
Tuberculosis (343,344,646)
Viral
HIV (511)
Varicella-zoster virus (345,346,369,647)
Epstein-Barr virus (370)
Toxins
Clioquinol (648–650)

Pathology

The brain, optic nerves, and spinal cord are affected by scattered lesions of demyelination that principally affect the white matter but may also affect the gray matter (348). In some cases, the cerebral cortex is only slightly affected or completely spared (349); however, the optic nerves and the spinal cord are invariably damaged (350). Both optic nerves are affected, although the degree of demyelination may be symmetric or asymmetric. Mandler et al. (349) described the pathologic findings in five cases of "neuromyelitis optica" and found unilateral demyelination in three of the five cases. All of these cases also showed evidence of a severe necrotizing myelopathy with thickening of blood vessel walls and absence of lymphocytic infiltration or demyelination in the spinal cord. In view of these unusual findings, we would question the diagnosis of NMO in these patients.

The spinal cord is extensively affected in all cases of NMO (350). Liquefaction and formation of cavities are common. There is widespread destruction of myelin sheaths, and axis cylinders may also be destroyed. There may be small areas of perivascular lymphocytes in both brain and spinal cord. Formation of glial tissue occurs in mild or moderately severe cases; however, it is not present or is minimal in fulminating, rapidly fatal cases.

Walsh (351) studied a patient with presumed NMO in whom scattered areas of destroyed tissue were present throughout the subcortex with more pronounced lesions in the occipital lobes, particularly in the region of the calcarine fissure. Small areas of demyelination were present in the basal ganglia, in the region of the red nucleus, and in perivascular locations throughout the mesencephalon. The optic nerves showed extensive demyelination, as did the optic chiasm. The spinal cord was most severely affected, with the lesions increasing in severity as they passed down the cord (352). Rare patients with NMO have pathologic evidence of a demyelinating peripheral neuropathy (353).

Although some investigators believe that NMO is simply a rare and aggressive variant of MS (329,347,354–356), there are several important differences in the pathologic findings in the two conditions (357,358). First, the cerebellum is almost never affected in patients with NMO, whereas it is frequently affected in MS. Second, excavation of affected tissue with formation of cavities is rare in MS but common in NMO, where there is often liquefaction of tissue. Third, gliosis is characteristic of MS but is almost always absent or minimal in NMO. Fourth, the arcuate fibers located in the cerebral subcortex are relatively unaffected in patients with NMO but are severely damaged in most patients with MS.

Lassmann et al. (359) proposed a classification for MS lesions based on molecular histopathologic findings from diagnostic biopsies and autopsies. The patterns I–IV of demyelination and inflammation are not closely linked to specific relapsing-remitting or progressive disease courses but may help us to understand the underlying immunologic and neurodegenerative mechanisms involved in lesion formation. These patterns may also be defining in the pathophysiologic process underlying NMO.

Although serologic and clinical evidence of B-cell autoimmunity has been observed in a high proportion of patients with NMO, the mechanisms that result in selective localization of inflammatory demyelinating lesions to the optic nerves and spinal cord are unknown. Lucchinetti et al. (360) provided detailed molecular studies on 82 lesions from nine autopsy cases of NMO using a similar classification, pathologically, as in their paper on the classification of MS lesions (359). Demyelinating activity in the lesions was immunocytochemically classified as early active (21 lesions), late active (18 lesions), inactive (35 lesions), or remyelinating (8 lesions) by examining the antigenic profile of MDPs with macrophages. The pathology of the lesions was analyzed using a broad spectrum of immunologic and neurobiologic markers, and lesions were defined on the basis of myelin protein loss, the geography and extension of plaques, the patterns of oligodendrocyte destruction, and the immunopathologic evidence of complement activation. The pathology was identical in all nine patients. Extensive demyelination was present across multiple spinal cord levels, associated with cavitation, necrosis, and acute axonal pathology (spheroids), in both gray and white matter. They found a pronounced loss of oligodendrocytes within the lesions. The inflammatory infiltrates in active lesions were characterized by extensive macrophage infiltration associated with large numbers of perivascular granulocytes and eosinophils and rare CD3+ and CD8+ T cells. A pronounced perivascular deposition of immunoglobulins (mainly IgM) and complement C9 neo-antigen in active lesions was associated with prominent vascular fibrosis and hyalinization in both active and inactive lesions. Lucchinetti et al. concluded that the extent of complement activation, eosinophilic infiltration, and vascular fibrosis observed in these Devic NMO cases was more prominent compared with that in prototypic MS, and that this supported a role for humoral immunity in the pathogenesis of NMO. Further, they felt that therapeutic strategies designed to limit the deleterious effects of complement activation, eosinophil degranulation, and neutrophil/macrophage/microglial activation were worthy of further investigation.

The animal model for MS, experimental autoimmune encephalomyelitis (EAE), may be of help in understanding which immunologic effector mechanisms, in particular autoantibodies, contribute to the pathogenesis of NMO. Augmentation of demyelination in EAE in the Lewis rat by circulating antibodies directed toward myelin oligodendrocyte glycoprotein (MOG) was described in the late 1980s (361). Since then a wide array of experimental models have focused on MOG as autoantigen and generated variants of EAE in rats and mice that more closely mimic the complex of pathologies seen in MS (362).

All the salient immunopathologic features of NMO are reproduced in Brown Norway (BN) rats immunized with MOG (363). MOG-induced EAE in this strain follows a fulminant clinical course associated with widespread demyelination and axonal injury. The lesion distribution also exhibits a preference for the optic tract and spinal cord similar to that seen in NMO. More importantly, the inflammatory

infiltrate contains large numbers of eosinophils and demyelination is associated with complement deposition. Recruitment of eosinophils into the CNS was not seen in demyelinating lesions induced by the cotransfer of MOG-specific antisera and encephalitogenic Th-1 MOG-specific T cells in BN rats, suggesting that eosinophil recruitment was dependent on a MOG-specific Th-2 T-cell response. However, it was not possible to identify a clear highly polarized MOG-specific Th-2 T-cell response. In particular, no enhanced secretion of the classical Th-2-associated cytokine IL-4 was observed and the MOG-specific antibody response included both Th-1-associated (IgG2b) and Th-2-associated (IgG1 and IgE) isotypes.

These findings demonstrate that even in inbred strains with a high susceptibility for Th-2-driven autoimmune responses, it is difficult to disentangle the effector pathways involved in lesion formation and ultimately tissue destruction. Cree (323) suggested that all we know about the molecular basis for the induction of this NMO disease model is that while the eosinophilic component is controlled by non-MHC genes, the intensity and pathogenicity of the antigen-specific autoimmune response is determined by multiple genes within the MHC. Cree further queried whether the susceptibility to NMO in humans is determined by a similar interplay between "background" and MHC loci. Just why the immune system in NMO selectively attacks the optic tract and spinal cord while sparing the brain remains speculative. Because these regions of the CNS are not thought to possess a different repertoire of glial cells or myelin proteins, the selective attack may be the result of differences in the structure/stability of the blood-brain barrier or subtle regional differences in the ability of the CNS to process and present antigen to T cells (323,360,363).

Clinical Manifestations

The primary features of NMO are visual loss caused by damage to the anterior visual sensory pathways and paraplegia caused by damage to the spinal cord. Other visual and neurologic manifestations are much less common.

Prodrome

Approximately one third of NMO patients develop a mild febrile illness several days or weeks before the onset of visual or neurologic manifestations of the disease (323, 336,364). Typical manifestations of this prodrome include sore throat, headache, and fever (365–367). In rare cases, there is a clear history of an antecedent viral illness, such as mumps (368), varicella (369), or infectious mononucleosis (370). The patient reported by Ko et al. (366) had high titers of antibodies against Epstein-Barr virus in her serum. A patient reported by Kline et al. (371) developed typical neuromyelitis optica 11 days after receiving a vaccination with attenuated live rubella virus.

In children, NMO is frequently preceded by infection (72%); these cases typically have a monophasic course and many have a complete recovery (336). Speculation exists regarding whether pediatric NMO should be considered a

variant of acute disseminating encephalomyelitis due to the association with preceding infection, monophasic course, and generally good outcome in children (336,372).

Loss of Vision

Visual loss in patients with neuromyelitis optica almost always is bilateral (323,330,331,336), although unilateral cases have been reported (323,336,349). One eye usually is affected first, but the second eye typically is affected within hours, days, or rarely weeks after onset (364). The loss of vision is typically rapid and usually severe. It is not uncommon for complete blindness to develop. The rapid, bilateral loss of vision that occurs in patients with NMO is in sharp contrast to the loss of vision in optic neuritis, which tends to be unilateral and not as severe, and to the loss of vision in Leber's hereditary optic neuropathy, which tends to be more slowly progressive. Pain in or about the eye precedes the loss of vision in a few cases, again distinguishing the condition from optic neuritis, in which pain is an almost universal feature (discussed previously). It is not currently possible to predict whether a patient presenting with optic neuritis or myelitis will develop NMO. However, the abrupt onset of a severe bilateral optic neuritis alerts one to the possible development of subsequent myelitis.

Since the foci of demyelination that affect the optic nerves are irregular and occur in a variety of different locations, the visual field defects that occur are similarly variable. In many instances, vision is so poor when the patient is first examined that it is impossible to plot the field defect. Nevertheless, central scotomas seem to be the most common defect observed, with some patients developing concentric contraction of one or both fields.

The ophthalmoscopic appearance of the optic discs varies considerably in patients with NMO. Most patients have mild swelling of both optic discs (330,336,365). Some patients, however, have substantial disc swelling that may be associated with dilation of retinal veins and extensive peripapillary exudates, and others have normal-appearing optic discs. With time, many patients develop pallor of the discs regardless of their initial appearance (Fig. 6.16). In some of these cases, there is slight narrowing of retinal vessels.

Some recovery of vision usually occurs in patients with NMO (323,331,332). Walsh stated that he had observed only one case of total permanent blindness among 12–15 cases (373), and Jeffery and Buncic (336) reported return of visual acuity to 20/20 in all 17 affected eyes of nine patients whom they studied. Visual acuity usually begins to improve within 1 week after visual symptoms begin, with maximum improvement occurring within several weeks to months. The peripheral fields usually begin to recover before there is noticeable improvement in the central-field defects. Nevertheless, some patients have severe and permanent visual loss in both eyes. Khan et al. (367), for example, reported the case of a 27-year-old pregnant woman who developed bilateral optic neuritis first in the right eye and 2 months later in the left eye. The visual function remained stable over the next several months. The patient then developed an acute transverse myelitis. On examination, she had no light percep-

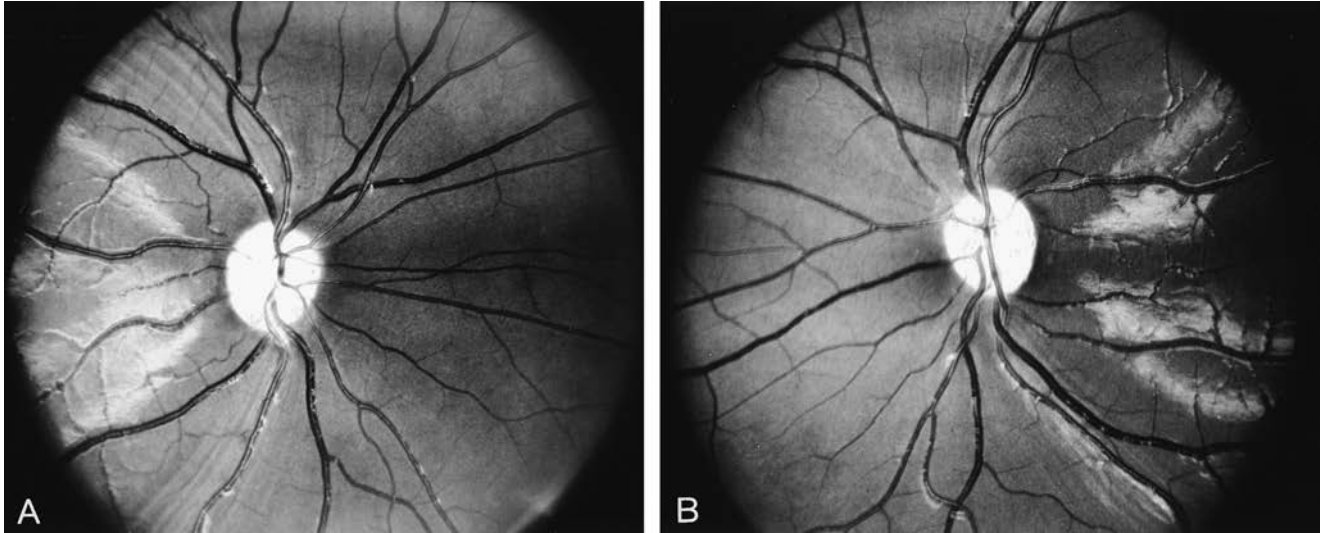


Figure 6.16. Ophthalmoscopic appearance in neuromyelitis optica (Devic's disease). The patient was a 13-year-old girl who developed transverse myelitis, followed several months later by bilateral visual loss. Visual acuity decreased to 20/400 OD and hand motions at 2 feet OS over 72 hours. The pupils were sluggishly reactive to light, and both optic discs appeared normal. The patient was treated with intravenous corticosteroids and gradually recovered both neurologic and visual function. Visual acuity eventually stabilized at 20/40 OD and 20/70 OS associated with small cecentral scotomas. The ophthalmoscopic appearance of the right and left ocular fundi, *A* and *B* respectively, shows symmetric pallor of the optic discs associated with atrophy of the retinal nerve fiber layer, especially in the papillomacular bundles.

tion in the right eye and only bare light perception in the left eye. There was no improvement in visual acuity over the subsequent 3 months.

There is some controversy about the relationship of visual loss to the onset of paraplegia. Most authors have reported that loss of vision precedes the onset of paraplegia in most cases (374); however, others have found that paraplegia usually precedes loss of vision (375). A similar controversy relates to whether one can diagnose NMO in a patient with bilateral severe optic neuritis without clinical evidence of spinal cord dysfunction. Although we agree that spinal cord damage in such cases could be minimal and subclinical, we would be averse to diagnosing "neuromyelitis optica sine myelitis" unless other studies such as MR imaging showed clear evidence of demyelinating lesions of the spinal cord.

Paraplegia

Paraparesis, which rapidly progresses to paraplegia, may precede or follow the loss of vision in patients with NMO (330). As noted above, the experience of some authors is that the visual loss occurs first (373,374), whereas that of other authors is that paraplegia occurs initially (375) and may be mistakenly assumed to be caused by an infarct or tumor of the spinal cord (376) until appropriate neuroimaging studies are performed. Regardless of which manifestation develops first, the interval between manifestations may be days, weeks, or months (349). In some cases, the blindness and paraplegia occur simultaneously. Hershewe et al. (332) suggested that a diagnosis of NMO should not be made unless the interval between the onset of visual loss and paraplegia is 2 months or less.

The onset of paraplegia, like that of visual loss, usually is sudden and severe, and it may be associated with a mild fever. Some patients develop an ascending paralysis that simulates the Guillain-Barré syndrome; however, the presence of associated sensory symptoms should be sufficient to eliminate Guillain-Barré syndrome from consideration (see Chapter 61). The paraplegia of NMO varies in different cases. Paraplegia in flexion, paraplegia in extension, and paraplegia with loss of all deep tendon (muscle stretch) reflexes may occur. There may be severe root pains, and urinary retention may be present or develop shortly after the onset of motor weakness. Ascending paralysis may paralyze respiration and cause death at an early stage of the disease. Most patients with NMO recover to some extent but have some residual paraparesis, and some have persistent and complete paralysis. The subsequent recovery of neurologic function, particularly in children suspected of having Devic's syndrome, should alert the clinician regarding the diagnosis of possible acute disseminated encephalomyelitis.

Laboratory Studies and Neuroimaging

During the active stage of NMO, the CSF usually shows evidence of an inflammatory process. There often is a mild lymphocytic pleocytosis (323,332,338,364,366,378), although Walsh (351) reported a case in which there were 1,000 white blood cells/mm³. The concentration of protein in the CSF may be increased, but intrathecal synthesis of IgG is not increased, and oligoclonal bands are rarely detected (378). The glucose concentration in the CSF invariably is normal. Rare cases have been recorded in which there has been evidence of increased intracranial pressure (379).

Chou et al. (380) reported a patient with NMO whose CSF contained antibody to glial fibrillary acidic protein (GFAP). The patient's serum did not contain this antibody, and it was therefore postulated by these authors that the antibody was being synthesized in the CNS.

Neuroimaging rarely shows intracranial lesions in patients with NMO (323). The spinal cord, however, may show changes consistent with demyelination (323,332,338,349,381), typically with areas of increased signal intensity spanning several sections of the spinal cord on T2-weighted images and with gadolinium enhancement (382). Cord swelling, in our experience, has been significant enough to be mistaken for an intrinsic cord tumor. Orbital MR imaging may demonstrate enlarged optic nerves with abnormal signal (Fig. 6.17) (381).

Recent interest has centered on serologic markers with myelin-specific antigens, which might identify patients with NMO. Weinshenker (383) analyzed sera from 101 patients with potential NMO on clinical grounds. The detection rate of NMO-IgG was 26/48 (54.2%) for patients with definite or probable NMO (using the most stringent clinical diagnostic criteria that require longitudinally extensive cord lesions), 13/33 (39.4%) for high-risk patients, and 0/20 (0%) for those with MS. Three high-risk patients seropositive for NMO-

IgG had recurrent, longitudinally extensive myelitis and subsequently developed clinically definite NMO. It was their feeling that the autoantibody NMO-IgG represents a potential biologic marker of NMO, and the presence or absence of this marker might help distinguish clinically defined NMO from typical MS. Their finding that seropositive high-risk patients later developed clinically definite NMO was quite striking. When positive, this autoantibody might allow early diagnosis and initiation of treatment in cases of definite NMO and in patients at high risk to convert to NMO. These findings may extend the spectrum of NMO to include some patients with recurrent optic neuritis or longitudinally extensive transverse myelitis.

Lennon (384) looked at sera from patients with definite NMO (48), MS (20), and numerous control disorders, including paraneoplastic vision loss (16), Sjögren's syndrome (10), vasculitides (10), and myasthenia gravis (10). The assay was indirect immunofluorescence with a standard composite substrate of mouse brain, gut, and kidney; sera were preabsorbed with liver extract. IgG in 26 (54%) of 48 patients with NMO yielded a distinctive staining pattern (NMO-IgG) associated with capillaries throughout the cerebellar cortex and midbrain, and with pia and a subpial mesh (prominent in midbrain). The capillary pattern was not seen

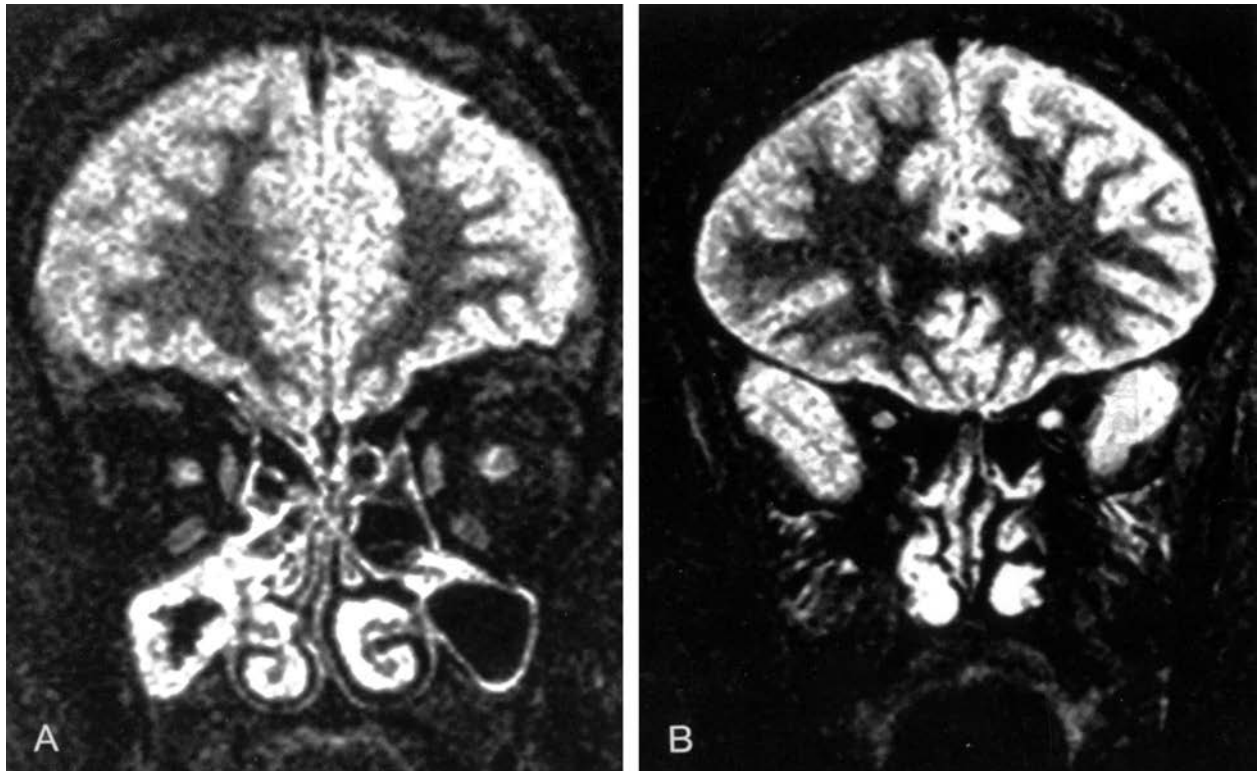


Figure 6.17. Neuroimaging in neuromyelitis optica (Devic's disease). The patient was a 39-year-old man who developed loss of vision in the left eye 4 days after developing paraparesis. *A*, Unenhanced proton density-weighted coronal MR image performed several hours after the onset of visual symptoms shows enlargement of the left optic nerve. *B*, Unenhanced proton density-weighted coronal MR image at a slightly different setting shows marked hyperintensity of the left optic nerve. (From Barkhof F, Scheltens P, Valk J, et al. Serial quantitative MR assessment of optic neuritis in a case of neuromyelitis optica, using Gadolinium-“enhanced” STIR imaging. *Neuroradiology* 1991;33:70–71.)

in gut mucosa, kidney, or liver, and NMO-IgG was not noted in any other study group, but it was identified incidentally in seven patients among thousands whose sera were submitted to Mayo Clinics Neuroimmunology Laboratory for paraneoplastic Ab service testing. Their histories revealed that one had definite NMO, three were at high risk for NMO (i.e., compatible findings but not fulfilling stringent criteria for definite NMO classification), one had new-onset myelopathy, one had unclassified steroid-responsive CNS inflammatory disorder, and one had gastroesophageal cancer and akathisia.

Lennon et al. (384) believed that the novel autoantibody NMO-IgG appears to bind selectively to an element associated with CNS capillaries, pia, and subpia. They felt that it held promise as a tool for serologic diagnosis of NMO at an early stage and for advancing the classification and therapy of related disorders. Given the above discussions, this autoantibody merits investigation as a candidate effector of NMO, which recent immunohistochemical studies suggest has a humoral and complement-mediated basis targeting CNS perivascular regions.

Genetics

Kuroiwa et al. (385) found several patterns that distinguish MS in Asia from MS in Western countries. Visual impairment, often accompanied by other manifestations of NMO, was more frequently seen in Asian populations. Shibasaki et al. (386) found that visual loss at the onset of neurologic symptoms and severe visual deficits were more frequent in Japanese patients. These clinical differences between Eastern and Western cases of MS have led to a hypothesis that clinical phenotypes of Asian-type MS may be due to immunogenetic variation. Kira et al. (137) studied the HLA locus in a series of Japanese patients with MS and found that, unlike in Western MS, the DR2-associated DRB1*1501 and DRB5*0101 alleles were not associated with NMO; rather, DPA1*0202 and DPB1*0501 alleles were associated with the NMO phenotype in Japanese patients but not with healthy control subjects or Japanese patients with typical MS (387). The HLA alleles with the strongest association with Western-type MS in Japanese patients were found to be DRB1*1501 and DRP1*0301 (323).

Of interest, the clinical course of MS in Japan may be changing: fewer patients present with Asian-type (opticospinal) MS and relatively more present with Western-type MS (388). This may, however, be due to an increased awareness of Asian cultures to the more subtle forms of Western-type MS.

Diagnosis

It may be impossible to differentiate between NMO and MS on clinical grounds alone, and some authors believe, as noted above, that they are simply variants of the same disease (323,329,337,354–356,573). Indeed, review of the literature suggests that some cases diagnosed as NMO are, in fact, MS (323,389). Nevertheless, not only are there important pathologic differences and differences in the CSF findings between the two diseases (discussed previously), but also there are important clinical differences between these two

disorders. First, NMO is not uncommon in the first decade of life, whereas MS rarely occurs in patients under 10 years of age. Second, the occurrence of bilateral optic neuritis associated with myelitis is rarely recorded in cases of pathologically proven MS. Third, bilateral blindness is extremely unusual in MS but is the rule in NMO. Also, and as reviewed above, the neurogenetic, serologic, and neuroimaging findings specific to NMO will likely allow better determination of this condition in the future as these modalities of testing become more widely available.

Treatment

There is no specific treatment for NMO, although as noted above one should consider the implications of the immunopathophysiology in rendering early and perhaps selective treatment based on considerations of the uniqueness of this disease process. Supportive care is crucial to ensure survival in patients with severe myelitis. The use of intravenous corticosteroids may lessen the severity of the attack and increase the speed of recovery of both visual and motor function (323,332,366). Frohman et al. (390) reported the case of a 15-year-old boy who developed typical NMO when he was 12 years old. His vision recovered, but he experienced recurrent attacks of bilateral, simultaneous optic neuritis over the next 3 years and became steroid dependent. Administration of IVIg allowed discontinuation of steroids without further ophthalmologic or neurologic deterioration or recurrent disease.

Despite our limitations in understanding the genetics, immunology, and cellular biology of NMO, the findings of Lucchinetti et al. are of substantial therapeutic importance (362). As noted above, NMO is associated with clearly defined MR and CSF abnormalities that should allow us to identify these patients rapidly. With the recent knowledge that humoral effector mechanisms have a central role in NMO, acute therapeutic interventions may focus on interrupting antibody/complement-dependent effector mechanisms. This could include plasmapheresis in cases where glucocorticosteroids are ineffective (391), IVIg, or complement inhibitors such as soluble CR-1. Long-term immunotherapy of NMO may be more problematic as drugs such as glatiramer acetate have the potential to augment Th-2-type responses (392). In patients with NMO, it may be worthwhile to consider treatment with highly active immunosuppressants such as mitoxantrone early in disease, reducing the immunotherapeutic regimen as soon as the patient has achieved stabilization or remission.

Prognosis

The mortality rate in patients with NMO was reported in the past to be as high as 50% (374,393); however, improvements in supportive care have greatly reduced this rate, and we would estimate that death occurs in less than 10% of cases (323,364).

As noted above, most patients experience some degree of recovery of both visual and motor function (323,332,364,

366). The recovery is rarely complete but may be substantial, particularly as regards vision (333). Visual recovery usually occurs within several weeks to months after the onset of visual loss; however, Walsh and Hoyt (377) evaluated a patient whose visual acuity decreased to 20/400 OU and remained at this level for 2 years. Four years later, vision in the right eye was still 20/400, but vision in the left eye had improved to 20/30. We wonder if this was a true case of NMO or perhaps could have been a case of Leber's optic neuropathy with other neurologic manifestations and late recovery, as has been reported in patients with some of the mitochondrial mutations (394). Some patients who experience an attack of NMO, however, never recover visual function and are left with severe bilateral visual loss.

NMO tends to occur as a single episode without recurrences, unlike MS. Nevertheless, occasional recurrences of both visual loss and paraplegia, both separate and simultaneous, have been documented (323,330,364,390).

OPTIC NEURITIS IN MYELINOCLASTIC DIFFUSE SCLEROSIS (ENCEPHALITIS PERIAXIALIS DIFFUSA, SCHILDER'S DISEASE)

In 1912, Schilder reported the case of a 12-year-old girl who experienced rapidly progressive mental deterioration associated with signs of increased intracranial pressure and death within 19 weeks. Postmortem examination disclosed large, well-demarcated areas of demyelination in the white matter of both cerebral hemispheres and a number of smaller demyelinating foci that resembled the typical plaques of MS. There was a prominent inflammatory reaction in both types of lesions with relative sparing of axon cylinders. Because of the similarities of the pathologic changes in this case to those of MS, Schilder called this disease "encephalitis periaxialis diffusa" to contrast it with the term "encephalitis periaxialis scleroticans" that had previously been used by Marburg (395) to describe a case of acute MS. Unfortunately, Schilder subsequently used the same term for two other completely different conditions (396,397). One seems to have been a case of adrenoleukodystrophy and the other a case of subacute sclerosing panencephalitis (398). These later reports seriously confused the subject for many years, and cases of adrenoleukodystrophy are still often called "Schilder's disease" (399). Nevertheless, if one separates the hereditary metabolic dystrophies and the various childhood disorders of cerebral white matter that have been called "Schilder's disease," there remains a characteristic group of cases that do indeed correspond to Schilder's original description (400,401). These latter cases, often referred to as myelinoclastic diffuse sclerosis, are nonfamilial, do not follow an obviously viral exanthem, and are not characterized pathologically by inclusion bodies or viral particles in the CNS. Throughout the remainder of this section, we will call this condition "myelinoclastic diffuse sclerosis."

The characteristic lesion in patients with myelinoclastic diffuse sclerosis is a large, sharply outlined, asymmetric focus of demyelination with severe, selective myelinoclasia that often affects an entire lobe or cerebral hemisphere

(350,402–406). There is typically extension across the corpus callosum and damage to the opposite hemisphere. Both hemispheres are symmetrically affected in some cases. Careful examination of the optic nerves, brain stem, cerebellum, and spinal cord often discloses typical discrete lesions consistent with MS, and histopathologic examination of both large and small foci reveals the characteristic features reminiscent of MS, including fibrillary gliosis with formation of giant multinucleated or swollen astrocytes and perivascular cuffing with inflammatory infiltrates containing plasma cells. The axons themselves may show little damage.

Both the clinical and histopathologic features of myelinoclastic diffuse sclerosis disease suggest that it is closely related to MS and probably is a variant of it, as Schilder originally proposed (407). The occurrence of myelinoclastic diffuse sclerosis in a patient who also had neuromyelitis optica (Devic's disease; discussed previously) lends credence to this philosophy (347).

Myelinoclastic diffuse sclerosis occurs most often in children and young adults (400,402,405,408,409,651), but it occasionally occurs in older persons (404,410). It is characterized by a progressive course that may be steady and unremitting or punctuated by a series of episodes of rapid worsening (398).

A change in personality may be the first evidence of the disease. Irritability, peevishness, unprovoked laughter or crying, and general apathy may also be present. Cortical blindness may also be an early feature of the disease, particularly in adults. Central deafness may also occur. Other manifestations include dementia, homonymous visual field defects, varying degrees of hemiparesis or quadriparesis often culminating in plegia, and pseudobulbar palsy. The brain stem and cerebellum are affected in some cases, and in such cases, nystagmus, intention tremor, scanning speech, and spastic paraplegia of spinal origin may develop.

The ocular symptoms that develop in patients with myelinoclastic diffuse sclerosis depend on the location of the lesions. As noted above, they may occur early in the course of the disease or later. Berliner (66) reviewed 35 cases of this disorder and found evidence of visual loss in 21 (60%). In 16 of the 21 cases (75%), visual loss occurred late in the disease.

Most patients who develop visual loss in this condition do so from damage to the postchiasmal visual pathways, producing homonymous hemianopic or quadrant visual field defects or cortical blindness (402,411). Occasional patients develop demyelination in the optic chiasm, producing bitemporal field defects. Other causes of visual difficulties in patients with myelinoclastic diffuse sclerosis include papilledema (412,413), damage to association areas of the cerebral cortex, and optic neuritis.

The frequency with which optic neuritis occurs in patients with myelinoclastic diffuse sclerosis is unclear, but it seems to be less frequent than in patients with MS. Berliner (66) was able to document only two cases, although Ford (413) remarked that he had observed examples of both anterior and retrobulbar optic neuritis in the condition. Such patients invariably develop optic atrophy if they survive long enough.

Nover (414) described a case of myelinoclastic diffuse sclerosis in which the ophthalmoscopic appearance of the fundus resembled retinitis punctata albescens. Accumulations of abnormal material were present on the inner aspect of the internal limiting membrane. It is unclear to us whether this was a true case of encephalitis periaxialis diffusa and whether the retinal findings were truly related to the underlying neurologic disease.

The CSF may show changes similar to those seen in typical MS (discussed previously). The intracranial pressure usually is normal, but in some patients the CSF is under increased pressure. The protein content of the CSF is usually slightly increased, and there may be a mild lymphocytic pleocytosis. The IgG content is often increased, as is the CSF IgG index (411). Oligoclonal bands may be present, and MBP is not only present but also extremely elevated (411). Neuroimaging studies show large, multifocal areas of extensive demyelination (404,405,409,415–419). In some cases, these lesions are similar in appearance to tumors or abscesses (411,417–419).

The diagnosis of myelinoclastic diffuse sclerosis may be suspected when a child or young adult develops evidence of a subacute or chronic progressive neurologic disease with neuroimaging and laboratory evidence of focal hemispheric demyelinating disease but without adrenal dysfunction or abnormal long chain fatty-acid components of serum cholesterol esters (409). Most patients do not have evidence of peripheral nerve damage; however, Szabo and Hegedus (420) described a case of otherwise typical myelinoclastic diffuse sclerosis in which there was evidence of a mild peripheral neuropathy. The diagnosis may be confirmed by brain biopsy (402,404,405,410,411,417,419).

Most patients with myelinoclastic diffuse sclerosis follow a progressive unremitting course that ends in death within a few months or years. A few cases have been reported in which there was temporary or permanent spontaneous improvement (413,418), and rare patients have been reported to survive for a decade or longer (420). Some patients have improved after being treated with systemic corticosteroids administered orally or intravenously (404,405,409,411,421). The patient reported by Lana-Peixoto and dos Santos experienced improvement in vision from hand motions in each eye to 20/20. Konkol et al. (422) reported improvement in an 8-year-old boy after intravenous administration of ACTH and cyclophosphamide. Patients who improve clinically generally show disappearance or shrinkage of the lesions seen on neuroimaging studies.

ENCEPHALITIS PERIAXIALIS CONCENTRICA (CONCENTRIC SCLEROSIS OF BALÓ)

Encephalitis periaxialis concentrica was first described by Marburg (395) in 1906 and later by Baló (423,424) in 1927 and 1928. Since then, more than 40 case reports have appeared in the literature (425–429). The disease clinically resembles myelinoclastic diffuse sclerosis but differs from it pathologically.

Encephalitis periaxialis concentrica usually is characterized clinically by a relatively rapid course during which patients develop a variety of neurologic symptoms and signs separated in both space and time, including visual loss and diplopia. As in encephalitis periaxialis diffusa, the visual loss that occurs in most patients with encephalitis periaxialis concentrica is usually caused by damage to postgeniculate visual pathways and is characterized by homonymous field defects or cortical blindness; however, a patient reported by Currie et al. (430), who initially had a left homonymous hemianopsia, eventually developed complete blindness associated with pupils that were nonreactive to light and optic discs that were markedly pale.

The pathologic changes in the disease described by Baló consist of alternating bands of demyelination and preserved myelin in a series of concentric rings in the cerebral white matter (348,350,406,424,430,431). The occurrence of lesions in this pattern has suggested to some investigators that there is centrifugal diffusion of some factor that is damaging to myelin (427); however, Moore et al. (429) performed a complete histologic and ultrastructural examination of neural tissue obtained from a 54-year-old woman with the disease and concluded that the predominant feature of the bands of myelin is remyelination. These authors suggest that the lesion originates as a small focus of acute demyelination around a perivascular inflammatory cuff and that the concentric bands are actually alternating areas of demyelination and remyelination. The remyelination occurs at the outer rim of the initial demyelinated area. Further demyelination then occurs external to the area of remyelination, and remyelination then occurs along the outer rim of this second area of demyelination. In this way, successive concentric rings of demyelination and remyelination are produced. The findings of Moore et al. (429) have not been corroborated by other investigators (431). Some patients with otherwise typical encephalitis periaxialis concentrica have not only pathologic changes consistent with the disease but also lesions typical of acute MS (429,431), suggesting that the former disease may actually be a variant of the latter.

Neuroimaging studies initially may be normal in patients with encephalitis periaxialis concentrica; however, eventually both CT scanning and MR imaging show multiple lesions consistent with demyelination (432,433). Similarly, analysis of the CSF at an early stage of the disease may reveal normal findings, but later analysis may show mild to moderate pleocytosis, increased protein, an increased IgG index, and multiple oligoclonal bands (430). The diagnosis can be made with certainty only by a stereotactic biopsy of affected brain (432,433).

Without treatment, encephalitis periaxialis concentrica usually progresses inexorably and is invariably fatal within a few weeks to a year. Treatment with systemic corticosteroids, however, may result in both immediate and long-term improvement in neurologic symptoms and signs. Early diagnosis thus is extremely important, and stereotactic biopsy seems to be an acceptable method of achieving this goal (432,433).

CAUSES OF OPTIC NEURITIS OTHER THAN PRIMARY DEMYELINATION

In a few cases, a primary demyelinating process in the optic nerve or the CNS is not the cause of unilateral or bilateral anterior or retrobulbar optic neuritis. Instead, the condition develops in the setting of, or as the presenting manifestation of, an underlying systemic infection.

OPTIC NEURITIS FROM VIRAL AND BACTERIAL DISEASES

Parainfectious optic neuritis typically follows the onset of a viral or, less often, a bacterial infection by 1 to 3 weeks (37,434,435). It is more common in children than in adults and is thought to occur on an immunologic basis, producing demyelination of the optic nerve. The optic neuritis may be unilateral, but it is often bilateral. The optic discs may appear normal or swollen. Swelling of the peripapillary retina may be observed in patients with anterior optic neuritis. If a star figure composed of lipid exudates develops in the macula of the affected eye, the condition is called “neuroretinitis” (discussed later). If there is evidence of optic disc swelling but no evidence of optic nerve dysfunction, and the intracranial pressure is normal, the inflammation is assumed to be affecting the periphery of the nerve and is called “perioptic neuritis” or “optic perineuritis” (discussed later).

Parainfectious optic neuritis, whether viral or bacterial, may occur in patients with no evidence of neurologic dysfunction or in association with a meningitis, meningoencephalitis, or encephalomyelitis. When neurologic manifestations are present, patients have typical abnormalities in the CSF. Patients with encephalitis usually have disturbances on electroencephalography and also may have changes in the brain seen by neuroimaging, whereas patients with encephalomyelitis may show such changes in both the brain and the spinal cord.

Visual recovery following parainfectious optic neuritis is usually excellent without treatment. Whether corticosteroids hasten recovery in patients with postviral optic neuritis is unknown, but this treatment is reasonable to consider, particularly if visual loss is bilateral and severe.

Optic neuritis may occur in association with infections by a large number of both DNA and RNA viruses, including adenovirus (436,437), Coxsackie virus (438,439), cytomegalovirus (440), hepatitis A (441), hepatitis B (442,443), human herpesvirus type 4 (Epstein-Barr virus) (444–448), human immunodeficiency virus (HIV) type 1 (449,450), measles (451–455), mumps (456–458), rubeola, rubella (459), and varicella zoster (in chicken pox [460,461] and in herpes zoster [462,463]). The neuro-ophthalmologic significance of these and other viruses is discussed in detail in Chapters 57 and 58.

Bacterial infections can produce optic neuritis. Some bacterial infections in which anterior or retrobulbar optic neuritis may occur include anthrax (464), β -hemolytic streptococcal infection (465), brucellosis (466,467), cat scratch disease (39,468,469,470), meningococcal infection (471), pertussis (472), tuberculosis (473–477), typhoid fever (478,479), and Whipple’s disease (480). The neuro-ophthalmologic signifi-

cance of these and other bacteria is discussed in detail in Chapter 49.

OPTIC NEURITIS AFTER VACCINATION

Although there is extensive anecdotal evidence of optic neuritis occurring following vaccinations, the actual evidence of a demyelinating event following vaccination is limited. In this section we first review the anecdotal information regarding optic neuritis and vaccinations; we then will explore the evidence-based medicine surrounding the relationship of vaccinations to demyelinating events in general.

Optic neuritis has been reported to occur after vaccinations against both bacterial and virus infections (38). Most cases are bilateral, and both anterior and retrobulbar forms of optic neuritis may occur. Optic neuritis may develop after vaccinations with bacillus Calmette Guérin (BCG) (481), hepatitis B virus (482,483), rabies virus (484–486), tetanus toxoid (487), and variola virus (488). The use of a combined smallpox, tetanus, and diphtheria vaccine was associated with a bilateral anterior optic neuritis in a 7-year-old child who eventually recovered completely (489), and a similar case was reported in association with combined measles, mumps, and rubella vaccination (490). Influenza vaccine is commonly associated with the development of optic neuritis. Perry et al. (491) reported a patient with bilateral anterior optic neuritis that occurred 6 days following vaccination with bivalent influenza vaccine. Ray and Dreizen (492) described a similar case. Cangemi and Bergen (493) reported a previously healthy man who developed a unilateral optic neuritis with disc swelling, 3 weeks after inoculation with 200 units of A-New Jersey swine influenza and 200 units of A-Victoria influenza whole-virus vaccine. Although most cases of postvaccination optic neuritis appear to be of the anterior variety, unilateral retrobulbar neuritis has been reported 3 weeks following a swine influenza vaccination (494).

Despite the previous anecdotal reports, the evidence-based medicine that vaccination may precipitate the onset of MS or lead to relapses is simply not present. Confavreux et al. (495) conducted a case-crossover study to assess whether vaccinations increase the risk of relapse in MS. The subjects included 643 patients included in the European Database for Multiple Sclerosis who had a relapse between 1993 and 1997. The index relapse was the first relapse confirmed by a visit to a neurologist and preceded by a relapse-free period of at least 12 months. Information on vaccinations was obtained in a standardized telephone interview and confirmed by medical records. Exposure to vaccination in the 2-month risk period immediately preceding the relapse was compared with that in the four previous 2-month control periods for the calculation of relative risks, which were estimated with the use of conditional logistic regression. Of these patients with relapses of MS, 15% reported having been vaccinated during the preceding 12 months. The reports of 94% of these vaccinations were confirmed. Of all the patients, 2.3% had been vaccinated during the preceding 2-month risk period, compared with 2.8–4.0% who were vac-

cinated during one or more of the four control periods. The relative risk of relapse associated with exposure to any vaccination during the previous 2 months was 0.71 (95% CI, 0.40–1.26). There was no increase in the specific risk of relapse associated with tetanus, hepatitis B, or influenza vaccination (range of relative risks, 0.22–1.08). Analyses based on risk periods of 1 and 3 months yielded similar results. These authors concluded that vaccination does not appear to increase the short-term risk of relapse in MS.

To further evaluate the association between vaccination and onset of MS or optic neuritis, DeStefano et al. (496) looked at a case-control study involving cases of MS or optic neuritis among adults 18–49 years of age. Data on vaccinations and other risk factors were obtained from computerized and paper medical records and from telephone interviews in three health maintenance organizations. Four hundred forty case subjects and 950 control subjects matched on health maintenance organization, sex, and date of birth were assessed. They noted the onset of first symptoms of demyelinating disease at any time after vaccination and during specified intervals after vaccination (less than year, 1–5 years, and more than 5 years). Cases and controls had similar vaccination histories. The odds ratios (95% CI), adjusted for potential confounding variables, of the associations between ever having been vaccinated and risk of demyelinating disease (MS and optic neuritis combined) were 0.9 (0.6–1.5) for hepatitis B vaccine; 0.6 (0.4–0.8) for tetanus vaccination; 0.8 (0.6–1.2) for influenza vaccine; 0.8 (0.5–1.5) for measles, mumps, rubella vaccine; 0.9 (0.5–1.4) for measles vaccine; and 0.7 (0.4–1.0) for rubella vaccine. The results were similar when MS and optic neuritis were analyzed separately. There was no increased risk according to timing of vaccination. It was the conclusion in this case-control study that vaccination against hepatitis B, influenza, tetanus, measles, or rubella is not associated with an increased risk of MS or optic neuritis.

It would appear that there are two primary issues regarding the relationship between vaccinations and MS: Does the vaccination precipitate the first attack of MS? Does it increase the short- or long-term risk in patients with known disease? It would appear from the preceding studies that vaccinations do not precipitate the seminal event in MS. The second question is more difficult to answer. Acute disseminated encephalomyelitis (ADEM), a monophasic and multifocal illness of the white and gray matter, has been observed following various viral or bacterial infections as well as vaccine injections for diseases such as pertussis, tetanus, and yellow fever. The similarities between ADEM and EAE are suggestive of an immunologic process. In addition to the dramatic presentation of ADEM, more limited white matter involvement, such as optic neuritis or myelitis, has been reported following vaccine injections and has occasionally been counted as the first attack of MS. In France, 25 million inhabitants, almost half of the population, were vaccinated against hepatitis B (HB) between 1991 and 1999 (497). Several hundred cases of an acute central demyelinating event following HB vaccination were reported to the pharmacovigilance unit, leading to a modification of vaccination policy in the schools and the initiation of several studies designed to examine the possible

relationship between the vaccine and the central demyelinating events. The results of these studies failed to establish the causality of the HB vaccine. Nevertheless, molecular mimicry between HB antigen(s) and one or more myelin proteins, or a nonspecific activation of autoreactive lymphocytes, could constitute possible pathogenetic mechanisms for these adverse neurologic events.

Although demyelinating events might in fact be precipitated by vaccinations, the chance of this occurring is low, and the risk to the patient with MS is minimal compared with the potential risk to the MS patient of disease state worsening due to an infectious disease.

OPTIC NEURITIS IN SARCOIDOSIS

Granulomatous inflammation of the optic nerve may occur in sarcoidosis, producing a typical anterior or retrobulbar optic neuritis (498–502). In some cases, the optic neuritis occurs during the disease; in others, it is the presenting manifestation. Clinical findings may be indistinguishable from those of demyelinating optic neuritis. However, the optic disc may have a characteristic lumpy, white appearance, which suggests a granulomatous etiology, and there may be an inflammatory reaction in the vitreous. Pain, common in a demyelinating optic neuritis, is often absent in the optic neuropathy of sarcoidosis.

Unlike primary demyelinating optic neuritis, which does not respond dramatically to systemic corticosteroids (discussed previously), the optic neuritis associated with sarcoidosis is usually extremely sensitive to steroids. In most cases, recovery of vision is rapid after treatment is instituted, although vision may decline again once steroids are tapered or stopped. Indeed, it must be emphasized that rapid recovery of vision with corticosteroid treatment and subsequent worsening when the steroids are tapered is atypical for demyelinating optic neuritis and suggests an infiltrative or nondemyelinating inflammatory process, such as sarcoidosis.

Patients with possible sarcoid optic neuritis should undergo an evaluation that includes a careful history and physical examination, a chest radiograph, serum chemistries, an assay for angiotensin converting enzyme (ACE) in the serum and CSF, a gallium scan, and in some cases bronchoscopic lavage or biopsy of skin, conjunctiva, lung, liver, or other organs looking for noncaseating granulomas. Sarcoidosis and related conditions are discussed in detail in Chapter 59.

SYPHILIS

Optic neuritis from syphilis is not rare (503–505), but it is particularly common in patients also infected with HIV (506–509) (see Chapters 56 and 58). The optic neuritis of syphilis can be unilateral or bilateral and anterior or retrobulbar. When the condition is anterior, there is usually some cellular reaction in the vitreous, which serves to distinguish it (and other systemic inflammatory diseases that cause anterior optic neuritis) from demyelinating optic neuritis, in which the vitreous usually is clear (discussed previously).

The diagnosis of syphilis is established using a variety of serologic and CSF assays. Treatment with intravenous

penicillin produces visual recovery in many cases; however, the disease may be difficult to cure, particularly in patients who are HIV positive or who have the acquired immune deficiency syndrome (AIDS).

Syphilis can cause both neuroretinitis and optic perineuritis (discussed later). Syphilis is discussed in detail in Chapter 56.

OPTIC NEURITIS IN HIV-POSITIVE PATIENTS AND PATIENTS WITH AIDS

Many infectious agents that do not normally cause optic neuritis can do so in patients who are immunocompromised from drugs or disease. Such optic neuritis is particularly common in patients who are infected with HIV and in patients with AIDS (510,511).

Optic neuritis, both anterior and retrobulbar, is an occasional finding in HIV-infected patients with cryptococcal meningitis, cytomegalovirus infection, herpesvirus infections, syphilis, tuberculous meningitis, and a variety of fungal infections (440,507,510,511–517). Rare patients with toxoplasmosis may also develop optic neuritis (518,519). In some cases, such infections cause neuroretinitis, whereas in others, optic perineuritis occurs.

Some patients with AIDS develop optic neuritis that is probably caused by infection of the optic nerve by HIV itself (449). Infection with HIV and AIDS are discussed in detail in Chapter 58.

OPTIC NEURITIS IN SYSTEMIC LUPUS ERYTHEMATOSUS (SLE) AND OTHER VASCULITIDES

Patients with SLE, polyarteritis nodosa, and other vasculitides can experience an attack of what seems clinically to be typical acute optic neuritis (520). This phenomenon occurs in about 1% of patients with SLE (521–531). In rare cases, the optic neuropathy is the presenting sign of the disease. The pathogenesis is not a true infection or inflammation of the nerve tissue itself but is related to ischemia, which may produce demyelination alone, axonal necrosis, or a combination of the two.

The clinical profile of optic neuropathy in SLE and other vasculitides actually can take several forms in addition to an acute anterior or retrobulbar optic neuropathy associated with pain. Patients may present with symptoms and signs that suggest a retrobulbar or anterior ischemic optic neuropathy, or they may have slowly progressive loss of vision that suggests a compressive lesion.

The diagnosis of SLE or other vasculitides as a cause of optic neuropathy is established by identification of systemic symptoms and signs of the disease as well as by serologic testing. Treatment with either intravenous or oral corticosteroids may be indicated in this condition.

The term “autoimmune optic neuritis” has been suggested for cases of optic neuritis in which there is both serologic evidence of vasculitis, such as a positive ANA, but no signs of systemic involvement other than the optic neuropathy; and progressive visual loss that tends to be responsive to treatment with systemic corticosteroids and that is often steroid dependent (i.e., vision worsens when steroids are

tapered) (531,532,532a). It is interesting that among patients enrolled in the ONTT, 3% had a positive ANA titer greater than 1:320 (7). Only one of these patients developed other evidence of connective tissue disease during the first 2 years of follow-up. In addition, patients with a positive ANA (regardless of the titer) who were treated with placebo had the same visual outcome as those treated with intravenous methylprednisolone (8). SLE and other vasculitides that produce neuro-ophthalmologic manifestations are discussed in detail in Chapter 44.

LYME DISEASE

Optic neuritis can occur in patients with Lyme borreliosis (Lyme disease) (533–536). This disorder is a spirochetal infection that is transmitted through the bite of an infected tick. It can produce a multitude of ocular and neurologic findings, including both anterior and retrobulbar optic neuritis. The diagnosis of Lyme disease is made by serologic detection of infection or by finding the organism or its nucleic acid in the serum or CSF. Treatment with antibiotics is usually effective, particularly in the early stages of the disease. As with other systemic infectious processes that can cause optic neuritis, Lyme disease can also cause neuroretinitis (discussed later). Lyme disease is discussed in detail in Chapter 56.

SINUS DISEASE

In the pre-antibiotic era, spread of infection from the paranasal sinuses to the optic nerve was not unusual. However, this is a rare occurrence now, and most cases of sinusitis in patients with optic neuritis are fortuitous. Nevertheless, some patients with acute severe sinusitis develop a secondary optic neuritis from spread of infection. When the infection originates from the ethmoid or maxillary sinuses, there generally are obvious signs of orbital inflammation; however, spread of infection from the sphenoid sinus to the posterior optic nerve in the apex of the orbit or within the optic canal can be silent except for the loss of vision. Aspergillosis and other fungal infections are considerations in this clinical setting (537,538). Neuroimaging techniques, particularly CT scanning and MR imaging, generally can be used to diagnose paranasal sinus disease.

Even when sinus disease is present in the setting of optic neuritis, one must be wary of attributing the optic neuritis to this cause. Obviously, those patients with retrobulbar neuritis and supportive sinusitis with signs of orbital inflammation should be actively treated not only to eradicate the infection but also for the possible beneficial effects of treatment on the optic neuritis; however, in our opinion, operative intervention in patients with radiologic evidence of sinus disease that normally would not call for medical or surgical therapy is unwarranted.

MISCELLANEOUS CAUSES OF OPTIC NEURITIS

Optic neuritis has been reported to occur rarely in many conditions other than bacterial or viral infections, including acute posterior multifocal placoid pigment epitheliopathy

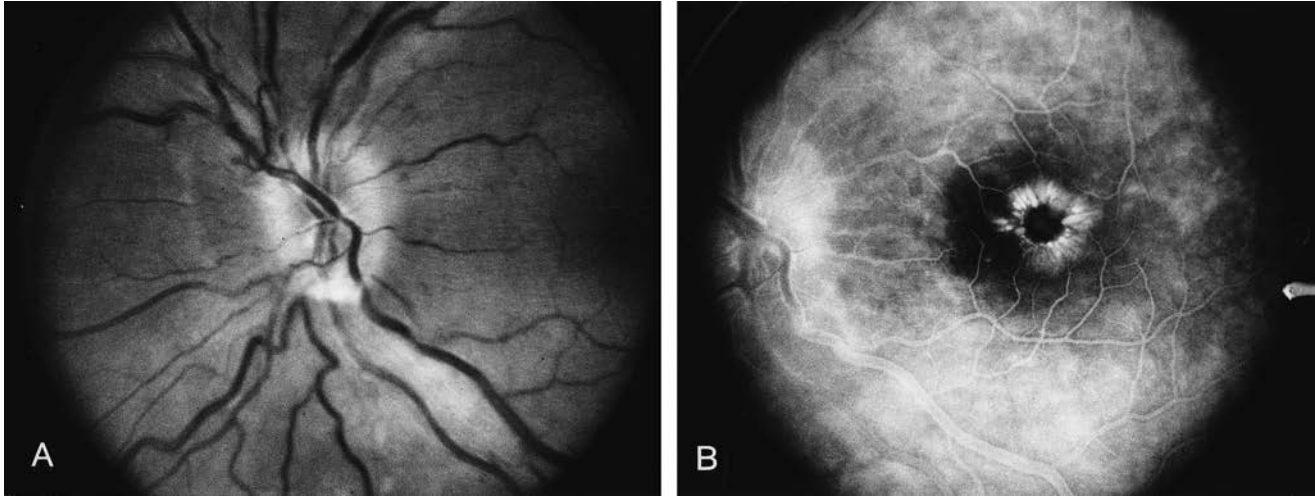


Figure 6.18. Optic disc swelling in a patient with pars planitis (chronic cyclitis). The patient was initially believed to have papilledema. *A*, The left optic disc is hyperemic and slightly swollen. The hazy appearance is due to the presence of vitreous cells. *B*, Fluorescein angiogram of the left macula shows cystoid macular edema, characteristic of this disorder. The opposite eye had a similar ophthalmoscopic appearance.

(504,539), after a bee sting (540–543), Behçet’s disease (544), birdshot retinochoroidopathy (545), Creutzfeldt-Jakob disease (546,547), cysticercosis (548), familial Mediterranean fever (549), Guillain-Barré syndrome (550–553), inflammatory bowel disease (554–559), intraocular nematode infection (504,560,561), presumed histoplasmosis (562,563), Reiter’s syndrome (564,565), toxocariasis (566), toxoplasmosis associated with or unassociated with AIDS (567,568), and *Mycoplasma pneumoniae* infection (569–572). As is true for optic neuritis associated with bacterial or viral infections, some of these cases are isolated, whereas others are associated with other evidence of CNS dysfunction.

Intraocular inflammation alone may cause optic disc swelling; however, in such cases, visual acuity is usually not significantly affected from damage to the optic nerve (504,573–575) (Fig. 6.18). In such patients, visual acuity is limited only by the degree of vitreous inflammation or by

secondary changes that occur in the macula (e.g., cystoid edema). Perhaps the most common form of disc swelling that occurs as part of an ocular inflammatory syndrome is that which occurs after cataract extraction and is associated with moderately decreased visual acuity and cystoid macular edema: the Irvine-Gass syndrome (576–578).

As mentioned above, the presence of uveitis and other symptoms of intraocular inflammation in a patient with acute anterior optic neuritis should alert the examiner to search for an associated intraocular or systemic disease.

Hanna and Girgis (579) found a 1.5% prevalence of optic atrophy in 2,178 patients after meningitis. Although postpapilledema optic atrophy accounted for some of these cases, primary optic atrophy, presumably the result of an associated optic neuritis, was much more frequent. In this study, optic atrophy occurred more frequently after tuberculous meningitis than after bacterial meningitis, including meningococcal, pneumococcal, and purulent meningitis of unknown etiology.

BILATERAL OPTIC NEURITIS

In adults, bilateral simultaneous acute optic neuritis, particularly that associated with MS, is uncommon but well described. Adie (80) found only one case of bilateral optic neuritis in his series of 70 adult patients, and other authors (66,580) agreed with him that both simultaneous and early consecutive cases were exceedingly rare (Fig. 6.19). However, reports indicate that the incidence of bilateral simultaneous acute optic neuritis in patients with MS is 10–75% (68,82,83,197,581). Morrissey et al. (275) performed a retrospective analysis of the causes of bilateral simultaneous acute optic neuritis in 23 adults and found that 5 of the patients (22%) had developed clinical evidence of MS. In many of these series, the time interval between attacks in the two eyes is not stated. Bradley and Whitty (82) separated

their cases into those that were unilateral (71%), those that were bilateral and simultaneous (7%), those that were bilateral and nonsimultaneous but occurred within 3 months of each other (12%), and those that occurred more than 3 months apart (12%). These authors found no significant differences in rate and degree of recovery between bilateral and unilateral cases, regardless of the time interval between the attacks. The studies of Rischbieth (582) and of Hutchinson (83) seem to support this view.

In the ONTT, approximately 48% of patients with involvement of one eye had some other definable visual field involvement of the contralateral eye, suggesting that optic neuritis is quite frequently present bilaterally from the onset (11).

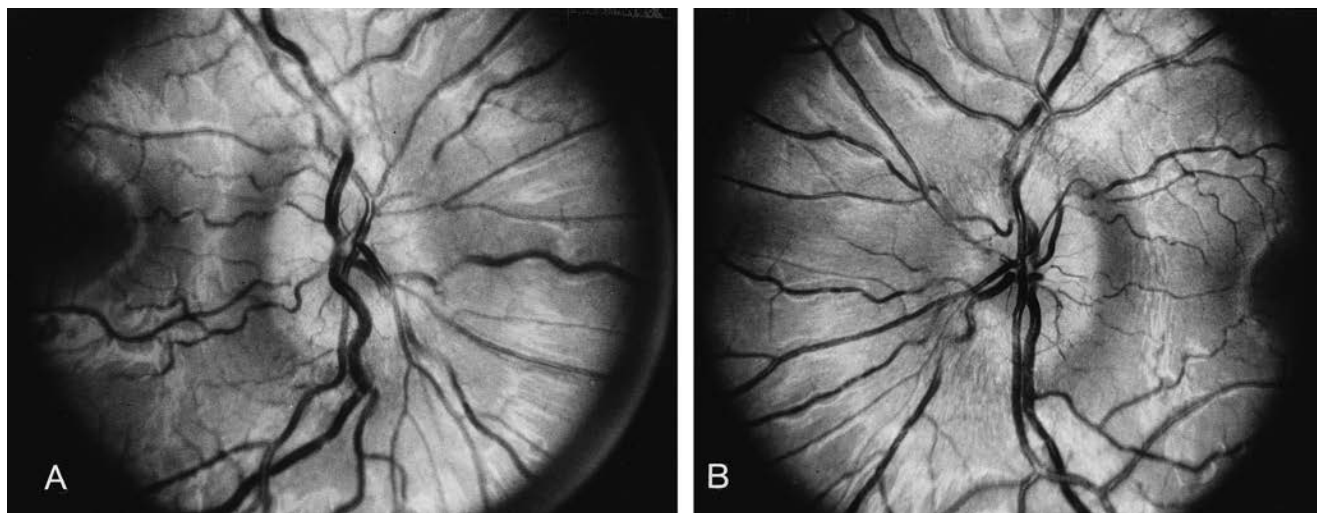


Figure 6.19. Bilateral anterior optic neuritis. The patient is a 19-year-old girl who suffered bilateral visual loss 2 weeks following a flulike illness. Both optic discs show moderate swelling without hemorrhages. Visual acuity is 20/400 in the right eye and 20/300 in the left eye, and there are bilateral central scotomas. Visual acuity returned to normal within 6 weeks, and disc swelling completely resolved.

In contrast to adults, acute optic neuritis is quite often bilateral and simultaneous in children. In such cases, it is

often presumed to be related to a viral infection (discussed later).

OPTIC NEURITIS IN CHILDREN

Optic neuritis in children has several unique characteristics that distinguish it from optic neuritis in adults. First, it is more often anterior. Second, it is more often a bilateral simultaneous condition. Third, it often seems to occur within 1–2 weeks after a known or presumed viral infection. Fourth, it is less often associated with the development of MS. Finally, it is often steroid sensitive and steroid dependent.

Kennedy and Carroll (35) examined 30 children with idiopathic optic neuritis. The youngest child was 4 years old, and the mean age of the group was 9.5 years. These investigators found disc swelling in more than 70% of children (as opposed to a prevalence of 20–40% in adults). In addition, over 50% of the children whom Kennedy and Carroll (35) studied had bilateral disease, a significantly higher frequency than in adults. Most of the patients in this series had central scotomas and visual acuity less than 20/200, with only one patient having visual acuity better than 20/50. Despite the poor initial visual acuity in these patients, the visual prognosis in children with optic neuritis appears to be quite good. Kennedy and Carroll (35) performed follow-up examinations on 19 of their 22 children with idiopathic anterior optic neuritis. Fifteen of the children recovered completely, two had moderate return of vision, and only two children had no significant improvement. Of three children with acute retrobulbar optic neuritis and normal optic discs at the time of visual loss, two had a complete recovery, although the third child had only a moderate return of vision and suffered a second attack of visual loss 4 years later from which she never recovered. No further information was given by these authors regarding final visual acuity or fields in these pa-

tients. Eight of the patients with idiopathic optic neuritis in this study developed MS over a mean follow-up period of 8 years.

Kriss et al. (37) studied 39 children with optic neuritis. After a mean follow-up of 8.8 years (range 3 months to 29 years), MS had developed in six (15%). The visual prognosis was reported to be excellent. Riikonen (38) reported on 18 children with optic neuritis. A vaccination preceded the development of optic neuritis in 6 of the 18 (33%) and a bacterial or viral infection preceded it in 10 (55.6%). Eight of the 18 (44.4%) children developed MS during the study.

Nakao et al. (583) found 9 cases of optic neuritis in children among 201 cases (5%) of optic neuritis evaluated at Osaka University Medical School in Japan. In all nine cases, the optic neuritis was bilateral and associated with severe visual loss. Optic disc swelling was present in most of the children, several of whom had associated upper respiratory tract infections, meningitis, or encephalitis. All were treated with systemic corticosteroids, and all experienced improvement in vision.

Hierons and Lyle (34) collected data on 13 cases of bilateral optic neuritis in children under the age of 13, 10 of whom were girls. Five of the patients had a history of specific exanthem or an indeterminate febrile illness before visual symptoms began, and all but one patient made a good visual recovery. Only one patient developed MS over a mean follow-up period of 4 years.

Meadows (36) reviewed 35 cases of bilateral optic neuritis in children, most between the ages of 5 and 12. Over a follow-up period of 3–18 years, 12 of the patients were lost to

examination, but of the remaining 21, none developed MS. Although Meadows (36) referred to his cases as examples of "retro-bulbar neuritis," he stated that in the "vast majority of cases seen during the early acute phase, the optic discs were abnormal," with the abnormality varying from mild blurring of the disc margins to marked swelling of the disc with peripapillary hemorrhages.

Keast-Butler and Taylor (584) described four cases, and Cohen et al. (585) and Rollinson (586) reported isolated cases, of bilateral optic neuritis with disc swelling in children. None of the children experienced any preceding exanthema, and all patients recovered excellent vision, even though the patient reported by Cohen et al. (585) had no perception of light in either eye at one point during her hospital course.

Farris and Pickard (435) described six children who developed acute simultaneous bilateral optic neuritis. Five of the six children had recently experienced a brief upper respiratory or gastrointestinal illness, presumed to be viral in nature. Five of the six patients also demonstrated marked neurologic deficits, including seizures and cerebellar dysfunction. Lumbar puncture was abnormal in three of the six patients. All patients were treated with a course of intravenous methylprednisolone, ranging from 1–2 mg/kg/day, and each patient experienced a rapid and nearly complete recovery of vision during treatment.

Koraszevska-Matuszevska et al. (587) reported a large series of optic neuritis in childhood. These investigators reviewed the records from 110 children, aged 2–18 years (mean 13 years) with optic neuritis. Sixty percent of the children had bilateral simultaneous optic neuritis. Children younger than 14 years of age tended to have anterior optic neuritis, whereas retrobulbar neuritis was more common in children over 14 years old. In younger patients, the cause of the inflammation seemed to be viral infections or chronic focal infection. Older children often had underlying neurologic disease. The use of systemic steroids resulted in improvement of visual acuity in about 75% of cases and improvement or normalization of the visual field in over 50% of cases, regardless of whether the optic neuritis was of the anterior or retrobulbar variety. Normal visual function was regained in about 50% of the children during a follow-up period of 3 years. These children tended to be those with the least severe visual loss during the acute phase of the optic neuritis.

Good et al. (588) reviewed the records of 10 children with optic neuritis in whom recovery of vision was poor or incomplete. These investigators found that in all cases, the condition had been bilateral. Optic disc swelling had been present in 7 of the 10 cases (70%), and 70% of the cases had been preceded by a viral illness. Five of the 10 children (50%) had developed evidence of MS.

Brady et al. (589) evaluated the presenting features, neuroimaging findings, CSF abnormalities, associated systemic disease, and visual outcome in children with optic neuritis. A retrospective analysis was performed on all patients who were seen at Baylor College of Medicine with optic neuritis during a 6-year period from 1991 to 1997. The degree of initial visual loss, subsequent visual recovery, and associated

disease were reviewed. MR images and CSF findings were also analyzed. Twenty-five patients (39 eyes) 21 months of age to 18 years of age were included in the study, with a mean follow-up of 11 months. Fourteen patients (56%) had bilateral optic neuritis, and 11 patients (44%) had unilateral disease. Thirty-three of 39 eyes (84%) had visual acuity of 20/200 or less at presentation. Twenty-one of 25 patients (84%) were given intravenous methylprednisolone (10–30 mg/kg/day). Thirty of 39 eyes (76%) recovered 20/40 visual acuity or better. Three of 39 eyes (7%) recovered vision in the 20/50 to 20/100 range. Six of 39 eyes (15%) recovered vision of 20/200 or less. Twenty-three of 25 patients (92%) underwent MR imaging of the brain. A normal MR image of the brain was associated with recovery of 20/40 or better visual acuity in six of six affected eyes (100%). Seven patients were 6 years of age or younger at presentation. Six of these seven (85%) had bilateral disease, and 12 of 13 (92%) affected eyes recovered 20/40 visual acuity or better. Eighteen patients were 7 years of age or older at presentation. Eight of these 18 (44%) had bilateral disease, and 10 of 18 patients (56%) had unilateral disease. Eighteen of 26 affected eyes (50%) recovered 20/40 visual acuity or better. These authors concluded that pediatric optic neuritis is usually associated with visual recovery; however, a significant number (22%) remain visually disabled. A normal MR image of the brain may be associated with a better outcome. Younger patients were more likely to have bilateral disease and a better visual prognosis.

Morales et al. (590) reviewed all charts of patients less than 15 years of age who presented with optic neuritis to the Bascom Palmer Eye Institute or the Miami Children's Hospital between 1986 and 1998. Fifteen patients were identified. There was a slight female predilection in the study group (60%), with a mean age of 9.8 years at presentation. A preceding febrile illness within 2 weeks of visual symptoms was reported in 66% of patients. Initial visual acuity ranged from 20/15 to no light perception. Involvement was bilateral in 66% of patients, and disc swelling was present in 64% of involved eyes. Of the patients who underwent MR imaging, 33% had focal demyelinating lesions in the brain, and 63% of affected nerves were enlarged or enhanced with gadolinium. Eleven patients were treated with intravenous steroids. Final visual acuity was 20/40 or more in 58.3% of eyes. Thirty percent of the patients had vision of finger counting or worse. Four (26%) patients developed MS. The mean age of patients with MS was 12 years, compared with 9 years in children who did not develop MS. Patients with unilateral involvement had an excellent visual prognosis (100% more than 20/40) but a higher rate of development of MS (75%). Two patients had positive serology for Lyme disease. It was their conclusion that optic neuritis presents differently in children than in adults. Children typically have bilateral involvement with papillitis following an antecedent viral illness. Although visual prognosis is poorer in children than adults, the development of MS is less common in children. Children who present with unilateral involvement have a better visual prognosis; however, they also develop MS at a greater frequency than children with bilateral involvement. Patients who developed MS were, on aver-

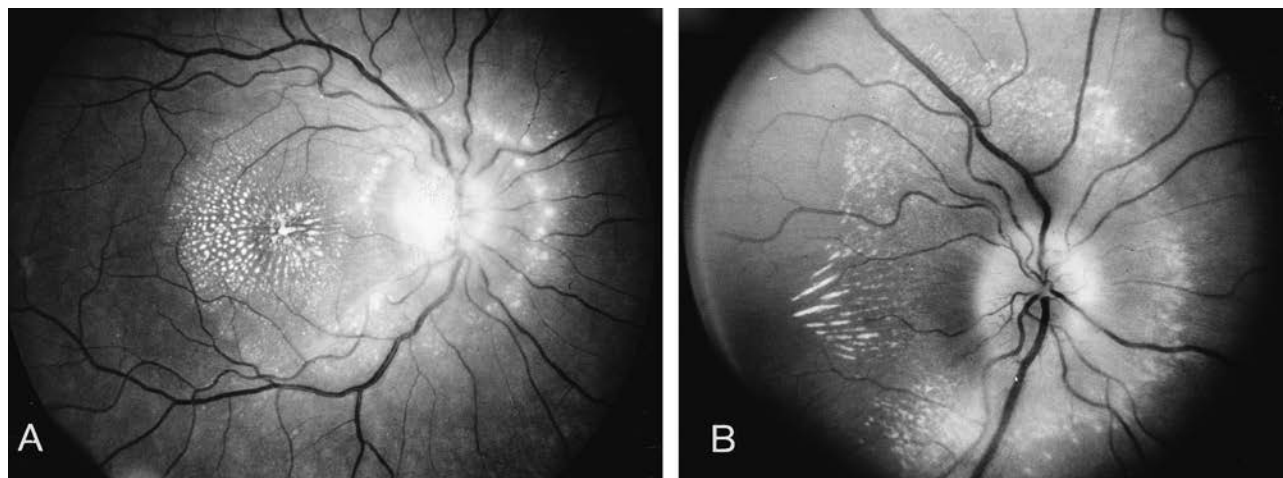


Figure 6.20. Neuroretinitis. *A*, The right optic disc is swollen; there is peripapillary edema; and there is a star figure composed of hard exudate in the macula. This is a form of optic neuritis that is not associated with multiple sclerosis. *B*, In another case, the star figure is incomplete and located nasal but not temporal to the fovea. Note the extensive transudate surrounding the swollen optic disc. (Courtesy of Dr. J.M. Christiansen.)

age, older at presentation with optic neuritis than those who did not develop MS.

We have been impressed with the tendency for optic neuritis in children, whether unilateral or bilateral, to be quite responsive to treatment with systemic corticosteroids and, more importantly, to be quite steroid sensitive. We have seen several children, primarily those with anterior optic neuritis, experience relapses of their condition, some of them quite severe, when steroids were rapidly tapered. It is our policy to evaluate all patients with optic neuritis less than 15 years of age with MR imaging and a lumbar puncture. Unless there

is a contraindication to doing so, we then treat these children with intravenous methylprednisolone 1–2 mg/kg/day for 3–5 days. We do not use an oral corticosteroid taper in these patients.

Gass (469) and Rush (591) emphasized that both children and adults can develop acute, usually unilateral, visual loss associated with an ophthalmoscopic picture of disc swelling, peripapillary exudative retinal detachment, and a macular star figure (Fig. 6.20). This type of ophthalmoscopic appearance has been called neuroretinitis (discussed later).

NEURORETINITIS

In 1916, Theodore Leber described a condition characterized by acute unilateral visual loss associated with an exudative maculopathy consisting of hard exudates arranged in a star figure around the fovea. Leber (592) believed that the condition was a primary retinal process and called it a “stellate maculopathy.” The condition subsequently became known as Leber’s stellate maculopathy (593) until 1977, when Gass (469) reported that patients with the condition showed swelling of the optic disc before and often concurrent with the appearance of the star figure. The optic disc swelling then resolved, leaving the maculopathy as the primary or sole ophthalmoscopic abnormality. Gass (469) performed fluorescein angiography in several of the patients with this condition and showed that there was no leakage from retinal vessels surrounding the macula. He thus concluded that the condition was not a primary maculopathy, but rather a form of optic neuritis. Because the condition affected both the optic nerve and the retina, he called it neuroretinitis. Gass (469) emphasized that the condition occurred commonly in children and young adults, up to 50%

of whom had an antecedent viral illness, usually affecting the respiratory tract, a few weeks before the onset of visual symptoms. It has subsequently become clear that some cases of neuroretinitis are associated with particular infectious diseases, whereas others occur as apparently isolated phenomena (594,595). In the latter setting, the condition is called Leber’s idiopathic stellate neuroretinitis (594,596–599).

Neuroretinitis affects persons of all ages, although it occurs most often in the third and fourth decades of life. There is no sex predilection. The condition usually is painless, but some patients complain of an aching sensation behind the affected eye or eyes, and the discomfort occasionally worsens with eye movements. Affected patients complain of visual blurring that progresses as the maculopathy evolves. Visual acuity at the time of initial examination may range from 20/20 to light perception. We have never seen a patient who lost all perception of light during this condition. Color vision is variably affected, and we have the impression that the degree of color deficit is usually significantly worse than the degree of visual loss would suggest. The most common

field defect is a cecentral scotoma, but central scotomas, arcuate defects, and even altitudinal defects may be present, and the peripheral field may be nonspecifically constricted. A relative afferent pupillary defect is present in most patients, unless the condition is bilateral, in which case even patients with clinically asymmetric visual loss may have no evidence of a relative afferent pupillary defect. The degree of disc swelling ranges from mild to severe, depending in part on the point in time at which the patient is first examined. In severe cases, splinter hemorrhages may be present. Segmental disc swelling has been reported but is uncommon. A macular star figure composed of lipid (hard exudates) may not be present when the patient is examined soon after visual symptoms begin, but it becomes apparent within days to weeks and tends to become more prominent even as the optic disc swelling is resolving (469,504,594,595) (Fig. 6.21).

Small, discrete chorioretinal lesions may occur in idiopathic cases in both symptomatic and asymptomatic eyes (594–596,600). Posterior inflammatory signs consisting of vitreous cells and venous sheathing, as well as occasional anterior chamber cell and flare, may occur in patients with neuroretinitis. Fluorescein angiography in patients with acute neuroretinitis demonstrates diffuse disc swelling and leakage of dye from vessels on the surface of the discs (469). The retinal vessels may show slight staining in the peripapillary region; however, the macular vasculature is entirely normal. Chorioretinal lesions, when present, show late hyperfluorescence and exhibit progressive scarring on follow-up examinations (594,595).

Neuroretinitis is a self-limited disorder. With time, usually over 6–8 weeks, the optic disc swelling resolves, and the appearance of the disc becomes normal or nearly so

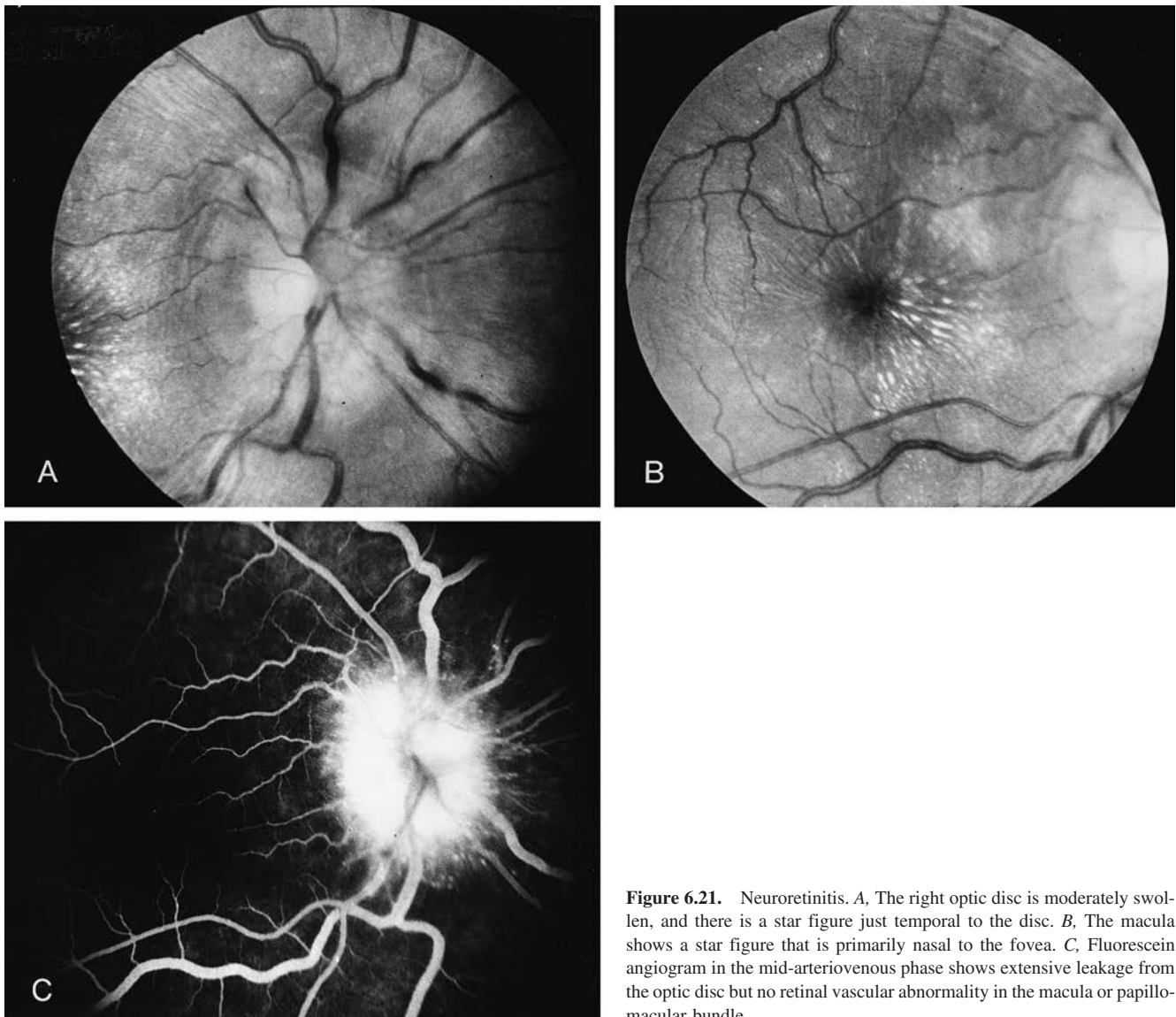


Figure 6.21. Neuroretinitis. *A*, The right optic disc is moderately swollen, and there is a star figure just temporal to the disc. *B*, The macula shows a star figure that is primarily nasal to the fovea. *C*, Fluorescein angiogram in the mid-arteriovenous phase shows extensive leakage from the optic disc but no retinal vascular abnormality in the macula or papillo-macular bundle.

(469,504,594,595). The macular exudates progress over about 7–10 days. They then remain stable for several weeks before gradual resolution occurs. Resolution may take 6–12 months, but the lipid eventually completely disappears. Most patients ultimately recover good visual acuity, although some complain of persistent metamorphopsia or nonspecific blurred vision from mild disruption of the macular architecture despite disappearance of the macular exudates. Ophthalmoscopy and fluorescein angiography usually reveal defects in the retinal pigment epithelium of the macula in such cases. Rare patients develop moderate to severe visual loss, and we have seen one patient who had bilateral loss of vision down to 20/400 OU. Such patients invariably have evidence of optic atrophy.

Most patients who develop neuroretinitis do not experience a subsequent attack in the same eye, and only a few patients who have experienced an attack in one eye subsequently develop a similar attack in the fellow eye. Nevertheless, we have examined several patients who had recurrent episodes of neuroretinitis in one or both eyes. Such patients almost always suffer significant visual loss associated with optic atrophy and permanent macular pigmentary disturbances.

Neuroretinitis is thought to be an infectious or immune-mediated process that may be precipitated by a number of different agents. A common association is with an antecedent viral syndrome, suggesting a possible viral etiology for up to 50% of cases; however, viruses are rarely cultured from the CSF of such patients, and serologic evidence of a concomitant viral infection is usually lacking (469,594,595). One case of neuroretinitis associated with herpes simplex encephalitis was reported by Johnson and Wisetzley (601), as was a case of bilateral neuroretinitis associated with serologic evidence of hepatitis B virus infection (602). Foster et al. (311) reported a case of neuroretinitis that occurred in association with mumps in a young man, and Margolis et al. (603) reported the occurrence of an “arcuate neuroretinitis” associated with optic disc swelling in a patient with the acute retinal necrosis syndrome, a condition thought to be caused by one or more of the herpes viruses (see Chapter 57).

Neuroretinitis may occur in patients with evidence of infectious disease caused by organisms other than viruses. Gass (469) described neuroretinitis associated with cat-scratch disease, a systemic infection caused by the bacterium *Bartonella henselae* (see Chapter 49). Since then, numerous similar cases of neuroretinitis have been described in patients with clinical manifestations consistent with cat scratch disease (470,594,600,604), some of whom have had positive cat scratch antigen and antibody testing (604–606). In our experience, cat scratch disease is the most common infectious process associated with neuroretinitis. The vitreoretinal manifestations include anterior uveitis, vitritis, pars planitis, focal retinal vasculitis, a characteristic retinal white spot syndrome, *Bartonella* retinitis, branch retinal arteriolar or venular occlusions, focal choroiditis, serous retinal detachments, and peripapillary angiomatous lesions. The pattern of ocular disease in AIDS-associated *B. henselae* infections is poorly

delineated; unusual manifestations include conjunctival and retinal bacillary angiomatosis.

Other common infections that cause neuroretinitis are the spirochetes. Neuroretinitis frequently occurs in patients with secondary and tertiary (late) syphilis. It may develop in patients with secondary syphilis as part of the syndrome of syphilitic meningitis (607). In such cases, it is usually bilateral and associated with evidence of meningeal irritation and multiple cranial neuropathies. It may also occur as an isolated phenomenon in patients with secondary syphilis, in which case it is often associated with uveitis and may be either unilateral or bilateral (607–614). Neuroretinitis occasionally occurs in patients with late syphilis, usually in patients with meningovascular neurosyphilis (607). The condition is indistinguishable from that which occurs in patients with secondary syphilis.

Lyme disease is another spirochete that is associated with neuroretinitis. Almost all cases occur in patients with stage II Lyme disease (534,617). Like the neuroretinitis that occurs in syphilis, the neuroretinitis of Lyme disease may be unilateral or bilateral; when bilateral, it is usually simultaneous and symmetric. Also like the neuroretinitis of syphilis, the neuroretinitis that occurs in Lyme disease may recover spontaneously but also resolves rapidly once the patient is treated with appropriate antibiotics (607).

Leptospira were identified in the CSF in one of three patients with neuroretinitis who all had unilateral visual loss and bilateral small, deep, intraretinal lesions consistent with septic retinitis (594). The patient in whom the leptospira were detected had no evidence of leptospirosis. No infectious agent was identified in blood or CSF in the remaining two patients.

Patients with toxoplasmosis, toxocariasis, and histoplasmosis may develop an acute anterior optic neuritis that, in rare cases, may be associated with a macular star figure (560,566,568,618–621). Whether such conditions are truly examples of neuroretinitis is unclear. We believe that any presumed or known inflammatory or infectious optic neuropathy that is characterized by optic disc swelling and the eventual development of a macular star figure should be defined as neuroretinitis; thus, these cases would fit that description. On the other hand, there are noninfectious and noninflammatory conditions that should not be called neuroretinitis even though they are characterized by optic disc swelling that may on occasion be associated with the development of a macular star figure. These mimicking conditions include papilledema, anterior ischemic optic neuropathy, and infiltration of the optic disc by tumor. Systemic hypertension may cause both optic disc swelling and a macular star figure, but fluorescein angiography in such cases shows leakage from macular vessels. A similar phenomenon may occur in the condition called diffuse unilateral subacute neuroretinitis, thought to be caused by one or more types of helminths (see Chapter 51).

One condition that is not associated with neuroretinitis is MS. One might assume that since neuroretinitis is a form of optic neuritis, the likelihood of developing MS after an attack of neuroretinitis would be as high as it seems to be after an attack of straightforward optic neuritis. In fact, although

the rate of development of MS after an attack of anterior or retrobulbar optic neuritis is substantial (discussed previously), there is no increased tendency for patients who experience an attack of neuroretinitis to develop MS (622), and the rate of development of MS in such patients is the same as that in the normal population, about 6–80 per 100,000. Thus, the designation of an attack of acute optic neuropathy as an episode of neuroretinitis rather than anterior optic neuritis substantially alters the systemic prognosis in the patient being evaluated.

Investigation into the etiology of neuroretinitis should be done systematically. A careful history is crucial and should include questioning regarding sexually transmitted diseases, skin rashes, and viral exanthema. Complete physical and ocular examinations are also essential, and a neurologic examination may be required.

Patients with cat scratch fever usually have a history of contact with a cat. They complain of malaise, fever, muscle aches, and headache. Examination typically reveals local lymphadenopathy. Rare patients also have symptoms of arthritis, hepatitis, meningitis, or encephalitis.

Patients with secondary or tertiary syphilis usually provide a history of previous sexual contact, and they may have had a chancre in the past. They may also complain of arthralgias and myalgias, and some have symptoms of meningitis or encephalopathy. Many of these patients have been treated for syphilis or some other sexually transmitted disease in the past.

Patients with stage II Lyme disease usually live or work in an endemic area and may even give a history of a tick bite within the last 6 months. They often have cutaneous, cardiac, or neurologic manifestations in addition to visual complaints. The most common cutaneous manifestation is a solitary red or violaceous abnormality that ranges in size from a small nodule to a plaque several centimeters in diameter. The lesion is called a "lymphocytoma" or "lymphadenosis benigna cutis." It may appear at the site of the tick bite or remote from it. Typical remote sites are the earlobe in children and the nipple in adults. Cardiac manifestations occur in about 5–8% of patients with stage II Lyme disease. Neurologic manifestations occur in 10–15% of cases of stage II Lyme disease and include meningitis, myelitis, encephalitis, cranial neuropathies, meningoradiculitis, and peripheral neuropathies. Some patients with neuroretinitis caused by Lyme disease have other ocular disturbances, including unilateral or bilateral granulomatous iridocyclitis, choroiditis, pars planitis, vitritis, and panophthalmitis. Intraocular vascular disturbances, such as retinal perivasculitis, branch retinal artery occlusion, recurrent vitreous hemorrhage, sheathing of retinal vessels, and intraretinal hemorrhages, are also common in such patients. Fluorescein angiography may reveal areas of nonperfusion in one or both eyes in such patients.

Specific patients may require lumbar puncture, MR imaging or CT scanning, and serologic tests for syphilis, Lyme disease, toxoplasmosis, histoplasmosis, or toxocariasis, whereas others should undergo antibody testing for cat scratch disease. The use of molecular biologic techniques to identify viral nucleic acids in various body tissues and fluids

may eventually result in identification of specific viruses that cause the condition in otherwise normal persons or in persons who have recently suffered what seems to be a viral illness. At this time, however, we cannot recommend that such techniques be used on a regular basis, since they are both time-consuming and expensive and the therapeutic implications may be nil. Patients in whom neuroretinitis is accompanied by diffuse retinal or choroidal lesions suggesting septic retinitis or choroiditis may require a complete evaluation for systemic infection (600).

Treatment of neuroretinitis depends on whether there is an underlying infectious or inflammatory condition that requires therapy. *B. henselae* is the principal cause of cat scratch disease (623,624). The availability of specific serologic investigations has allowed the recognition of a spectrum of ocular cat scratch disease syndromes that previously were ill defined and considered idiopathic. The benefit of antimicrobial therapy for cat scratch disease in immunocompetent individuals has been difficult to establish, partly because most infections are self-limited. Empirically, azithromycin, ciprofloxacin, rifampin, parenteral gentamicin, and trimethoprim-sulfamethoxazole are the best therapeutic choices to minimize damage to the eye. Such treatment is almost always associated with improvement of the associated neuroretinitis, although whether the neuroretinitis would resolve spontaneously without treatment is unknown (470,600,623,624). Patients with neuroretinitis who are found to have secondary or late syphilis should be treated with intravenous penicillin as recommended by the Centers for Disease Control and Prevention (625), and patients with neuroretinitis that occurs in the setting of Lyme disease should also be treated with appropriate antibiotics, such as ceftriaxime, amoxicillin, or tetracycline (534). Patients in whom neuroretinitis is found to be associated with evidence of toxoplasmosis, toxocariasis, or histoplasmosis should likewise undergo treatment specific for their underlying systemic disease.

Patients with presumed viral or idiopathic neuroretinitis may or may not require treatment. Some authors advocate the use of systemic corticosteroids or ACTH to treat isolated neuroretinitis, but there is no definite evidence that such treatment alters either the speed of recovery of the condition or the ultimate outcome. Interestingly, Weiss and Beck (600) reported a case of idiopathic neuroretinitis that did not respond to treatment with oral prednisone but that improved rapidly and dramatically when intravenous corticosteroids were given.

As noted above, the ultimate prognosis for most cases of Leber's idiopathic neuroretinitis is excellent. Most patients achieve good visual recovery, although a subgroup of patients develop optic atrophy and poor vision. These patients typically have very poor visual acuity from the beginning of the process, significant visual field loss at presentation, and a marked, relative afferent pupillary defect if the condition is unilateral or asymmetric (595). Nevertheless, even patients who present with profound loss of visual function may recover normal or near-normal vision over time. Recurrent neuroretinitis may occur in rare cases (626).

OPTIC PERINEURITIS (PERIOPTIC NEURITIS)

Perioptic neuritis is a condition in which only the periphery of the optic nerve is inflamed. Edmunds and Lawford (627) initially described optic perineuritis as occurring in two forms: exudative and purulent. The exudative form, representing a localized, nonsuppurative pachymeningitis, occurs infrequently, most often in association with syphilis,

sarcoidosis, and viral encephalitides (628–632). The purulent form, actually a leptomeningitis, arises as an extension from the cerebral meninges. Pathologically, the pia and arachnoid are infiltrated by polymorphonuclear leukocytes that are also found free in the subarachnoid space surrounding the optic nerve (Fig. 6.22). From the leptomeninges, the

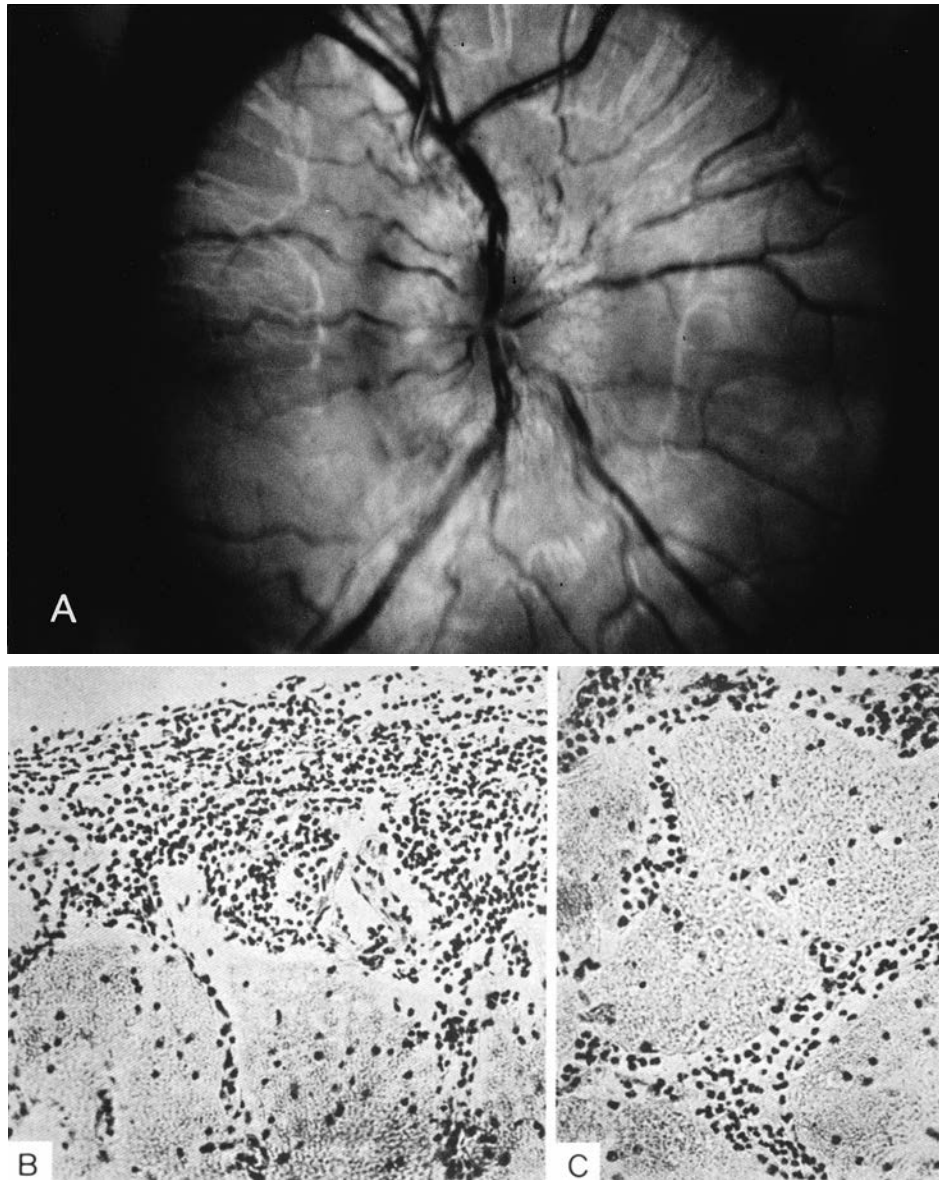


Figure 6.22. Optic perineuritis. *A*, The optic disc is hyperemic and swollen (as was the left disc). The patient was a 15-year-old boy complaining of a headache and stiff neck. He had a moderate fever. Visual acuity was 20/15 in both eyes, color vision was normal, and visual fields were full. The patient was believed to have papilledema. A lumbar puncture, however, revealed normal intracranial pressure, an increased concentration of protein in the CSF, and a significant CSF lymphocytosis. *B*, Histologic appearance of optic perineuritis in a case of fatal meningitis. Polymorphonuclear leukocytes (PMNs) are infiltrating the leptomeninges surrounding the optic nerve and are present in the subarachnoid space. *C*, Magnified view of affected area of peripheral optic nerve. PMNs extend from the pia in the septal system deep into the nerve. There is no invasion of the nerve tissue, however. (Specimen courtesy of Dr. S.T. Orion.)

infiltration may spread into the substance of the optic nerves without at first affecting the nerve fibers themselves.

Purvin et al. (633) reviewed the medical records of 14 patients with optic perineuritis who were seen in two neuro-ophthalmology clinics. The patients ranged in age from 24 to 60 years; 5 were older than 50 years. All patients had visual loss, eye pain, or both. The visual acuity was 20/20 or better in 8 of the 15 eyes. The results of visual field testing were normal in two eyes, and a paracentral scotoma or an arcuate defect was seen in seven. MR imaging demonstrated circumferential enhancement around the optic nerve, sometimes with intraorbital extension. Response to corticosteroids was dramatic; however, four patients had a relapse with lowering of the dose. The authors concluded that in contrast to those with optic neuritis, patients with optic perineuritis are often older at onset and are more likely to show sparing of central vision. MR imaging demonstrates enhancement around, rather than within, the optic nerve. Response to corticosteroids is more dramatic than in patients with optic neuritis, and patients are more likely to experience recurrence after stopping treatment.

In many cases of optic perineuritis, there are neither ocular symptoms nor signs other than disc swelling, usually bilateral. Apparently, the absence of visual dysfunction occurs because the infiltration is loose and disorganized. When vitreous cells are present, the differentiation from papilledema is easy; however, when there are no intraocular signs of inflammation, it may be necessary to perform neuroimaging and a lumbar puncture for diagnosis. Enlargement of the optic nerve sheath on CT scan may simulate optic nerve sheath meningioma (634), but advanced MR imaging is definitive (633).

REFERENCES

- Nettleship E. On cases of retro-ocular neuritis. *Trans Ophthalmol Soc UK* 1884; 4:186–226.
- Parinaud H. Trouble oculaires de la sclérose en plaques. *J Sante* 1884;3:3–5.
- Uhthoff W. Untersuchungen über die bei der multiplen herdsklerose vorkommenden augenstörungen. *Arch Psychiatr Nervenkr* 1890;21:55–116, 303–410.
- Buzzard T. Atrophy of the optic nerve as a symptom of chronic disease of the central nervous system. *Br Med J* 1893;2:779–784.
- Gunn RM. In discussion on retro-ocular neuritis. *Trans Ophthalmol Soc UK* 1897;17:107–217.
- Beck RW, Optic Neuritis Study Group. The Optic Neuritis Treatment Trial. *Arch Ophthalmol* 1988;106:1051–1053.
- Optic Neuritis Study Group. The clinical profile of acute optic neuritis: experience of the Optic Neuritis Treatment Trial. *Arch Ophthalmol* 1991;109:1673–1678.
- Beck RW, Cleary PA, Anderson MM Jr, et al. A randomized, controlled trial of corticosteroids in the treatment of acute optic neuritis. *N Engl J Med* 1992; 326:581–588.
- Beck RW, Optic Neuritis Study Group. The Optic Neuritis Treatment Trial: implications for clinical practice. *Arch Ophthalmol* 1992;110:331–332.
- Beck RW, Optic Neuritis Study Group. Corticosteroid treatment of optic neuritis: a need to change treatment practices. *Neurology* 1992;42:1133–1135.
- Beck RW, Kupersmith MJ, Cleary PA, et al. Fellow eye abnormalities in acute unilateral optic neuritis: experience of the Optic Neuritis Treatment Trial. *Ophthalmology* 1993;100:691–698.
- Beck RW, Arrington J, Murtagh FR, et al. Brain MRI in acute optic neuritis: experience of the Optic Neuritis Study Group. *Arch Neurol* 1993;8:841–846.
- Beck RW, Cleary PA, Trobe JD, et al. The effect of corticosteroids for acute optic neuritis on the subsequent development of multiple sclerosis. *N Engl J Med* 1993;329:1764–1769.
- Beck RW, Cleary PA, Optic Neuritis Study Group. Optic Neuritis Treatment Trial: one-year follow-up results. *Arch Ophthalmol* 1993;111:773–775.
- Beck RW, Cleary PA, Optic Neuritis Study Group. Recovery from severe visual loss in optic neuritis. *Arch Ophthalmol* 1993;111:300.
- Beck RW, Diehl L, Cleary PA, et al. The Pelli-Robson letter chart: normative data for young adults. *Clin Vis Sci* 1993;8:207–210.
- Cleary PA, Beck RW, Anderson MM Jr, et al. Design, methods and conduct of the Optic Neuritis Treatment Trial. *Control Clin Trials* 1993;14:123–142.
- Beck RW, Cleary PA, Backlund JC, et al. The course of visual recovery after optic neuritis: experience of the Optic Neuritis Treatment Trial. *Ophthalmology* 1994;101:1771–1778.
- Beck RW. The Optic Neuritis Treatment Trial: three-year follow-up results. *Arch Ophthalmol* 1995;113:136–137.
- Beck RW, Trobe JD, Optic Neuritis Study Group. What have we learned from the Optic Neuritis Treatment Trial? *Ophthalmology* 1995;102:1504–1508.
- Beck RW, Trobe JD, Optic Neuritis Study Group. The Optic Neuritis Treatment Trial: putting the results in perspective. *J Neuroophthalmol* 1995;15:131–135.
- Optic Neuritis Study Group. The five-year risk of multiple sclerosis after optic neuritis. Experience of the Optic Neuritis Treatment Trial. *Neurology* 1997;49: 1404–1413.
- Optic Neuritis Study Group. High- and low-risk profiles for the development of multiple sclerosis within 10 years after optic neuritis. *Arch Ophthalmol* 2003; 121:944–949.
- Optic Neuritis Study Group. Visual function more than 10 years after optic neuritis: experience of the Optic Neuritis Treatment Trial. *Am J Ophthalmol* 2004;137:77–83.
- Optic Neuritis Study Group. Neurologic impairment 10 years after optic neuritis. *Arch Neurology* 2004 (in press).
- Optic Neuritis Study Group. Long-term brain MRI changes after optic neuritis in patients without clinically definite multiple sclerosis. *Arch Neurology* 2004 (in press).
- Alter M, Leibowitz U, Speer J. Risk of multiple sclerosis related to age at immigration in Israel. *Arch Neurol* 1996;15:234–237.
- Percy AK, Nobrega FT, Kurland LT. Optic neuritis and multiple sclerosis: an epidemiologic study. *Arch Ophthalmol* 1972;87:135–139.
- Wikström J. The epidemiology of optic neuritis in Finland. *Acta Neurol Scand* 1975;52:167–178.
- Kahana E, Alter M, Feldman S. Optic neuritis in relation to multiple sclerosis. *J Neurol* 1976;213:87–95.
- Haller P, Patzold U, et al. Optic neuritis in Hanover: an epidemiologic and serogenetic study. In: Bauer HJ, Poser S, Ritter G, eds. *Progress in Multiple Sclerosis Research*. New York, Springer, 1980:546–548.
- Kinnunen E. The incidence of optic neuritis and its prognosis for multiple sclerosis. *Acta Neurol Scand* 1983;68:371–377.
- Rodriguez M, Siva A, Cross SA, et al. Optic neuritis: a population-based study in Olmsted County, Minnesota. *Neurology* 1995;45:244–250.
- Hierons R, Lyle TK. Bilateral retrobulbar optic neuritis. *Brain* 1959;82:56–67.
- Kennedy C, Carroll FD. Optic neuritis in children. *Arch Ophthalmol* 1960;63: 747–755.
- Meadows SP. Retrobulbar and optic neuritis in childhood and adolescence. *Trans Ophthalmol Soc UK* 1969;89:603–638.
- Kriss A, Francis DA, Cuendet F, et al. Recovery after optic neuritis in childhood. *J Neurol Neurosurg Psychiatry* 1988;51:1253–1258.
- Rikonen R. The role of infection and vaccination in the genesis of optic neuritis and multiple sclerosis in children. *Acta Neurol Scand* 1989;80:425–431.
- Perkin GD, Rose FC. *Optic Neuritis and Its Differential Diagnosis*. Oxford, UK, Oxford Medical Publications, 1979.
- Kupersmith MJ, Nelson JI, Seiple WH, et al. The 20/20 eye in multiple sclerosis. *Neurology* 1983;33:1015–1020.
- Celesia GG, Kaufman DL, Brigell M, et al. Optic neuritis: a prospective study. *Neurology* 1990;40:919–923.
- Francis DA. Demyelinating optic neuritis: clinical features and differential diagnosis. *Br J Hosp Med* 1991;45:376–379.
- Compston A. Cellular organization of the optic nerve and the implications for optic neuritis. *Eye* 1992;6:123–128.
- McDonald WI, Barnes D. The ocular manifestations of multiple sclerosis. I. Abnormalities of the afferent visual system. *J Neurol Neurosurg Psychiatry* 1992; 55:747–752.
- Rose FC. The aetiology of optic neuritis. In: Cant JS, ed. *The Optic Nerve*. St Louis, CV Mosby, 1972:217–219.
- Swartz NG, Beck RW, Savino PJ, et al. Pain in anterior ischemic optic neuropathy. *J Neuroophthalmol* 1995;15:9–10.
- Lepore FE. The origin of pain in optic neuritis: determinants of pain in 101 eyes with optic neuritis. *Arch Neurol* 1991;48:748–749.
- Swartz NG, Beck RW, Savino PJ, et al. Pain in anterior ischemic optic neuropathy. *J Neuroophthalmol* 1995;15:9–10.
- Traquair HM. Toxic amblyopias, including retrobulbar neuritis. *Trans Ophthalmol Soc UK* 1930;17:107–217.
- Davis FA, Bergen D, Schauf C, et al. Movement phosphenes in optic neuritis: a new clinical sign. *Neurology* 1976;26:1100–1104.
- Cohen M, Lessell S, Wolf P. A prospective study of the risk of developing multiple sclerosis in uncomplicated optic neuritis. *Neurology* 1979;19:208–213.
- Page NGR, Bolger JP, Sanders MD. Auditory evoked phosphenes in optic nerve disease. *J Neurol Neurosurg Psychiatry* 1982;45:7–12.

53. Sanders EA, Volkens AC, Van der Poel JC, et al. Spatial contrast sensitivity function in optic neuritis. *Neuroophthalmology* 1984;4:255–259.
54. Tsukamoto M, Adachi-Usami E. Color vision in multiple sclerosis with optic neuritis. *Acta Soc Ophthalmol Jpn* 1987;91:613–621.
55. Ménage MJ, Papakostopoulos D, Hart JCD, et al. The Farnsworth-Munsell 100 hue test in the first episode of demyelinating optic neuritis. *Br J Ophthalmol* 1993;77:68–74.
56. Trauzettel-Klosinski S, Aulhorn E. Measurement of brightness sensation caused by flickering light: a simple and highly specific test for assessing the florid stage of optic neuritis. *Clin Vis Sci* 1987;2:63–82.
57. Stellberger C, Wetzel W, Duncker G. Comparison between the flicker test procedures of Aulhorn and of Dölle in the diagnosis of optic neuritis. *Graefes Arch Clin Exp Ophthalmol* 1993;231:692–696.
58. Wong L-C, Wakakura M, Ishikawa S. Critical flicker frequency in acute and recovered optic neuritis. *Jpn J Ophthalmol* 1993;37:122–129.
59. Steinmetz R, Kearns TP. H-R-R pseudoisochromatic plates: as a diagnostic aid in retrobulbar neuritis of multiple sclerosis. *Am J Ophthalmol* 1956;41:833–837.
60. Rosen JA. Pseudoisochromatic visual testing in the diagnosis of disseminated sclerosis. *Trans Am Neurol Assoc* 1965;90:283–284.
61. Marre M. The investigation of acquired color deficiencies. Second Congress of the International Color Association, University of York, July 2–6, 1973. London, Adam Hilger Publishers, 1973.
62. Trusiewicz D. Farnsworth 100-hue test in diagnosis of ethambutol-induced damage to optic nerve. *Ophthalmology* 1975;171:425–431.
63. Griffin JF, Wray SH. Acquired color vision defects in retrobulbar neuritis. *Am J Ophthalmol* 1978;86:193–201.
64. Griffith AH. In discussion on retro-ocular neuritis. *Trans Ophthalmol Soc UK* 1897;17:107–217.
65. Gunn RM. Discussion on retro-ocular neuritis. *Br Med J* 1904;2:1285–1287.
66. Berliner MD. Acute optic neuritis in demyelinating diseases of the nervous system. *Arch Ophthalmol* 1935;13:83–98.
67. Carroll FD. Retrobulbar optic neuritis: observations on one hundred cases. *Arch Ophthalmol* 1940;24:44–54.
68. Marshall D. Ocular manifestations of multiple sclerosis and relationship to retrobulbar neuritis. *Trans Am Ophthalmol Soc* 1950;48:487–525.
69. Hyllested K, Møller P. Follow-up patients with a history of optic neuritis. *Acta Ophthalmol* 1961;39:655–662.
70. Miller NR. Walsh and Hoyt's Clinical Neuro-Ophthalmology, 4th ed, vol 1. Baltimore, Williams & Wilkins, 1982:228.
71. Chamlin M. Visual field changes in optic neuritis. *Arch Ophthalmol* 1953;50:699–713.
72. Vighetto A, Grochowicki M, Aimard G. Altitudinal hemianopia in multiple sclerosis. *Neuroophthalmology* 1991;11:25–27.
73. Keltner JL, Johnson CA, Spurr JO, et al. Baseline visual field profile of optic neuritis: the experience of the Optic Neuritis Treatment Trial. *Arch Ophthalmol* 1993;111:231–234.
74. Nikoskelainen E, Nikoskelainen J, Salmi AA, et al. Virus antibody levels in serum specimens from patients with optic neuritis and from matched controls. *Acta Neurol Scand* 1975;51:333–346.
75. Stanley JA, Baise G. The swinging flashlight test to detect minimal optic neuropathy. *Arch Ophthalmol* 1968;80:769–771.
76. Thompson HS. Pupillary signs in the diagnosis of optic nerve disease. *Trans Ophthalmol Soc UK* 1976;96:377–381.
77. Ellis CK. The afferent pupillary defect in acute optic neuritis. *J Neurol Neurosurg Psychiatry* 1979;42:1008–1017.
78. Cox TA, Thompson HS, Corbett JJ. Relative afferent pupillary defects in optic neuritis. *Am J Ophthalmol* 1981;92:685–690.
79. Paton J. Papilloedema in disseminated sclerosis. *Trans Ophthalmol Soc UK* 1914;34:252–261.
80. Adie WJ. The aetiology and symptomatology of disseminated sclerosis. *Br Med J* 1932;2:997–1000.
81. Benedict WL. Multiple sclerosis as an etiologic factor in retrobulbar neuritis. *Arch Ophthalmol* 1942;28:988–995.
82. Bradley WG, Whitty CM. Acute optic neuritis: its clinical features and their relation to prognosis for recovery of vision. *J Neurol Neurosurg Psychiatry* 1967;30:531–538.
83. Hutchinson WM. Acute optic neuritis and the prognosis for multiple sclerosis. *J Neurol Neurosurg Psychiatry* 1976;39:283–289.
84. Lightman S, McDonald WI, Bird AC, et al. Retinal venous sheathing in optic neuritis: its significance for the pathogenesis of multiple sclerosis. *Brain* 1987;110:405–414.
85. Birch MK, Barbosa S, Blumhardt LD, et al. Retinal venous sheathing and the blood-retinal barrier in multiple sclerosis. *Arch Ophthalmol* 1966;114:34–39.
86. Arden GB, Gucukoglu AG. Grating test of contrast sensitivity in patients with retrobulbar neuritis. *Arch Ophthalmol* 1978;96:1626–1629.
87. Froehlich J, Kaufman DI. Use of pattern electroretinography to differentiate acute optic neuritis from acute anterior ischemic optic neuropathy. *Electroencephalograph Clin Neurophysiol* 1994;92:480–486.
88. Beck RW, Ruchman MC, Savino PJ, et al. Contrast sensitivity measurements in acute and resolved optic neuritis. *Br J Ophthalmol* 1984;68:756–759.
89. Sanders EA, Volkens AC, Van der Poel JC, et al. Estimation of visual function after optic neuritis: a comparison of clinical tests. *Br J Ophthalmol* 1986;70:918–924.
90. Fleishman JA, Beck RW, Linares OA, et al. Deficits in visual function after resolution of optic neuritis. *Ophthalmology* 1987;94:1029–1035.
91. Howard CW, Osher RH, Tomsak RL. Computed tomographic features in optic neuritis. *Am J Ophthalmol* 1980;89:699–702.
92. Miller NR, Savino PJ, Schneider T. Rapid growth of an intracranial aneurysm causing apparent retrobulbar optic neuritis. *J Neuroophthalmol* 1995;15:212–218.
93. Rolak LA, Beck RB, Paty DW, et al. Cerebrospinal fluid in acute optic neuritis: Experience of the Optic Neuritis Study Group. *Neurology* 1996;46:368–372.
94. Link H, Norrby E, Olsson J-E. Immunoglobulins and measles antibodies in optic neuritis. *N Engl J Med* 1973;289:1103–1107.
95. Arnason BW, Fuller TC, Lehigh J, et al. Histocompatibility types and measles antibodies in multiple sclerosis and optic neuritis. *J Neurol Sci* 1974;22:419–428.
96. Miller DH, Ormerod IEC, McDonald WI, et al. The early risk of multiple sclerosis after optic neuritis. *J Neurol Neurosurg Psychiatry* 1988;51:1569–1571.
97. Guy J, Mancuso A, Quisling RG, et al. Gadolinium-DTPA-enhanced magnetic resonance imaging in optic neuropathies. *Ophthalmology* 1990;97:592–600.
98. Youl BD, Turano G, Miller DH, et al. The pathophysiology of acute optic neuritis: an association of gadolinium leakage with clinical and electrophysiological deficits. *Brain* 1991;114:2437–2450.
99. Guy J, Mao J, Bidgood WD Jr, et al. Enhancement and demyelination of the intraorbital optic nerve: fat suppression magnetic resonance imaging. *Ophthalmology* 1992;99:713–719.
100. Frederiksen JL, Larsson HBW, Henriksen O, et al. Magnetic resonance imaging of the brain in patients with acute monosymptomatic optic neuritis. *Acta Neurol Scand* 1989;80:512–517.
101. Jacobs L, Munschauer FE, Kaba SE. Clinical and magnetic resonance imaging in optic neuritis. *Neurology* 1991;41:15–19.
102. Sandberg-Wollheim M, Bynke H, Cronqvist S, et al. A long-term prospective study of optic neuritis: evaluation of risk factors. *Ann Neurol* 1990;27:386–393.
103. Frederiksen JL, Larsson HBW, Oleson J. Correlation of magnetic resonance imaging and CSF findings in patients with acute monosymptomatic optic neuritis. *Acta Neurol Scand* 1992;86:317–322.
104. Tourtellotte WW, Tuman H. Multiple sclerosis. Cerebrospinal fluid. In: Raine CS, McFarland HF, Tourtellotte WW, eds. *Multiple Sclerosis: Clinical and Pathogenetic Basis*. London, Chapman and Hall, 1997:57–59.
105. Söderström M, Lindqvist M, Hiller J, et al. Optic neuritis: findings on MRI, CSF examination and HLA class II typing in 60 patients and results of a short-term follow-up. *J Neurol* 1994;241:391–397.
106. Sandberg M, Bynke H. Cerebrospinal fluid in 25 cases of optic neuritis. *Acta Neurol Scand* 1973;49:442–452.
107. Nikoskelainen E, Irjala K, Salmi TT. Cerebrospinal fluid findings in patients with optic neuritis. *Acta Ophthalmol* 1975;53:105–119.
108. Sandberg-Wollheim M, Platz P, Ryder LP, et al. HL-A histocompatibility antigens in optic neuritis. *Acta Neurol Scand* 1975;52:161–166.
109. Nyland H, Naess A, Slagsvold JE. Lymphocyte subpopulations in peripheral blood and cerebrospinal fluid from patients with acute optic neuritis. *Acta Ophthalmol* 1980;58:411–417.
110. Rudick RA, Jacobs L, Kinkel PR, et al. Isolated idiopathic optic neuritis: analysis of free kappa-light chains in cerebrospinal fluid and correlation with nuclear magnetic resonance findings. *Arch Neurol* 1986;43:456–458.
111. Staugaitis S, Shapshak P, Tourtellotte W, et al. Isoelectric focusing of unconcentrated cerebrospinal fluid: application to ultrasensitive analysis of oligoclonal immunoglobulin-G. *Electrophoresis* 1985;6:287–291.
112. Poser CM, Paty D, Scheinberg L, et al. New diagnostic criteria for multiple sclerosis: guidelines for research protocols. *Ann Neurol* 1983;13:227–231.
113. Frick E, Stickl H. Optic neuritis and multiple sclerosis: an immunological study. *Eur Neurol* 1980;19:185–191.
114. Söderström M, Link H, Xu Z, et al. Optic neuritis and multiple sclerosis: anti-MBP and anti-MBP peptide antibody-secreting cells are accumulated in CSF. *Neurology* 1993;43:1215–1222.
115. Feasby TE, Ebers GC. Risk of multiple sclerosis in isolated optic neuritis. *Can J Neurol Sci* 1982;9:269.
116. Link H, Stendahl-Brodin L. Optic neuritis and multiple sclerosis. *N Engl J Med* 1983;308:1294–1295.
117. Stendahl-Brodin L, Link H. Optic neuritis: oligoclonal bands increase the risk of multiple sclerosis. *Acta Neurol Scand* 1983;67:301–304.
118. Anmarkrud N, Slettnes ON. Uncomplicated retrobulbar neuritis and the development of multiple sclerosis. *Acta Ophthalmol* 1989;67:306–309.
119. Deckert-Schlüter M, Schlüter D, Schwendemann G. Evaluation of IL-2, sIL2R, IL-6, TNF- α , and IL-1 β in serum and CSF of patients with optic neuritis. *J Neurol Sci* 1992;113:50–54.
120. Link J, Söderström M, Kostulas V, et al. Optic neuritis is associated with myelin basic protein and proteolipid protein reactive cells producing interferon-gamma, interleukin-4, and transforming growth factor-beta. *J Neuroimmunol* 1994;49:9–18.
121. Oksenberg JR, Seboun E, Hauser SL. Genetics of demyelinating diseases. *Brain Pathol* 1996;6:289–302.

122. Spielman RS, Nathanson N. The genetics of susceptibility to multiple sclerosis. *Epidemiol Rev* 1982;4:45–65.
123. Ebers GC, Bulman DE, Sadovnick AD, et al. A population-based study of multiple sclerosis in twins. *N Engl J Med* 1986;315:1638–1642.
124. Sandberg-Wollheim M. Studies on the cerebrospinal fluid in relation to clinical course in 61 patients. *Acta Neurol Scand* 1975;52:167–178.
125. Compston DA, Batchelor JR, Earl CJ, et al. Factors influencing the risk of multiple sclerosis developing in patients with optic neuritis. *Brain* 1978;101:495–511.
126. Matthews WB, Acheson ED, Batchelor JR, et al, eds. *McAlpine's Multiple Sclerosis*. Edinburgh, Churchill Livingstone, 1985.
127. Kelly MA, Cavan DA, Penny MA, et al. The influence of HLA-DR and -DQ alleles on progression to multiple sclerosis following a clinically isolated syndrome. *Hum Immunol* 1993;37:185–191.
128. Tiwari JL, Terasaki PI. *HLA and Disease Associations*. New York, Springer-Verlag, 1985.
129. Hauser SL, Fleischnick E, Weiner HL, et al. Extended major histocompatibility complex haplotypes in patients with multiple sclerosis. *Neurology* 1989;39:275–277.
130. Francis DA, Compston DAS, Batchelor JR, et al. A reassessment of the risk of multiple sclerosis developing in patients with optic neuritis after extended follow-up. *J Neurol Neurosurg Psychiatry* 1987;50:758–765.
131. Marcadet A, Massart C, Semana G, et al. Association of class II HLA-DQB chain DNA restriction fragments with multiple sclerosis. *Immunogenetics* 1985;22:93–96.
132. Olerup O, Hillert J, Frederickson S, et al. Primary chronic progressive and relapsing/remitting multiple sclerosis: two immunogenetically distinct disease entities. *Proc Natl Acad Sci USA* 1989;86:7113–7117.
133. Vartdal F, Sollid LM, Vandvik B, et al. Patients with multiple sclerosis carry DQB1 genes which encode shared polymorphic amino acid sequences. *Hum Immunol* 1989;25:103–110.
134. Hillert J, Käll T, Olerup O, et al. Distribution of HLA-Dw2 in optic neuritis and multiple sclerosis indicates heterogeneity. *Acta Neurol Scand* 1996;94:161–166.
135. Hely MA, McManis PG, Doran TJ, et al. Acute optic neuritis: a prospective study of risk factors for multiple sclerosis. *J Neurol Neurosurg Psychiatry* 1986;49:1125–1130.
136. Oksenberg JR, Seboun E, Hauser SL. Genetics of demyelinating diseases. *Brain Pathol* 1996;6:289–302.
137. Kira J, Kanai T, Nishimura Y, et al. Western versus Asian types of multiple sclerosis: two immunogenetically and clinically distinct patient groups. *Ann Neurol* 1996;40:569–574.
138. Muntoni F, Murru MR, Costa G, et al. Different HLA-DR2-DQW1 haplotypes in Sardinian and northern Italian populations: implications for multiple sclerosis susceptibility. *Tissue Antigens* 1991;38:34–36.
139. Haines JL, Terwedow HA, Burgess K, et al. Linkage of the MHC to familial multiple sclerosis suggests genetic heterogeneity. *Multiple Sclerosis Genetic Group*. *Hum Mol Genet* 1998;7:1229–1234.
140. Hauser SL, Oksenberg JR, Lincoln R, et al. Interaction between HLA-DR2 and abnormal brain MRI in optic neuritis and early MS. *Neurology* 2000;54:1859–1861.
141. Soderstrom M, Ya-Ping J, Hillert J, Link H. Optic neuritis: prognosis for multiple sclerosis from MRI, CSF, and HLA findings. *Neurology* 1998;50:708–714.
142. Ozawa K, Suchanek G, Breitschopf H, et al. Patterns of oligodendroglia pathology in multiple sclerosis. *Brain* 1994;117:1311–1322.
143. Genain CP, Cannella B, Hauser SL, Raine CS. Identification of autoantibodies associated with tissue damage in multiple sclerosis. *Nat Med* 1999;5:170–175.
144. Thompson AJ, Polman CH, Miller DH, et al. Primary progressive multiple sclerosis. *Brain* 1997;120:1085–1096.
145. Jacobs L, Kinkel PR, Kinkel WR. Silent brain lesions in patients with isolated idiopathic optic neuritis: a clinical and nuclear magnetic resonance imaging study. *Arch Neurol* 1986;43:452–455.
146. Hornabrook RSL, Miller DH, Newton MR, et al. Frequent involvement of the optic radiation in patients with acute isolated optic neuritis. *Neurology* 1992;42:77–79.
147. Frederiksen J, Larsson HBW, Olesen J, et al. MRI, VEP, SEP and biothesiometry suggest monosymptomatic acute optic neuritis to be a first manifestation of multiple sclerosis. *Acta Neurol Scand* 1991;83:343–350.
148. Frederiksen J, Larsson HBW, Nordenbo AM, et al. Plaques causing hemianopsia or quadrantanopsia in multiple sclerosis identified by MRI and VEP. *Acta Ophthalmol* 1991;69:169–177.
149. Martinelli V, Comi G, Filippi M, et al. Paraclinical tests in acute-onset optic neuritis, basal data and results of a short follow-up. *Acta Neurol Scand* 1991;84:231–236.
150. Morrissey SP, Miller DH, Kendall BE, et al. The significance of brain magnetic resonance imaging abnormalities at presentation with clinically isolated syndromes suggestive of multiple sclerosis. *Brain* 1993;116:135–146.
151. Frohman EM, Goodin DS, Calabresi PA, et al. The utility of MRI in suspected MS: report of the Therapeutics and Technology Assessment Subcommittee of the American Academy of Neurology. *Neurology* 2003;61:602–611.
152. McDonald WI, Compston A, Edan G, et al. Recommended diagnostic criteria for multiple sclerosis: guidelines from the International Panel on the Diagnosis of Multiple Sclerosis. *Ann Neurol* 2001;50:121–127.
153. Braude LS, Cunha-Vaz JG, Frenkel M. Diagnosing acute retrobulbar neuritis by vitreous fluorophotometry. *Am J Ophthalmol* 1981;91:764–773.
154. Hench PS, Kendall EC, et al. The effect of a hormone of the adrenal cortex (17-hydroxy-11-dehydrocorticosterone: compound E) and of pituitary adrenocorticotropic hormone on rheumatoid arthritis. *Proc Staff Meet Mayo Clin* 1949;24:181–197.
155. Rawson MD, Liversedge LA, Goldfarb G. Treatment of acute retrobulbar neuritis with corticotrophin. *Lancet* 1966;2:1044–1046.
156. Rawson MD, Liversedge LA. Treatment of retrobulbar neuritis with corticotrophin. *Lancet* 1969;2:222.
157. Cooperative study in the evaluation of therapy in multiple sclerosis: ACTH vs. placebo-final report. *Neurology* 1970;20:1–59.
158. Bowden AN, Bowden PMA, Friedmann AI, et al. A trial of corticotrophin gelatin injection in acute optic neuritis. *J Neurol Neurosurg Psychiatry* 1974;37:869–873.
159. Gould ES, Bird AC, Leaver PK, et al. Treatment of optic neuritis by retrobulbar injection of triamcinolone. *Br Med J* 1977;1:1495–1497.
160. Trauzettel-Klosinski S, Axmann D, Aulhorn E, et al. The Tübingen study on optic neuritis treatment: a prospective, randomized and controlled trial. *Clin Vision Sci* 1993;8:385–394.
161. Spoor TC. Treatment of optic neuritis with megadose corticosteroids. *J Clin Neuroophthalmol* 1986;6:137–143.
162. Spoor TC, Rockwell DL. Treatment of optic neuritis with intravenous megadose corticosteroids: a consecutive series. *Ophthalmology* 1988;95:131–134.
163. Raine CS, Traugott U. Chronic relapsing experimental autoimmune encephalomyelitis: ultrastructure of the central nervous system of animals treated with combination of myelin components. *Lab Invest* 1982;48:275–284.
164. Traugott U, Stone SH, Raine CS. Chronic relapsing experimental autoimmune encephalomyelitis treatment with combinations of myelin components promotes clinical and structural recovery. *J Neurol Sci* 1982;56:65–73.
165. Raine CS, Hintzen R, Traugott U, et al. Oligodendrocyte proliferation and enhanced CNS remyelination after therapeutic manipulation of chronic relapsing EAE. *Ann NY Acad Sci* 1988;540:712–714.
166. Rodriguez M, Lennon VA, Benveniste EN. Remyelination by oligodendrocytes stimulated by antiserum to spinal cord. *J Neuropathol Exp Neurol* 1987;46:84–95.
167. Rodriguez M, Lennon VA. Immunoglobulins promote remyelination in the central nervous system. *Ann Neurol* 1990;27:12–17.
168. Miller DJ, Sanborn KS, Katzmann JA, et al. Monoclonal autoantibodies promote central nervous system repair in an animal model of multiple sclerosis. *J Neurosci* 1994;14:6230–6238.
169. van Engelen BGM, Miller DJ, Pavelko KD, et al. Promotion of remyelination by polyclonal immunoglobulin and IVIg in Theiler's virus induced demyelination and in MS. *J Neurol Neurosurg Psychiatry* 1994;57(Suppl):65–68.
170. van Engelen BG, Hommes OR, Pinckers A, et al. Improved vision after intravenous immunoglobulin in stable demyelinating optic neuritis. *Ann Neurol* 1992;32:834–835.
171. Noseworthy JH, O'Brien PC, Petterson TM, et al. A randomized trial of intravenous immunoglobulin in inflammatory demyelinating optic neuritis. *Neurology* 2001;56:1514–1522.
172. Scorolli L, Martini E, Scorolli L, et al. Metilprednisolone in bolo endovenoso nel trattamento delle manifestazioni oculari della sclerosi multipla. *Ann Ottalmol Clin Oculist* 1991;117:165–171.
173. Serra A. Some temporal aspects of colour discrimination in multiple sclerosis. *Doc Ophthalmol* 1982;33:445–451.
174. Plant GT, Hess RF. Regional threshold contrast sensitivity within the central visual field in optic neuritis. *Brain* 1987;110:489–515.
175. Keltner JL, Johnson CA, Spurr JO, et al. Visual field profile of optic neuritis: one-year follow-up in the Optic Neuritis Treatment Trial. *Arch Ophthalmol* 1994;112:946–953.
176. Sandberg HO. Acute retrobulbar neuritis: a retrospective study. *Acta Ophthalmol* 1972;50:3–8.
177. Slamovits TL, Rosen CE, Cheng KP, et al. Visual recovery in patients with optic neuritis and visual loss to no light perception. *Am J Ophthalmol* 1991;111:209–214.
178. Mathot E, Segal A, Bour T, et al. A propos d'un cas de névrite optique retrobulbaire siderante bilatérale sur sclérose en plaques. *Bull Soc Ophtalmol Fr* 1988;88:1449–1450.
179. Saroux H, Nordmann JPh, Denis Ph. Les formes atypiques des névrites optiques de la sclérose en plaques. *J Fr Ophtalmol* 1991;14:235–244.
180. Heron JR, Regan D, Milner BA. Delay in visual perception in unilateral optic atrophy after retrobulbar neuritis. *Brain* 1974;97:69–78.
181. Burde RM, Gallin PF. Visual parameters associated with recovered retrobulbar optic neuritis. *Am J Ophthalmol* 1975;79:1034–1037.
182. Galvin RJ, Regan D, Heron JR. Impaired temporal resolution of vision after acute retrobulbar neuritis. *Brain* 1976;99:255–268.
183. Ellenberger C Jr, Ziegler T. The Swiss cheese visual field or time-varying abnormalities of vision after "recovery" from optic neuritis. In: Smith JL, ed. *Neuro-Ophthalmology Focus* 1980. New York, Masson, 1979:175–179.

184. Hess RF, Plant GT. The effect of temporal frequency variation on threshold contrast sensitivity deficits in optic neuritis. *J Neurol Neurosurg Psychiatry* 1983; 46:322–330.
185. Medjbeur S, Tulunay-Keesey U. Spatiotemporal responses of the visual system in demyelinating diseases. *Brain* 1985;108:123–138.
186. Plant GT, Hess RF. Temporal frequency discrimination in optic neuritis and multiple sclerosis. *Brain* 1985;108:647–776.
187. Frederiksen J, Larsson H, Olesen J, et al. Evaluation of the visual system in multiple sclerosis. II. Colour vision. *Acta Neurol Scand* 1986;74:203–209.
188. Engell T, Trojaborg W, Raun NE. Subclinical optic neuropathy in multiple sclerosis: a neuro-ophthalmological investigation by means of visually evoked response, Farnsworth-Munsell 100 hue test and Ishihara test and their diagnostic value. *Acta Ophthalmol* 1987;65:735–740.
189. Nordmann J-P, Saraux H, Rouillet E. Contrast sensitivity in multiple sclerosis: a study of 35 patients with and without optic neuritis. *Ophthalmologica* 1987; 195:199–204.
190. MacFadyen DJ, Drance SM, Chisholm IA, et al. The Farnsworth-Munsell 100-hue color vision score and visual evoked potentials in multiple sclerosis. *Neuro-ophthalmology* 1988;8:289–298.
191. MacFadyen DJ, Drance SM, Douglas GR, et al. The retinal nerve fiber layer, neuroretinal rim area and visual evoked potentials in MS. *Neurology* 1988;38: 1353–1358.
192. Honan WP, Heron JR, Foster DH, et al. Visual loss in multiple sclerosis and its relation to previous optic neuritis, disease duration and clinical classification. *Brain* 1990;113:975–987.
193. Regan D, Kothe AC, Sharpe JA. Recognition of motion-defined shapes in patients with multiple sclerosis and optic neuritis. *Brain* 1991;114:1129–1155.
194. Ciancaglini M, Thomas A, D'Aurelio AP, et al. Difetti perimetrici affetti da sclerosi multipla con o senza storia di neurite ottica retrobulbare. *Ann Ottalmol Clin Oculist* 1993;119:637–640.
195. Kirkham TH, Coupland SG. Multiple regression analysis of diagnostic predictors in optic nerve disease. *Can J Neurol Sci* 1981;8:67–72.
196. Wybar KC. The ocular manifestations of disseminated sclerosis. *Proc Roy Soc Med* 1952;45:315–319.
197. Lynn BH. Retrobulbar neuritis: a survey of the present condition of cases occurring over the last fifty-six years. *Trans Ophthalmol Soc UK* 1959;79:701–716.
198. Van Dalen JTW, Greve EL. Visual field defects in multiple sclerosis. *Neuroophthalmology* 1981;2:93–104.
199. Zimmern RL, Campbell FW, Wilkinson IM. Subtle disturbances of vision after optic neuritis elicited by studying contrast sensitivity. *J Neurol Neurosurg Psychiatry* 1979;42:407–412.
200. Sjöstrand J, Abrahamsson M. Suprathreshold vision in acute optic neuritis. *J Neurol Neurosurg Psychiatry* 1982;45:227–234.
201. Drucker MD, Savino PJ, Sergott RC, et al. Low-contrast letter charts to detect subtle neuropathies. *Am J Ophthalmol* 1988;105:141–145.
202. Regan D, Silver R, Murray TJ. Visual acuity and contrast sensitivity in multiple sclerosis: hidden visual loss. *Brain* 1977;100:563–579.
203. Kupersmith MJ, Seiple WH, Nelson JJ, et al. Contrast sensitivity loss in multiple sclerosis. *Invest Ophthalmol Vis Sci* 1984;25:632–639.
204. Friedman JR, Kosmorsky GS, Burde RM. Stereoacuity in patients with optic nerve disease. *Arch Ophthalmol* 1985;103:37–38.
205. Sadun AA, Lessell S. Brightness-sense and optic nerve disease. *Arch Ophthalmol* 1985;103:39–43.
206. Bynke H, Rosen I, Sandberg-Wollheim M. Correlation of visual evoked potentials, ophthalmological and neurological findings after unilateral optic neuritis. *Acta Ophthalmol* 1980;58:673–687.
207. Hoyt WF, Schlicke B, Eckelhoff RJ. Funduscopic appearance of a nerve-fiber bundle defect. *Br J Ophthalmol* 1972;56:577–583.
208. Shahrokhii F, Chiappa KH, Young RR. Pattern shift visual evoked responses: two hundred patients with optic neuritis and/or multiple sclerosis. *Arch Neurol* 1978;35:64–71.
209. Wutz W, Bartl G, Hiti H, et al. Verlaufsbeobachtungender neuritis retrobulbaris: Vergleichende psychophysische und elektroophthalmologische befunde. *Klin Monatsbl Augenheilkd* 1980;177:689–695.
210. Halliday AM, McDonald WI, Mushin J. Delayed pattern evoked responses in optic neuritis in relation to visual acuity. *Trans Ophthalmol Soc UK* 1973;93: 315–324.
211. Asselman P, Chadwick DW, Marsden CD. Visual evoked responses in the diagnosis and management of patients suspected of multiple sclerosis. *Brain* 1975; 98:261–282.
212. Halliday AM, McDonald WI, Mushin J. Delayed visual evoked response in optic neuritis. *Lancet* 1972;1:982–985.
213. Cleary PA, Beck RW, Bourque LB, et al. Visual symptoms after optic neuritis: results from the Optic Neuritis Treatment Trial. *J Neuroophthalmol* 1997;17: 18–23.
214. Franklin CR, Brickner RM. Vasospasm associated with multiple sclerosis. *Arch Neurol Psychiatr* 1947;58:125–162.
215. McAlpine D, Compston N. Some aspects of the natural history of disseminated sclerosis. *Q J Med* 1952;21:135–167.
216. Goldstein JE, Cogan DG. Exercise and the optic neuropathy of multiple sclerosis. *Arch Ophthalmol* 1964;72:168–170.
217. Smith JL, Hoyt WF, Susac JO. Ocular fundus in acute Leber optic neuropathy. *Arch Ophthalmol* 1973;90:349–354.
218. Nelson D, Jeffreys WH, McDowell F. Effect of induced hyperthermia on some neurological diseases. *Arch Neurol Psychiatr* 1958;79:31–39.
219. Scholl GB, Song H-S, Wray SH. Uhthoff's symptom in optic neuritis: relationship to magnetic resonance imaging and development of multiple sclerosis. *Ann Neurol* 1991;30:180–184.
220. Guthrie TC. Visual and motor changes in patients with multiple sclerosis. *Arch Neurol Psychiatr Nervenkr* 1951;21:55–116.
221. Bornstein MD, Crain SM. Functional studies of cultured brain tissue as related to demyelinating disorders. *Science* 1965;148:1242–1244.
222. Cerf JA, Carels G. Multiple sclerosis: serum factor producing reversible alteration in bioelectric responses. *Science* 1966;152:1066–1068.
223. Crain SM, Bornstein MB. Depression of complex bioelectric discharges in cerebral tissue cultures by thermolabile complement dependent serum factors. *Exp Neurol* 1975;49:330–338.
224. Sell FJ, Leiman AL, Kelly JM. Neuroelectric blocking factors in multiple sclerosis and normal human sera. *Arch Neurol* 1976;33:418–422.
225. Zweifach PH. Studies of hyperthermia in optic neuropathy. *Arch Ophthalmol* 1978;96:1831–1834.
226. Tasaki I. *Nervous Transmission*. Springfield, IL, Charles C Thomas, 1953.
227. Davis FA. Pathophysiology of multiple sclerosis and related clinical implications. *Mod Treat* 1970;7:890.
228. Rasminsky M. The effects of temperature on conduction in demyelinated single nerve fibers. *Arch Neurol* 1973;28:287–292.
229. Bode DD. The Uhthoff phenomenon. *Am J Ophthalmol* 1978;85:721–722.
230. Persson HE, Sachs E. Visual evoked potentials elicited by pattern reversal during provoked visual impairment in multiple sclerosis. *Brain* 1981;104:369–382.
231. Selhorst JB, Saul RF, Waybright EA. Optic nerve conduction: opposing effects of exercise and hyperventilation. *Trans Am Neurol Assoc* 1981;106:101–105.
232. Kurtzke JF. Optic neuritis or multiple sclerosis. *Arch Neurol* 1985;42:704–710.
233. Kennedy C, Carter S. Relation of optic neuritis to multiple sclerosis in children. *Pediatrics* 1961;28:377–387.
234. Riikonen R, Donner M, Erkkilä H. Optic neuritis in children and its relationship to multiple sclerosis: a clinical study of 21 children. *Dev Med Child Neurol* 1988;30:349–359.
235. O'Duffy AE, Kiers L, Gomez MR, et al. Acute optic neuritis in childhood: a long-term follow-up. *Ann Neurol* 1993;34:273.
236. Rizzo JF, Lessell S. Risk of developing multiple sclerosis after uncomplicated optic neuritis: a long-term prospective study. *Neurology* 1988;38:185–190.
237. Landy PJ. A prospective study of the risk of developing multiple sclerosis in optic neuritis in a tropical and sub-tropical area. *J Neurol Neurosurg Psychiatry* 1983;46:659–661.
238. Isayama Y, Takahashi T, Shimoyoma T, et al. Acute optic neuritis and multiple sclerosis. *Neurology* 1982;32:73–76.
239. Alvarez G, Cárdenas M. Multiple sclerosis following optic neuritis in Chile. *J Neurol Neurosurg Psychiatry* 1989;52:15–117.
240. Ebers GC. Optic neuritis and multiple sclerosis. *Arch Neurol* 1985;42:702–704.
241. Beck RW. What to tell the patient with optic neuritis about multiple sclerosis. II. When to withhold. *Surv Ophthalmol* 1991;36:48–49.
242. Frenkel M, Lim JJ, Hillman DS. What to tell the patient with optic neuritis about multiple sclerosis. III. The patient's right to know. *Surv Ophthalmol* 1991;36: 49–50.
243. Slamovits TL, Macklin R. What to tell the patient with optic neuritis about multiple sclerosis. *Surv Ophthalmol* 1991;36:47–48.
244. McAlpine D. The benign form of multiple sclerosis. *Brain* 1961;86:186–203.
245. Fog T, Linneman F. The course of multiple sclerosis. *Acta Neurol Scand* 1970; 47(Suppl):46.
246. Nikoskelainen E, Riekkinen P. Retrospective study of 117 patients with optic neuritis. *Acta Ophthalmol Suppl* 1974;123:202–204.
247. Wikström J, Poser S, Ritter G. Optic neuritis as an initial symptom in multiple sclerosis. *Acta Neurol Scand* 1980;61:178–185.
248. Leibowitz U, Alter M, Halpern L. Clinical studies of multiple sclerosis in Israel. IV. Optic neuritis and multiple sclerosis. *Arch Neurol* 1966;14:459–466.
249. Leibowitz U, Kahana E, Alter M. Multiple sclerosis in immigrant and native populations of Israel. *Lancet* 1969;2:1323–1325.
250. Leibowitz U, Alter M. Clinical factors associated with increased disability in multiple sclerosis. *Acta Neurol Scand* 1970;46:53–70.
251. Sanders EA, Reulen JPH, Hogenhuis LA. Central nervous system involvement in optic neuritis. *J Neurol Neurosurg Psychiatry* 1984;47:241–249.
252. O'Riordan JI, Thompson AJ, Kingsley, et al. The prognostic value of brain MRI in clinically isolated syndromes of the CNS: a 10-year-year follow-up. *Brain* 1998;121:495–503.
253. Brex PA, Ciccarelli O, O'Riordan JI, et al. A longitudinal study of abnormalities on MRI and disability from multiple sclerosis. *N Engl J Med* 2002;346:158–164.
254. Schlossman A, Phillips C. Optic neuritis in relation to demyelinating diseases. *Am J Ophthalmol* 1954;37:487–494.
255. Lumsden GE. The neuropathology of multiple sclerosis. In: Vinken PJ, Bruyn GW, eds. *Handbook of Clinical Neurology*. Amsterdam, North Holland, 1970: 217–309.
256. McDonald WI. Pathophysiology in multiple sclerosis. *Brain* 1974;97:179–196.

257. Prineas J. Pathology of the early lesion in multiple sclerosis. *Hum Pathol* 1975; 6:531–554.
258. Traugott U, Reinherz EL, Raine CS. Multiple sclerosis: distribution of T cell subjects within active chronic lesions. *Science* 1985;219:308–310.
259. Gartner S. Optic neuropathy in multiple sclerosis: optic neuritis. *Arch Ophthalmol* 1953;50:718–726.
260. de Preux J, Mair WGP. Ultra-structure of the optic nerve in Schilder's disease, Devic's disease and disseminated sclerosis. *Acta Neuropathol* 1974;30:225–242.
261. Rao NA, Tso MOM, Zimmerman EL. Experimental allergic optic neuritis in guinea pigs: preliminary report. *Invest Ophthalmol Vis Sci* 1977;16:338–342.
262. Hayreh SS, Massanari RM, Yamada T, et al. Experimental allergic encephalomyelitis. I. Optic nerve and central nervous system manifestations. *Invest Ophthalmol Vis Sci* 1981;21:256–269.
263. Okamoto N. Macrophages in the subarachnoid space in experimental allergic optic neuritis. *Jpn J Ophthalmol* 1981;25:38–46.
264. Rao NA. Demyelinating optic neuritis. *Comp Pathol Bull* 1979;2:3–4.
265. Sergott RC, Brown MJ, Polenta RM, et al. Optic nerve demyelination induced by human serum: patients with multiple sclerosis or optic neuritis and normal subjects. *Neurology* 1985;35:1438–1442.
266. Davis FA, Schauff C. Pathophysiology of multiple sclerosis. In: *Multiple Sclerosis Research: Proceedings of a Joint Conference Held by the Medical Research Council and the Multiple Sclerosis Society of Great Britain and Northern Ireland*. London, Her Majesty's Stationary Office, 1975.
267. Nikoskelainen E, Frey H, Salmi AA. Prognosis of optic neuritis with special reference to cerebrospinal fluid immunoglobulins and measles virus antibodies. *Ann Neurol* 1981;9:545–550.
268. Ebers GC, Cousin HK, Feasby TE, et al. Optic neuritis in familial MS. *Neurology* 1981;31:1138–1142.
269. Kurland LT, Beebe GW, Kurtzke JF, et al. Studies on the natural history of multiple sclerosis: 2. The progression of optic neuritis to multiple sclerosis. *Acta Neurol Scand* 1966;42(Suppl 19):157–176.
270. Mapelli G, de Palma P, Sebastiani A, et al. Risk of multiple sclerosis in optic neuritis: a prospective study. *Acta Neurol* 1986;8:619–625.
271. Alter M, Good J, Okihiro M. Optic neuritis in Orientals and Caucasians. *Neurology* 1973;23:631–639.
272. Alter M, Halpern L, Kurland LT, et al. The prevalence of multiple sclerosis in Israel among immigrants and native inhabitants. *Arch Neurol* 1962;7:253–263.
273. Dean G, Kurtzke JF. On the risk of multiple sclerosis according to age of immigration to South Africa. *Br Med J* 1971;3:725–729.
274. Kurtzke JF, Beebe GW, Norman JE Jr. Epidemiology of multiple sclerosis in US veterans. I. Race, sex and geographic distribution. *Neurology* 1979;29:1228–1235.
275. Morrissey SP, Borrut FX, Miller DH, et al. Bilateral simultaneous optic neuropathy in adults: clinical, imaging, serological, and genetic studies. *J Neurol Neurosurg Psychiatry* 1995;58:70–74.
276. Jacobs L, Kaba S, Miller C, et al. Correlation of clinical, magnetic resonance imaging, and cerebrospinal fluid findings in optic neuritis. *Ann Neurol* 1997; 41:393–398.
277. Cole SR, Beck RW, Moke PS, et al. The predictive value of CSF oligoclonal banding for MS 5 years after optic neuritis. *Neurology* 1998;51:885–887.
278. Müller R. Studies on disseminated sclerosis with special reference to symptomatology, course and prognosis. *Acta Med Scand* 1949;133(Suppl 222):1–214.
279. Scott GI. Ophthalmic aspects of demyelinating diseases. *Proc R Soc Med* 1961; 54:38–42.
280. Ashworth B. Chronic retrolubal and chiasmatic neuritis. *Br J Ophthalmol* 1967; 51:598–702.
281. Kahana E, Leibowitz U, Fishback N, et al. Slowly progressive and acute visual impairment in multiple sclerosis. *Neurology* 1973;23:729–733.
282. Patterson VH, Heron JR. Visual field abnormalities in multiple sclerosis. *J Neurol Neurosurg Psychiatry* 1980;43:205–208.
283. Patterson VH, Foster DH, Heron JR, et al. Multiple sclerosis: luminance threshold and measurements of temporal characteristics of vision. *Arch Neurol* 1981; 38:687–689.
284. Ormerod IEC, McDonald WI. Multiple sclerosis presenting with progressive visual failure. *J Neurol Neurosurg Psychiatry* 1984;47:943–946.
285. Ashworth B. Chronic demyelinating optic neuritis: a reappraisal. *Neuroophthalmology* 1987;7:75–79.
286. Frisén L, Hoyt WF. Insidious atrophy of retinal nerve fibers in multiple sclerosis: funduscopy identification of patients with and without visual complaints. *Arch Ophthalmol* 1974;92:91–97.
287. Regan D, Bartol S, Murray TJ, et al. Spatial frequency discrimination in normal vision and in patients with multiple sclerosis. *Brain* 1982;105:735–754.
288. Raymond J, Regan D, Murray TJ. Abnormal adaptation of visual contrast sensitivity in multiple sclerosis patients. *Can J Neurol Sci* 1981;8:227–234.
289. Della Sala S, Comi G, Martinelli V, et al. The rapid assessment of visual dysfunction in multiple sclerosis. *J Neurol Neurosurg Psychiatry* 1987;50:840–846.
290. Soderstrom M. Multiple sclerosis: rationale for early treatment. *Neuro Sci* 2003; 24:S298–S300.
291. Ashworth B, Aspinall PA, Mitchell JD. Visual function in multiple sclerosis. *Doc Ophthalmol* 1990;73:209–224.
292. van Diemen HAM, Lanting P, Koetsier JC, et al. Evaluation of the visual system in multiple sclerosis: a comparative study of diagnostic tests. *Clin Neurol Neurosurg* 1992;94:191–195.
293. Ulrich J, Groebke-Lorenz W. The optic nerve in multiple sclerosis. A morphological study with retrospective clinico-pathological correlations. *Neuroophthalmology* 1983;3:149–159.
294. Miller NR, Walsh and Hoyt's *Clinical Neuro-Ophthalmology*, 4th ed. Baltimore, Williams & Wilkins, 1995:4314.
295. Menabue R, Nichelli P, Bellei S. Exposure times for color discrimination in the parafoveal field: a new procedure to detect subtle visual dysfunction in multiple sclerosis patients. *J Neurol Neurosurg Psychiatry* 1986;49:400–404.
296. Pinckers A, Cruysberg JRM. Colour vision, visually evoked potentials, and lightness discrimination in patients with multiple sclerosis. *Neuroophthalmology* 1992;12:251–256.
297. Meienberg O, Flammer J, Ludin H-P. Subclinical visual field defects in multiple sclerosis: demonstration and quantification with automated perimetry, and comparison with visually evoked potentials. *J Neurol* 1982;227:125–133.
298. Marra G, Ciasca S, Ratiglia R, et al. Confronto tra le alterazioni del campo visivo in soggetti affetti da sclerosi multipla con e senza pregresse neuriti ottiche. *Boll Oculist* 1989;68:249–252.
299. Cox TA. Relative afferent pupillary defects in multiple sclerosis. *Can J Ophthalmol* 1989;24:207–210.
300. Feinsod M, Hoyt WF. Subclinical optic neuropathy in multiple sclerosis: how early VER components reflect axon loss and conduction defects in optic pathways. *J Neurol Neurosurg Psychiatry* 1975;38:1109–1114.
301. Elbol P, Work K. Retinal nerve fiber layer in multiple sclerosis. *Acta Ophthalmol* 1990;68:481–486.
302. Honan WP, Baranyovits PR, Heron JR. Retinal nerve fiber layer atrophy in multiple sclerosis. *Neuroophthalmology* 1992;12:11–15.
303. Ellenberger C Jr, Ziegler T. Visual evoked potentials and quantitative perimetry in multiple sclerosis. *Ann Neurol* 1977;1:561–564.
304. Matthews WB, Acheson ED, Batchelor JR, et al, eds. *McAlpine's Multiple Sclerosis*. Edinburgh, Churchill Livingstone, 1985.
305. Wright CE, Drasdo N, Harding GFA. Pathology of the optic nerve and visual association areas: information given by the flash and pattern visual evoked potential, and the temporal and spatial contrast sensitivity function. *Brain* 1987;110: 107–120.
306. Travis D, Thompson P. Spatiotemporal contrast sensitivity and colour vision in multiple sclerosis. *Brain* 1989;112:283–303.
307. Ashworth B, Aspinall PA. A longitudinal study of visual function in multiple sclerosis: with a note on the Cambridge grating test. *Neuroophthalmology* 1993; 13:135–142.
308. Ogden NA, Raymond JE, Seland TP. Visual accommodation and sustained visual resolution in multiple sclerosis. *Invest Ophthalmol Vis Sci* 1992;33: 2744–2753.
309. Galvin RJ, Heron JR, Regan D. Subclinical optic neuropathy in multiple sclerosis. *Arch Neurol* 1977;34:666–670.
310. Daley ML, Swank RL, Ellison CM. Flicker fusion thresholds in multiple sclerosis: a functional measure of neurological damage. *Arch Neurol* 1979;36: 292–295.
311. Foster RE, Lowder CY, Meisler DM, et al. Mumps neuroretinitis in an adolescent. *Am J Ophthalmol* 1990;110:91–93.
312. Dain SJ, Rammahan KW, Benes SC, et al. Chromatic, spatial, and temporal losses of sensitivity in multiple sclerosis. *Invest Ophthalmol Vis Sci* 1990;31: 548–558.
313. Porciatti V, Sartucci F. Retinal and cortical evoked responses to chromatic contrast stimuli: specific losses in the eyes of patients with multiple sclerosis and unilateral optic neuritis. *Brain* 1996;119:723–740.
314. Pulfrich C. Die stereoskopie im Dienste der isochromen und heterochromen Photometrie. *Naturwissenschaften* 1922;10:553–761.
315. Rushton D. Use of the Pulfrich pendulum for detecting abnormal delay in the visual pathway in multiple sclerosis. *Brain* 1975;98:283–296.
316. Feldman L, Todman L, Bender B. "Flight of colours" in lesions of the visual system. *J Neurol Neurosurg Psychiatry* 1974;37:1265–1272.
317. Swart S, Millac P. A comparison of flight of colours with visually evoked responses in patients with multiple sclerosis. *J Neurol Neurosurg Psychiatry* 1980;43:550–551.
318. Rolak LA. The flight of colors test in multiple sclerosis. *Arch Neurol* 1985;42: 759–760.
319. Larsson H, Frederiksen J, Stigsby B, et al. Evaluation of visual pathways in multiple sclerosis. I. After-images compared to visual evoked potentials. *Acta Neurol Scand* 1986;74:195–202.
320. Allbutt TC. On the ophthalmoscopic signs of spinal disease. *Lancet* 1870;1: 76–78.
321. Devic E. Myélite subaigue compliquée de névrite optique. *Bull Med Paris* 1894; 8:1033–1034.
322. Gault F. De la neuromyérite optique aigue. Thesis, University of Lyon, 1894, Serre I, No. 981, Lyon.
323. Cree BAC, Goodin DS, Hauser SL. Neuromyelitis optica. *Semin Neurol* 2002; 22:105–122.
324. Shibusaki H, Kuroda Y, Kuroiwa Y. Clinical studies of multiple sclerosis in

- Japan: classical multiple sclerosis and Devic's disease. *J Neurol Sci* 1974;23: 215–222.
325. Pálffy G. Multiple sclerosis in Hungary, including the Gypsy. In: Kuroiwa Y, Kurland LT, eds. *Multiple Sclerosis, East and West*. Fukuoka, Kyushu University Press, 1982:149–158.
 326. Kuroiwa Y. Multiple sclerosis and allied demyelinating encephalomyelitis in Japan. In: Bammer HG, ed. *Zukunft der Neurologie*. Stuttgart, Thieme, 1967: 70–84.
 327. Kuroiwa Y, Shibasaki H. Clinical studies of multiple sclerosis in Japan. I. A current appraisal of 83 cases. *Neurology* 1973;23:609–617.
 328. Kuroiwa Y, Igata A, Itahara K, et al. Nationwide survey of multiple sclerosis in Japan: clinical analysis of 1,084 cases. *Neurology* 1975;25:845–851.
 329. Shibasaki H, Kuroda Y, Kuroiwa Y. Clinical studies of multiple sclerosis in Japan: classical multiple sclerosis and Devic's disease. *J Neurol Sci* 1974;23: 215–222.
 330. Stansbury FC. Neuromyelitis optica (Devic's disease): presentation of five cases, with pathologic study, and review of literature. *Arch Ophthalmol* 1949;42: 292–335, 465–501.
 331. Scott GI. Neuromyelitis optica. *Am J Ophthalmol* 1952;35:755–764.
 332. Hershewe GL, Corbett JJ, Thompson HS. The NANOS Devic's Study Group. Presented at the North American Neuro-Ophthalmology Society Meeting, Steamboat Springs, CO, Feb. 4–8, 1990.
 333. Ramelli GP, Deonna T, Roulet E, et al. Transverse myelitis and optic neuromyelitis in children: apropos of 3 case reports. *Schweiz Rundsch Med Prax* 1992;81: 661–663.
 334. Igarashi Y, Oyachi H, Nakamura Y, et al. Neuromyelitis optica. *Ophthalmology* 1994;208:226–229.
 335. Jain S, Hiran S, Sarma PS. Devic's disease. *J Assoc Phys India* 1994;42:166.
 336. Jeffery AR, Buncic JR. Pediatric Devic's neuromyelitis optica. *J Pediatr Ophthalmol Strabismus* 1996;33:223–229.
 337. Filley CM, Sternberg PE, Norenberg MD. Neuromyelitis optica in the elderly. *Arch Neurol* 1984;41:670–672.
 338. Barbieri F, Buscaino GA. Neuromyelitis optica in the elderly. *Acta Neurol* 1989; 11:247–251.
 339. McAlpine D. Familial neuromyelitis optica: its occurrence in identical twins. *Brain* 1938;61:430–448.
 340. April RS, Vansonenberg E. A case of neuromyelitis optica (Devic's syndrome) in systemic lupus erythematosus: clinicopathologic report and review of the literature. *Neurology* 1976;26:1066–1070.
 341. Kinney EL, Berdoff RL, Rao NS, et al. Devic's syndrome and systemic lupus erythematosus: a case report with necropsy. *Arch Neurol* 1979;36:643–644.
 342. Tommasi M, Lecuire J, Masquin A, et al. Étude anatomoclinique d'une neuromyélite optique de Devic, d'évolution artificiellement prolongée. *Rev Neurol* 1966; 114:378–381.
 343. Barbizet J, Degos JD, Meyrignac C. Neuromyélite optique aiguë associée à une tuberculose pulmonaire aiguë. *Rev Neurol* 1980;136:303–309.
 344. Silber MH, Willcox PA, Bowen RM, et al. Neuromyelitis optica (Devic's syndrome) and pulmonary tuberculosis. *Neurology* 1990;40:934–938.
 345. Al-Deeb SM, Yaqub BA, Khoja WO. Devic's neuromyelitis optica and varicella. *J Neurol* 1993;240:450–451.
 346. Ahasan HA, Jafiqueuddin AK, Chowdhury MA, et al. Neuromyelitis optica (Devic's disease) following chicken pox. *Trop Doc* 1994;24:75–76.
 347. Hainfellner JA, Schmidbauer M, Schmutzhard E, et al. Devic's neuromyelitis optica and Schilder's myelinoclastic diffuse sclerosis. *J Neurol Neurosurg Psychiatry* 1992;55:1194–1196.
 348. Raine CS. Demyelinating diseases. In: Davis RL, Robertson DM, eds. *Textbook of Neuropathology*. 2nd ed. Baltimore, Williams & Wilkins, 1991:535–620.
 349. Mandler RN, Davis LE, Jeffery DR, et al. Devic's neuromyelitis optica: a clinicopathologic study of 8 patients. *Ann Neurol* 1993;34:162–168.
 350. Allen IV, Kirk J. Demyelinating diseases. In: Adams JH, Duchon LW, eds. *Greenfield's Neuropathology*, 5th ed. New York, Oxford University Press, 1992: 447–520.
 351. Walsh FB. Neuromyelitis optica: an anatomical-pathological study of one case; clinical studies of three additional cases. *Bull Johns Hopkins Hosp* 1935;56: 183–210.
 352. Walsh FB, Hoyt WF. *Clinical Neuro-Ophthalmology*, 3rd ed. Baltimore, Williams & Wilkins, 1969:996–997.
 353. Aimoto Y, Ito K, Morwaka F, et al. Demyelinating peripheral neuropathy in Devic disease. *Jpn J Psychiatry Neurol* 1991;45:861–864.
 354. Cloys DE, Netsky MG. Neuromyelitis optica. In: Vinken PJ, Bruyn GW, eds. *Handbook of Clinical Neurology*. New York, Elsevier North Holland, 1970: 426–436.
 355. Oppenheimer DR. Demyelinating diseases. In: Blackwood W, Corsellis JA, eds. *Greenfield's Neuropathology*, 3rd ed. London, Edward Arnold, 1976:470–484.
 356. Poser CM. Neuromyelitis optica. In: Baker AB, Baker LH, eds. *Clinical Neurology*. Philadelphia, JB Lippincott, 1981:70.
 357. Hassin GB. Neuroptic myelitis versus multiple sclerosis: a pathologic study. *Arch Neurol* 1937;34:1083–1099.
 358. Kohut H, Richter RB. Neuro-optic myelitis: a clinicopathological study of two related cases. *J Nerv Ment Dis* 1945;101:99–114.
 359. Lassmann H, Bruck W, Lucchinetti C. Heterogeneity of multiple sclerosis pathogenesis; implications for diagnosis and therapy. *Trends Mol Med* 2001;7: 115–121.
 360. Lucchinetti CF, Mandler RN, McGavern D, et al. A role for humoral mechanisms in the pathogenesis of Devic's neuromyelitis optica. *Brain* 2002;125:1450–1461.
 361. Linington C, Bradl M, Lassmann H, et al. Augmentation of demyelination in rat acute allergic encephalomyelitis by circulating mouse monoclonal antibodies directed against a myelin/oligodendrocyte glycoprotein. *Am J Pathol* 1988;130: 443–454.
 362. Gold R, Linington C. Devic's disease: bridging the gap between laboratory and clinic. *Brain* 2002;125:1425–1427.
 363. Steffler A, Brehm U, Storch M, et al. Myelin oligodendrocyte glycoprotein induces experimental autoimmune encephalomyelitis in the "resistant" Brown Norway rat: disease susceptibility is determined by MHC and MHC-lined effects on the B cell response. *J Immunol* 1999;163:40–49.
 364. Whitham RH, Brey RL. Neuromyelitis optica: two new cases and review of the literature. *J Clin Neuroophthalmol* 1985;5:263–269.
 365. Zangemeister WH, Mueller-Jensen A. Neuromyelitis optica: clinical and neurophysiological features. *Neuroophthalmology* 1984;4:81–88.
 366. Ko FJ, Chiang CH, Jong YJ, et al. Neuromyelitis optica (Devic's disease): report of one case. *Acta Paediatr Sinica* 1989;30:428–431.
 367. Khan MA, Mahar PS, Raghuraman VU. Neuromyelitis optica (Devic's disease). *Br J Clin Pract* 1990;44:667–668.
 368. Kuroiwa Y, Igata A, Itahara K, et al. Nationwide survey of multiple sclerosis in Japan: clinical analysis of 1,084 cases. *Neurology* 1975;25:845–851.
 369. Chusid MJ, Williamson SJ, Murphy JV, et al. Neuromyelitis optica (Devic disease) following varicella infection. *J Pediatr* 1979;95:737–738.
 370. Williamson PM. Neuromyelitis optica following infectious mononucleosis. *Proc Aust Assoc Neurol* 1975;12:153–155.
 371. Kline LB, Margulies SL, Oh SJ. Optic neuritis and myelitis following rubella vaccination. *Arch Neurol* 1982;39:443–444.
 372. Breukelman AJ, Polman CH, de Slegte RG, et al. Neuromyelitis optica (Devic's syndrome); not always multiple sclerosis. *Clin Neurol Neurosurg* 1988;90: 357–360.
 373. Walsh FB, Hoyt WF. *Clinical Neuro-Ophthalmology*, 3rd ed. Baltimore, Williams & Wilkins, 1969:997.
 374. Goulden C. Optic neuritis and myelitis. *Trans Ophthalmol Soc UK* 1914;34: 229–252.
 375. Beck GM. A case of diffuse myelitis associated with optic neuritis. *Brain* 1927; 50:687–702.
 376. Markham JW, Otenasek FJ. Neuromyelitis optica simulating spinal cord tumor: report of a case with review of nine additional cases. *Arch Neurol Psychiatry* 1954;72:758–763.
 377. Walsh FB, Hoyt WF. *Clinical Neuro-Ophthalmology*, 3rd ed. Baltimore, Williams & Wilkins, 1969:998.
 378. Piccolo G, Franciotta DM, Camana C, et al. Devic's neuromyelitis optica: long-term follow-up and serial CSF findings in two cases. *J Neurol* 1990;237: 262–264.
 379. Keefe RJ. Neuromyelitis optica with increased intracranial pressure. *Arch Ophthalmol* 1957;57:110–111.
 380. Chou C-H, Chou FC-H, Tourtellotte WW, et al. Devic's syndrome: antibody to glial fibrillary acidic protein in cerebrospinal fluid. *Neurology* 1984;34:86–88.
 381. Barkhof F, Scheltens P, Valk J, et al. Serial quantitative MR assessment of optic neuritis in a case of neuromyelitis optica, using gadolinium-"enhanced" STIR imaging. *Neuroradiology* 1991;33:70–71.
 382. Filippi M, Rocca MA, Momiola L, et al. MRI and magnetization transfer imaging changes in the brain and cervical cord of patients with Devic's neuromyelitis optica. *Neurology* 1999;53:1705–1710.
 383. Weinschenker BG, Wingerchuk DM, Lucchinetti CF, et al. A marker autoantibody discriminates neuromyelitis optica from multiple sclerosis. *American Academy of Neurology Poster S65.005*, 2003.
 384. Lennon VA, Lucchinetti CF, Weinschenker BG. Identification of a marker autoantibody of neuromyelitis optica. *American Academy of Neurology Poster*, 2003.
 385. Kuroiwa Y, Hung TP, Landsborough D, et al. Multiple sclerosis in Asia. *Neurology* 1977;7:188–192.
 386. Shibasaki H, McDonald WI, Kuroiwa Y. Racial modification of clinical picture of multiple sclerosis: comparison between British and Japanese patients. *J Neurol Sci* 1981;49:253–271.
 387. Yamasaki K, Horiuchi I, Minohara M, et al. HLA-DPB1*0501-associated opticospinal multiple sclerosis: clinical, neuroimaging and immunogenetic studies. *Brain* 1999;121:1689–1696.
 388. Nakashima I, Fujihara K, Takase S, et al. Decrease in multiple sclerosis with acute transverse myelitis in Japan. *Tohoku J Exp Med* 1999;188:89–94.
 389. Banerjee A, Bishop A, Elliott P. A case of neuromyelitis optica (Devic's disease). *Practitioner* 1989;23:202–203.
 390. Frohman LP, Cook SD, Bieler L. Dysgammaglobulinemia in steroid-dependent optic neuritis: response to gamma globulin treatment. *J Clin Neuroophthalmol* 1991;11:241–245.
 391. Keegan M, Pineda AA, McClelland RL, et al. Plasma exchange for severe attacks of CNS demyelination: predictors of response. *Neurology* 2002;58:143–146.
 392. Duda PW, Schmied MC, Cook SL, et al. Glatiramer acetate (Copaxone®) in-

- duces degenerate, TH2-polarized immune responses in patients with multiple sclerosis. *J Clin Invest* 2000;105:967–976.
393. Fraifick FB, DeJong RN. Neuromyelitis optica. *Am J Ophthalmol* 1937;20:1119–1124.
 394. Johns DR, Heher KL, Miller NR, Smith KH. Leber's hereditary optic neuropathy: clinical manifestations of the 14484 mutation. *Arch Ophthalmol* 1993;111:495–498.
 395. Marburg O. Die sogenannte "akute multiple Sklerose" (Encephalomyelitis periaxialis scleroticans). *Jahrb Psychiatr Neurol* 1906;27:211–312.
 396. Schilder P. Zur Frage der Encephalitis periaxialis diffusa (sogenannte diffuse Sklerose). *Ztschr Neurol Psychiatr* 1913;15:359–376.
 397. Schilder P. Die Encephalitis periaxialis diffusa (nebst Bemerkungen über die Apraxie des Lidschlusses). *Arch Psychiatr Nervenkr* 1924;71:327–336.
 398. Adams RD, Victor M. Principles of Neurology, 4th ed. New York, McGraw-Hill, 1989:908–909.
 399. Barness LA, Chandra S, Kling P, et al. Progressive neurologic deterioration in a nine-year-old white male. *Am J Med Gen* 1990;37:489–503.
 400. Poser CM. Diffuse-disseminated sclerosis in the adult. *J Neuropathol Exp Neurol* 1957;16:61–78.
 401. Martin J-J, Guazzi G-C. Schilder's diffuse sclerosis. *Dev Neurosci* 1991;13:267–273.
 402. Case Records of the Massachusetts General Hospital: Case 6-1962. *N Engl J Med* 1962;266:191–196.
 403. Allen IV. Demyelinating diseases. In: Adams JH, Corsellis JAN, Duchon LW, eds. Greenfield's Neuropathology, 4th ed. New York, John Wiley & Sons, 1984:338–384.
 404. Dresser LP, Tourian AY, Anthony DC. A case of myelinoclastic diffuse sclerosis in an adult. *Neurology* 1991;41:316–318.
 405. Eblen F, Poremba M, Grodd W, et al. Myelinoclastic diffuse sclerosis (Schilder's disease): Cliniconeurologic correlations. *Neurology* 1991;41:589–591.
 406. Schmidt RE. Demyelinating diseases. In: Nelson JS, Parisi JE, Schochet SS Jr, eds. Principles and Practice of Neuropathology. St Louis, CV Mosby, 1993:361–397.
 407. Schilder P. Zur Kenntnis der sogenannten diffusen Sklerose. *Ztschr Ges Neurol Psychiatr* 1912;10:1–606.
 408. Zeman W, Whieldon JA. Clinical considerations in "Schilder's disease." *Am J Dis Child* 1962;104:635–643.
 409. Poser CM, Goutières F, Carpentier MA, Aicardi J. Schilder's myelinoclastic diffuse sclerosis. *Pediatrics* 1986;77:107–112.
 410. Sedwick LA, Klingele TG, Burde RM, et al. Schilder's (1912) disease: total cerebral blindness due to acute demyelination. *Arch Neurol* 1986;43:85–87.
 411. Lana-Peixoto MA, dos Santos EC. Schilder's myelinoclastic diffuse sclerosis. *J Clin Neuroophthalmol* 1989;9:236–240.
 412. Ford FR, Bumstead JH. Encephalitis periaxialis diffusa of Schilder: report of 2 cases with anatomical findings. *Bull Johns Hopkins Hosp* 1929;44:443–458.
 413. Ford FR. Diseases of the Nervous System in Infancy, Childhood and Adolescence, 5th ed. Springfield, IL, Charles C Thomas, 1966:197–205.
 414. Nover A. Über Netzhautveränderungen bei Schilderscher Enzephalitis. *Klin Monatsbl Augenheilkd* 1955;127:294–302.
 415. Sagar HJ, Warlow CP, Shelton PWE, et al. Multiple sclerosis with clinical and radiological features of cerebral tumors. *J Neurol Neurosurg Psychiatry* 1982;45:802–808.
 416. Harpey JP, Fenalet F, Foncin JF, et al. Démyélinisation aiguë pseudotumorale à poussées régressives. *Arch Fr Pediatr* 1983;40:407–409.
 417. Mehler MF, Rabinowich L. Inflammatory myelinoclastic diffuse sclerosis. *Ann Neurol* 1988;23:413–415.
 418. Barth PG, Derix MMA, de Krom MCTFM, et al. Schilder's diffuse sclerosis: case study with three years' follow-up and neuro-imaging. *Neuropediatrics* 1989;20:230–233.
 419. Mehler MF, Rabinowich L. Inflammatory myelinoclastic diffuse sclerosis (Schilder's disease): Neuroradiologic findings. *AJNR Am J Neuroradiol* 1989;10:176–180.
 420. Szabo P, Hegedus K. Myelinoclastic diffuse sclerosis: a case report. *Acta Morphol Hung* 1990;38:109–117.
 421. DiMario FJ Jr, Berman PH. Multiple sclerosis presenting at 4 years of age: clinical and MRI correlations. *Clin Pediatr* 1988;27:32–37.
 422. Konkol RJ, Bousounis D, Kuban KC. Schilder's disease: additional aspects and a therapeutic option. *Neuropediatrics* 1987;18:149–152.
 423. Baló J. A leukoencephalitis periaxialis concentricaról. *Magy Orvosi Arch* 1927;28:108–124.
 424. Baló J. Encephalitis periaxialis concentrica. *Arch Neurol Psychiatry* 1928;19:242–264.
 425. Bleiker H. Genuine Epilepsie und Konzentrische Sklerose. *Schweiz Arch Neurol Psychiatr* 1967;100:387–398.
 426. Duma D, Papilian VV, Serban M. Recherches histochemiques dan certaines encéphalomyérites démyélinisantes primitives. *Rev Roum Neurol* 1965;2:139–154.
 427. Courville CB. Concentric sclerosis. In: Vinken PJ, Bruyn GW, eds. Handbook of Clinical Neurology. Amsterdam, North-Holland, 1970:9:437–451.
 428. Harper CG. Diagnostic dilemma: acute central nervous system disorder mimicking stroke. *Med J Aust* 1981;1:136–138.
 429. Moore GRW, Neumann PE, Suzuki K, et al. Baló's concentric sclerosis: new observations on lesion development. *Ann Neurol* 1985;17:604–611.
 430. Currie S, Roberts AH, Ulrich H. The nosological position of concentric lacunar leucoencephalopathy. *J Neurol Neurosurg Psychiatry* 1970;33:131–137.
 431. Yao D-L, Webster HD, Hudson LD, et al. Concentric sclerosis (Baló): morphometric and in situ hybridization study of lesions in six patients. *Ann Neurol* 1994;35:18–30.
 432. Garbern J, Spence AM, Alvord EC Jr. Baló's concentric demyelination diagnosed premortem. *Neurology* 1986;36:1610–1614.
 433. Nandini M, Gourie-Devi M, Shankar SK, et al. Baló's concentric sclerosis diagnosed intravital on brain biopsy. *Clin Neurol Neurosurg* 1993;95:303–309.
 434. Selbst RG, Selhorst JB, Harbison JW, et al. Parainfectious optic neuritis: report and review following varicella. *Arch Neurol* 1983;40:347–350.
 435. Farris BK, Pickard DJ. Bilateral postinfectious optic neuritis and intravenous steroid therapy in children. *Ophthalmology* 1990;97:339–345.
 436. Benkö E, Sipos I. Einige Fälle von Opticus-Neuritis als Begleiterscheinung der Kerato-conjunctivitis epidemica. *Ophthalmology* 1963;146:83–86.
 437. Manor RS, Cohen S, Ben-Sira T. Bilateral acute retrobulbar optic neuropathy associated with epidemic keratoconjunctivitis in a compromised host. *Arch Ophthalmol* 1986;104:1271–1272.
 438. Audry-Chaboud D, Dumas R, Audry F, et al. Coxsackie B virus neuropapillitis. *Rev Otoneuroophthalmol* 1981;53:473–482.
 439. Spalton DJ, Murdoch I, Holder GE. Coxsackie B5 papillitis. *J Neurol Neurosurg Psychiatry* 1989;52:1310–1311.
 440. Gross JG, Sadun AA, Wiley CA, et al. Severe visual loss related to isolated peripapillary retinal and optic nerve head cytomegalovirus infection. *Am J Ophthalmol* 1989;108:691–698.
 441. Walsh FB, Hoyt WF. Clinical Neuro-Ophthalmology, 3rd ed. Baltimore, Williams & Wilkins, 1969:136.
 442. Galli M, Morelli R, Casellato A, et al. Retrobulbar optic neuritis in a patient with acute type B hepatitis. *J Neurol Sci* 1986;72:195–200.
 443. Achiron LR. Postinfectious hepatitis B optic neuritis. *Optomet Vis Sci* 1994;71:53–56.
 444. Ashworth J, Motto S. Infectious mononucleosis complicated by bilateral papilloretinal edema: report of a case. *N Engl J Med* 1947;237:544–545.
 445. Karpe G, Wising P. Retinal changes with acute reduction of vision as initial symptoms of infectious mononucleosis. *Acta Ophthalmol* 1948;26:19–23.
 446. Bonyngé TW, Von Hagen KO. Severe optic neuritis in infectious mononucleosis: report of a case. *JAMA* 1952;148:933–934.
 447. Frey T. Optic neuritis in children: infectious mononucleosis as an etiology. *Doc Ophthalmol* 1973;34:183–188.
 448. Jones J, Gardner W, Newman T. Severe optic neuritis in infectious mononucleosis. *Ann Emerg Med* 1988;17:361–364.
 449. Newman NJ, Lessell S. Bilateral optic neuropathies with remission in two HIV-positive men. *J Clin Neuroophthalmol* 1992;12:1–5.
 450. Sweeney BJ, Manji H, Gilson RJC, et al. Optic neuritis and HIV-1 infection. *J Neurol Neurosurg Psychiatry* 1993;56:705–707.
 451. Walsh FB, Ford FR. Central scotomas: their importance in topical diagnosis. *Arch Ophthalmol* 1940;24:500–534.
 452. Strom T. Acute blindness as post-measles complication. *Acta Paediatr* 1953;42:60–65.
 453. Tyler HR. Neurological complications of rubeola. *Medicine* 1957;36:147–167.
 454. Srivastava SP, Neman HV. Optic neuritis in measles. *Br J Ophthalmol* 1963;47:180–181.
 455. Hayden M. Erblindung beider augen nach masernerkrankung. *Klin Monatsbl Augenheilkd* 1970;156:539–543.
 456. Woodward JH. The ocular complications of mumps. *Ann Ophthalmol* 1907;16:7–38.
 457. Swab CM. Encephalitic optic neuritis and atrophy due to mumps: report of a case. *Arch Ophthalmol* 1938;19:926–929.
 458. Strong LE, Henderson JW, Gangitano JL. Bilateral retrobulbar neuritis secondary to mumps. *Am J Ophthalmol* 1974;78:331–332.
 459. Connolly JH, Hutchinson WM, Allen IV, et al. Carotid artery thrombosis, encephalitis, myelitis and optic neuritis associated with rubella virus infections. *Brain* 1975;98:583–594.
 460. Miller DH, Kay R, Schon F, et al. Optic neuritis following chickenpox in adults. *J Neurol* 1986;233:182–184.
 461. Purvin V, Hrisomalos N, Dunn D. Varicella optic neuritis. *Neurology* 1988;38:501–503.
 462. Gündüz K, Özdemiş O. Bilateral retrobulbar optic neuritis following unilateral herpes zoster ophthalmicus. *Ophthalmology* 1994;208:61–64.
 463. Deane JS, Bibby K. Bilateral optic neuritis following herpes zoster ophthalmicus. *Arch Ophthalmol* 1995;113:972–973.
 464. Colarizi A, Panico E. Atrofia secondaria del nervo ottico consecutiva a infezione carbonchiosa. *Bull Acad Med Roma* 1933;59:399–408.
 465. Smallberg GJ, Sherman SH, Pezeshkpour GH, et al. Optic neuropathy due to brain abscess. *Am J Ophthalmol* 1976;82:188–192.
 466. Abd Elrazak M. Brucella optic neuritis. *Arch Intern Med* 1991;151:776–778.
 467. McLean DR, Russell N, Khan MY. Neurobrucellosis: clinical and therapeutic features. *Clin Infect Dis* 1992;15:582–590.

468. Sweeney VP, Drance SM. Optic neuritis and compressive neuropathy associated with cat scratch disease. *Can Med Assoc J* 1970;103:1380–1381.
469. Gass JDM. Diseases of the optic nerve that may simulate macular disease. *Trans Am Acad Ophthalmol Otolaryngol* 1977;83:766–769.
470. Brazis PW, Stokes HR, Ervin FR. Optic neuritis in cat scratch disease. *J Clin Neuroophthalmol* 1986;6:172–174.
471. Miller NR, Walsh and Hoyt's Clinical Neuro-Ophthalmology, 4th ed. Baltimore, Williams & Wilkins, 1995:2895–2896.
472. Miller HG, Staton JB, Gibbons JL. Parainfectious encephalomyelitis and related syndromes: a critical review of the neurological complications of certain specific fevers. *QJ Med* 1956;25:427–505.
473. Groenouw A, Uthoff W. Beziehungen der allgemeinleiden und organerkrankungen zu veränderungen und krankheiten des sehorganes. Leipzig, Springer Verlag, 1911.
474. Lamb HD. A case of tuberculous papillitis with anatomic findings. *Am J Ophthalmol* 1937;20:390–396.
475. Boke W. Neuritische sehnerveränderungen bei der meningitis tuberculosa. *Klin Monatsbl Augenheilkd* 1955;126:678–683.
476. Mooney AJ. Some ocular sequelae of tuberculous meningitis. *Am J Ophthalmol* 1956;41:753–768.
477. Miller BW, Frenkel M. Report of a case of tuberculous retrobulbar neuritis and osteomyelitis. *Am J Ophthalmol* 1971;71:751–756.
478. Bajpai PC, Dikshit SK. Bilateral optic neuritis and encephalitis accompanying typhoid. *J Indian Med Assoc* 1958;30:54–57.
479. Glander VR, Illert H. Amaurose und Hemiparese nach Typhus abdominalis bei einem 3 jährigen Kinde. *Arch Kinderheilkd* 1958;158:164–170.
480. Sanders MD. Gastrointestinal and ocular disease. In: Mausolf FA, ed. *The Eye and Systemic Disease*. St Louis, CV Mosby, 1980:345.
481. Yen M-Y, Liu J-H. Bilateral optic neuritis following bacille Calmette-Guérin (BCG) vaccination. *J Clin Neuroophthalmol* 1991;11:246–249.
482. Shaw FE Jr, Graham DJ, Guess HA, et al. Postmarketing surveillance for neurologic adverse events reported after hepatitis B vaccination: experience of the first three years. *Am J Epidemiol* 1988;127:337–352.
483. Berkman N, Banzarti T, Dhaoui R, et al. Neuropapillite bilatérale avec décollement séreux du neuroépithélium, au décours d'une vaccination contre l'hépatite B. *Bull Soc Ophthalmol Fr* 1996;96:187–190.
484. Cormack HS, Anderson LP. Bilateral papillitis following antirabic inoculation: recovery. *Br J Ophthalmol* 1934;43:167–168.
485. Consul BN, Purohit GK, Chhabra HN. Antirabic vaccine optic neuritis. *Indian J Med Sci* 1968;22:630–632.
486. Chayakul V, Ishikawa S, Chotibut S, et al. Convergence insufficiency and optic neuritis due to anti-rabic inoculation. *Jpn J Ophthalmol* 1875;19:307–314.
487. Topaloglu H, Berker M, Kansu T, et al. Optic neuritis and myelitis after booster tetanus toxoid vaccination. *Lancet* 1992;339:178–179.
488. Wagener HP. Edema of the optic disks in cases of encephalitis. *Am J Med Sci* 1952;223:205–215.
489. McReynolds WU, Havener WH, Petrohelos MA. Bilateral optic neuritis following smallpox vaccination and diphtheria-tetanus toxoid. *Am J Dis Child* 1953;86:601–603.
490. Kazarian E, Gager W. Optic neuritis complicating measles, mumps, and rubella vaccination. *Am J Ophthalmol* 1978;86:544–547.
491. Perry HD, Mallen FJ, Grodin RW, et al. Reversible blindness in optic neuritis associated with influenza vaccination. *Ann Ophthalmol* 1979;11:545–550.
492. Ray CL, Dreizin IJ. Bilateral optic neuropathy associated with influenza vaccination. *J Neuroophthalmol* 1996;16:182–184.
493. Cangemi FE, Bergen RL. Optic atrophy following swine flu vaccination. *Ann Ophthalmol* 1980;12:857–863.
494. Bienfang DC, Kantowitz FG, Noble JL, et al. Ocular abnormalities after influenza immunization. *Arch Ophthalmol* 1977;95:1649.
495. Confavreux C, Suissa S, Saddier P, et al. Vaccinations and the risk of relapse in multiple sclerosis. *N Engl J Med* 2001;344:319–326.
496. DeStefano F, Verstraeten T, Jackson LA, et al. Vaccinations and risk of central nervous system demyelinating diseases in adults. *Arch Neurol* 2003;60:504–509.
497. Gout O. Vaccinations and multiple sclerosis. *Neurol Sci* 2001;22:151–154.
498. Gould H, Kaufman HE. Sarcoid of the fundus. *Arch Ophthalmol* 1961;65:453–456.
499. Hart WM Jr, Burde RM. Optic disk edema in sarcoidosis. *Am J Ophthalmol* 1979;88:769–771.
500. Spalton DJ, Sanders MD. Fundus changes in histologically confirmed sarcoidosis. *Br J Ophthalmol* 1981;65:348–358.
501. Beardsley TL, Brown SVL, Sydnor CF, et al. Eleven cases of sarcoidosis of the optic nerve. *Am J Ophthalmol* 1984;97:62–77.
502. Graham EM, Ellis CJK, Sanders MD, et al. Optic neuropathy in sarcoidosis. *J Neurol Neurosurg Psychiatry* 1986;49:756–763.
503. Sloan LL, Woods AC. Perimetric studies in syphilitic optic neuropathies. *Arch Ophthalmol* 1938;20:201–254.
504. Miller NR, Fine SL. *The Ocular Fundus in Neuro-Ophthalmologic Diagnosis: Sights and Sounds in Ophthalmology*. St Louis, CV Mosby, 1977.
505. Weinstein JM, Lexow SS, Spickard A. Acute syphilitic optic neuritis. *Arch Ophthalmol* 1981;99:1392–1395.
506. Carter JB, Hamill RJ, Matoba AY. Bilateral syphilitic optic neuritis in a patient with a positive test for HIV: case report. *Arch Ophthalmol* 1987;105:1485–1486.
507. Zambrano W, Perez GM, Smith JL. Acute syphilitic blindness in AIDS. *J Clin Neuroophthalmol* 1987;7:1–5.
508. Becerra LI, Ksiazek SM, Savino PJ, et al. Syphilitic uveitis in human immunodeficiency virus-infected and noninfected patients. *Ophthalmology* 1989;96:1727–1730.
509. Katz DA, Berger JR. Neurosyphilis in acquired immunodeficiency syndrome. *Arch Neurol* 1989;46:895–898.
510. Winward KE, Hamed LM, Glaser JS. The spectrum of optic nerve disease in human immunodeficiency virus infection. *Am J Ophthalmol* 1989;107:373–380.
511. Blanche P, Diaz E, Gombert B, et al. Devic's neuromyelitis optica and HIV-1 infection. *J Neurol Neurosurg Psychiatry* 2000;68:795–796.
512. Grossniklaus HE, Frank KE, Tomsak RL. Cytomegalovirus retinitis and optic neuritis in acquired immune deficiency syndrome: report of a case. *Ophthalmology* 1987;94:1601–1604.
513. Grossniklaus HE, Specht CS, Allaire G, et al. *Toxoplasma gondii* retinochoroiditis and optic neuritis in acquired immune deficiency syndrome: report of a case. *Ophthalmology* 1990;97:1342–1346.
514. Litoff D, Catalano RA. Herpes zoster optic neuritis in human immunodeficiency virus infection. *Arch Ophthalmol* 1990;108:782–783.
515. Golnik KC, Newman SA, Wispelway B. Cryptococcal optic neuropathy in the acquired immune deficiency syndrome. *J Clin Neuroophthalmol* 1991;11:96–103.
516. Friedman DI. Neuro-ophthalmologic manifestations of human immunodeficiency virus infection. *Neurol Clin* 1991;9:55–72.
517. Nichols JW, Goodwin JA. Neuro-ophthalmologic complications of AIDS. *Semin Ophthalmol* 1992;7:24–29.
518. Holland GN, Engstrom RE Jr, Glasgow BJ, et al. Ocular toxoplasmosis in patients with the acquired immunodeficiency syndrome. *Am J Ophthalmol* 1988;106:653–657.
519. Falcone PM, Notis C, Merhige K. Toxoplasmic papillitis as the initial manifestation of acquired immunodeficiency syndrome. *Ann Ophthalmol* 1993;25:56–57.
520. Ohnuma I, Yamaguchi K, Takahashi S. Retrobulbar neuritis in a patient with mixed connective tissue disease. *Folia Ophthalmol Jpn* 1996;47:828–831.
521. Fulford KWM, Catterall RD, Delhanty JJ, et al. A collagen disorder of the nervous system presenting as multiple sclerosis. *Brain* 1972;95:373–386.
522. Hackett ER, Martinez RD, Larson PF, et al. Optic neuritis in systemic lupus erythematosus. *Arch Neurol* 1974;31:9–11.
523. Shepherd DI, Downie AW, Best PV. Systemic lupus erythematosus and multiple sclerosis. *Arch Neurol* 1974;30:423–426.
524. Jabs DA, Miller NR, Newman SA, et al. Optic neuropathy in systemic lupus erythematosus. *Arch Ophthalmol* 1986;104:564–568.
525. Kinney EL, Berdoff RL, Rao NS, et al. Devic's syndrome and systemic lupus erythematosus: a case report with necropsy. *Arch Neurol* 1979;36:643–644.
526. Oppenheimer S, Hoffbrand BI. Optic neuritis and myelopathy in systemic lupus erythematosus. *Can J Neurol Sci* 1986;13:129–132.
527. Tola MR, Granieri E, Caniatti L, et al. Systemic lupus erythematosus presenting with neurological disorders. *J Neurol* 1992;239:61–64.
528. Cordeiro ME, Lloyd ME, Spalton DJ, et al. Ischaemic optic neuropathy, transverse myelitis and epilepsy in an antiphospholipid positive patient with systemic lupus erythematosus. *J Neurol Neurosurg Psychiatry* 1994;57:1142–1143.
529. Bonnet F, Mercie P, Morlat P, et al. Devic's neuromyelitis optica during pregnancy in a patient with systemic lupus erythematosus. *Lupus* 1999;8:244–247.
530. Giorgi D, Balacco Gabrieli C, Bonomo L. The association of optic neuropathy with transverse myelitis in systemic lupus erythematosus. *Rheumatology (Oxf)* 1999;38:191–192.
531. Dutton JJ, Burde RM, Klingele TC. Autoimmune retrobulbar optic neuritis. *Am J Ophthalmol* 1982;94:11–17.
532. Kupersmith MJ, Burde RM, Warren FA, et al. Autoimmune optic neuropathy: evaluation and treatment. *J Neurol Neurosurg Psychiatry* 1988;51:1381–1386.
- 532a. Kidd D, Burton B, Plant GT, et al. Chronic relapsing inflammatory optic neuropathy (CRION). *Brain* 2003;126:276–284.
533. Winward KE, Smith JL, Culbertson WW, et al. Ocular Lyme borreliosis. *Am J Ophthalmol* 1989;108:651–657.
534. Lesser RL, Kornmehl EW, Pachner AR, et al. Neuro-ophthalmologic manifestations of Lyme disease. *Ophthalmology* 1990;97:699–706.
535. Winterkorn JMS. Lyme disease: Neurologic and ophthalmologic manifestations. *Surv Ophthalmol* 1990;35:191–204.
536. Jacobson DM, Marx JJ, Dlesk A. Frequency and clinical significance of Lyme seropositivity in patients with isolated optic neuritis. *Neurology* 1991;41:706–711.
537. Spoor TC, Hartel WC, Harding S, et al. Aspergillosis presenting as a corticosteroid-responsive optic neuropathy. *J Clin Neuroophthalmol* 1982;2:103–107.
538. Weinstein JM, Sattler FA, Towfighi J, et al. Optic neuropathy and paratrigeminal syndrome due to *Aspergillus fumigatus*. *Arch Neurol* 1982;39:582.
539. Kirkham TH, Fyfe T, Sanders MD. Placoid pigment epitheliopathy with retinal vasculitis and papillitis. *Br J Ophthalmol* 1972;56:875–880.
540. Goldstein NP, Rucker CW, Woltman HW. Neuritis occurring after insect stings. *JAMA* 1960;173:1727–1730.

541. Singh I, Chaudhary U. Bilateral optic neuritis following multiple wasp stings. *J Indian Med Assoc* 1986;84:251–252.
542. Song HS, Wray SH. Bee sting optic neuritis: a case report with visual evoked potentials. *J Clin Neuroophthalmol* 1991;11:45–49.
543. Berrios RR, Serrano LA. Bilateral optic neuritis after a bee sting [letter]. *Am J Ophthalmol* 1994;117:677–678.
544. Colvard DM, Robertson DM, O'Duffy JD. The ocular manifestations of Behçet's disease. *Arch Ophthalmol* 1977;95:1813–1817.
545. Ryan SJ, Maumenee AE. Birdshot retinochoroidopathy. *Am J Ophthalmol* 1980;89:31–45.
546. Lesser RL, Albert DM, Bobowick AR, et al. Creutzfeldt-Jakob disease and optic atrophy. *Am J Ophthalmol* 1979;87:317–321.
547. Roth AM, Keltner JL, Ellis WG, et al. Virus-simulating structures in the optic nerve head in Creutzfeldt-Jakob disease. *Am J Ophthalmol* 1979;87:827–833.
548. Bawa YS, Wahi PL. Cysticercosis cellulosa of the optic disc with generalized cysticercosis. *Br J Ophthalmol* 1962;46:753–755.
549. Lossos A, Eliashiv S, Ben-Chetrit E, et al. Optic neuritis associated with familial Mediterranean fever. *J Clin Neuroophthalmol* 1993;13:141–143.
550. Vlodarczyk S. Un cas de syndrome de Guillain-Barré avec névrite optique retro-bulbaire. *Neurol Pol* 1949;23:110–115.
551. Mouren P, Vital-Berard P, Poinso Y, et al. Névrite optique retro-bulbaire au cours d'un syndrome de Guillain-Barré. *Rev Otoneuroophthalmol* 1971;43:216–221.
552. Nikoskelainen E, Riekkinen P. Retrobulbar neuritis as an early symptom on Guillain-Barré syndrome. *Acta Ophthalmol* 1972;50:111–115.
553. Behan PO, Lessell S, Roche M. Optic neuritis in the Landry-Guillain-Barré-Strohl syndrome. *Br J Ophthalmol* 1976;60:58–59.
554. Ellis PP, Gentry JH. Ocular complications of ulcerative colitis. *Am J Ophthalmol* 1964;58:779–785.
555. Macoul KL. Ocular changes in granulomatous ileocolitis. *Arch Ophthalmol* 1970;84:95–97.
556. Knox DL. Optic nerve manifestations of systemic diseases. *Trans Am Acad Ophthalmol Otolaryngol* 1977;83:743–750.
557. Knox DL, Bayless TM. Gastrointestinal and ocular disease. In: Mausolf FA, ed. *The Eye and Systemic Disease*. St Louis, CV Mosby, 1980:333–344.
558. Sedwick LA, Klingele TG, Burde RM, et al. Optic neuritis in inflammatory bowel disease. *J Clin Neuroophthalmol* 1984;4:3–6.
559. Hutnik CML, Nicolle DA, Canny CLB. Papillitis: a rare initial presentation of Crohn's disease. *Can J Ophthalmol* 1996;31:373–376.
560. Bird AC, Smith JL, Curtin VT. Neomatode optic neuritis. *Am J Ophthalmol* 1970;69:72–77.
561. Phillips CI, Mackenzie AD. Toxocara larval papillitis. *Br Med J* 1973;1:154–155.
562. Husted RC, Shock JP. Acute presumed histoplasmosis of the optic nerve head. *Br J Ophthalmol* 1975;59:409–412.
563. Beck RW, Sergott RC, Barr CC, et al. Optic disc edema in the presumed ocular histoplasmosis syndrome. *Ophthalmology* 1984;91:183–185.
564. Duke-Elder S. Diseases of the outer eye. In: *System of Ophthalmology*. London, Henry Kimpton, 1965:1:527–532.
565. Bietti GB, Bruna F. An ophthalmic report on Behçet's disease. In: Monacelli M, Nazzaro P, eds. *Symposium on Behçet's Disease*. Basel, S Karger, 1966:79–110.
566. Cox TA, Haskins GE, Gangitano JL, et al. Bilateral *Toxocara* optic neuropathy. *J Clin Neuroophthalmol* 1983;3:267–274.
567. Willerson D, Aaberg TM, Reeser F, et al. Unusual ocular presentation of acute toxoplasmosis. *Br J Ophthalmol* 1977;61:693–698.
568. Folk JC, Lobes LA. Presumed toxoplasmic papillitis. *Ophthalmology* 1984;91:64–67.
569. Rothstein TL, Kenny GE. Cranial neuropathy, myeloradiculopathy, and myositis: complications of *Mycoplasma pneumoniae* infection. *Arch Neurol* 1979;36:476–477.
570. Salzman MB, Sood SK, Slavin ML, et al. Ocular manifestations of *Mycoplasma pneumoniae* infection. *Clin Infect Dis* 1992;14:1137–1139.
571. Nadkarni N, Lisak RP. Guillain-Barré syndrome (GBS) with bilateral optic neuritis and white matter disease. *Neurology* 1993;43:842–843.
572. Sheth RD, Goulden KJ, Pryse-Phillips WE. The focal encephalopathies associated with *Mycoplasma pneumoniae*. *Can J Neurol Sci* 1993;20:319–323.
573. Porsaa K. Papilledema in iridocyclitis. *Acta Ophthalmol* 1944;21:316–329.
574. Kimura SJ, Hogan MJ. Chronic cyclitis. *Arch Ophthalmol* 1964;71:193–201.
575. Tillmann W, Ufermann K. Papillenschwellung bei uveitis. *Klin Monatsbl Augenheilkd* 1972;161:42–46.
576. Irvine SR. A newly defined vitreous syndrome following cataract surgery. *Am J Ophthalmol* 1953;36:599–619.
577. Gass JDM, Norton EWD. Cystoid macular edema and papilledema following cataract extraction. *Arch Ophthalmol* 1966;76:646–661.
578. Norton AL, Brown WJ, Carlson M, et al. Pathogenesis of aphakic macular edema. *Am J Ophthalmol* 1975;80:96–101.
579. Hanna LS, Girgis NI. Incidence of papilloedema and optic atrophy in meningitis. *Jpn J Ophthalmol* 1981;25:69–73.
580. McIntyre HD, McIntyre AP. Prognosis of multiple sclerosis. *Arch Neurol Psychiatr* 1943;50:431–438.
581. White DN, Wheelan L. Disseminated sclerosis: a survey of patients in the Kingston, Ontario, area. *Neurology* 1959;9:256–272.
582. Rischbieth RC. Retrobulbar neuritis in the State of South Australia. *Proc Aust Assoc Neurol* 1968;5:573–575.
583. Nakao Y, Omoto T, Shimomura Y. Optic neuritis in children. *Folia Ophthalmol Jpn* 1983;34:496–498.
584. Keast-Butler J, Taylor D. Optic neuropathies in children. *Trans Ophthalmol Soc UK* 1980;100:111–118.
585. Cohen G, Gitter K, Baber BW. Reversible bilateral simultaneous papillitis with no light perception. *Ann Ophthalmol* 1976;8:583–586.
586. Rollinson RD. Bilateral optic neuritis in childhood. *Med J Aust* 1977;2:50–51.
587. Koraszewska-Matuszewska B, Samochowiec-Donocik E, Rynkiewicz E. Optic neuritis in children and adolescents. *Klin Oczna* 1995;97:207–210.
588. Good WV, Muci-Mendoza R, Berg BO, et al. Optic neuritis in children with poor recovery of vision. *Aust NZ J Ophthalmol* 1992;20:319–323.
589. Brady KM, Brar AS, Lee AG, Coats, et al. Optic neuritis in children: clinical features and visual outcome. *J AAPOS* 1999;3:98–103.
590. Morales DS, Siatkowski RM, Howard CW, et al. Optic neuritis in children. *J Pediatr Ophthalmol Strabismus* 2000;37:254–259.
591. Rush JA. Idiopathic optic neuritis of childhood. *J Pediatr Ophthalmol Strabismus* 1981;18:39–41.
592. Leber T. Pseudoneuritic retinal disease, stellate retinitis: the angiopathic retinal affections after severe skull injury. *Graefe-Saemisch Handb Ges Augenheilkd* 1916;7:1319.
593. Francois J, Verriest G, DeLaey J. Leber's idiopathic stellate retinopathy. *Am J Ophthalmol* 1969;68:340–345.
594. Dreyer RF, Hopen G, Gass DM, et al. Leber's idiopathic stellate neuroretinitis. *Arch Ophthalmol* 1984;102:1140–1145.
595. Maitland CG, Miller NR. Neuroretinitis. *Arch Ophthalmol* 1984;102:1146–1150.
596. Carroll DM, Franklin RM. Leber's idiopathic stellate retinopathy. *Am J Ophthalmol* 1982;93:96–101.
597. Neetens A, Smets RM. Leber's neurogenic stellate maculopathy. *Neuroophthalmology* 1987;7:315–328.
598. Guillaume J-B, Risse JF, Rovira JC. Neurorétinite aigue: discussion nosologique à propos d'un cas chez un adulte jeune. *Bull Soc Ophthalmol Fr* 1991;91:39–42.
599. King MN, Cartwright MJ, Carney MD. Leber's idiopathic neuroretinitis. *Arch Ophthalmol* 1991;23:58–60.
600. Weiss AH, Beck RW. Neuroretinitis in childhood. *J Pediatr Ophthalmol* 1989;26:198–203.
601. Johnson BL, Wisetzley HM. Neuroretinitis associated with herpes simplex encephalitis in an adult. *Am J Ophthalmol* 1977;83:481–489.
602. Farthing CF, Howard RS, Thin RN. Papillitis and hepatitis B. *Br Med J* 1986;292:1712.
603. Margolis T, Irvine AR, Hoyt WF, et al. Acute retinal necrosis syndrome presenting with papillitis and acute neuroretinitis. *Ophthalmology* 1988;95:937–940.
604. Ulrich GG, Waecker NJ Jr, Meister SJ, et al. Cat scratch disease associated with neuroretinitis in a 6-year-old girl. *Ophthalmology* 1992;99:246–249.
605. Bar S, Segal M, Shapira R, et al. Neuroretinitis associated with cat scratch disease. *Am J Ophthalmol* 1990;110:703–705.
606. Chrousos GA, Drack AV, Young M, et al. Neuroretinitis in cat scratch disease. *J Clin Neuroophthalmol* 1990;10:92–94.
607. Arruga J, Valentines J, Mauri F, et al. Neuroretinitis in acquired syphilis. *Ophthalmology* 1985;92:262–270.
608. Fewell AG. Unilateral neuroretinitis of syphilitic origin with a striate figure in the macula. *Arch Ophthalmol* 1932;8:615.
609. Folk JC, Weingeist TA, Corbett JJ, et al. Syphilitic neuroretinitis. *Am J Ophthalmol* 1983;95:480–496.
610. Veldman E, Bos PJM. Neuroretinitis in secondary syphilis. *Doc Ophthalmol* 1986;64:23–29.
611. McLeish WM, Pulido JS, Holland S, et al. The ocular manifestations of syphilis in the human immunodeficiency virus type 1-infected host. *Ophthalmology* 1990;97:196–203.
612. Ninomiya H, Hamada T, Akiya S, et al. Three cases of acute syphilitic neuroretinitis. *Folia Ophthalmol Jpn* 1990;41:2088–2094.
613. Halperin LS. Neuroretinitis due to seronegative syphilis associated with human immunodeficiency virus. *J Clin Neuroophthalmol* 1992;12:171–172.
614. Graveson GS. Syphilitic optic neuritis. *J Neurol Neurosurg Psychiatry* 1950;13:216–224.
615. Bialiasiewicz AA, Huk W, Druschky KF, et al. *Borrelia burgdorferi*-Infektion mit beidseitiger Neuritis nervici optici und intrazerebralen Demyelinisierungsherden. *Klin Monatsbl Augenheilkd* 1989;195:91–94.
616. Schönherr U, Wilk CM, Lang GE, et al. Intraocular manifestations of Lyme borreliosis. Presented at the Fourth International Conference on Borreliosis, Stockholm, Sweden, June 18–21, 1990.
617. Schönherr U, Lang GE, Meythaler FH. Bilaterale Lebersche Neuroretinitis stellata bei *Borrelia burgdorferi*-Serokonversion. *Klin Monatsbl Augenheilkd* 1991;198:44–47.
618. Manschot WA, Daamen CBF. Congenital ocular toxoplasmosis. *Arch Ophthalmol* 1965;74:48–54.

619. Brown GC, Tasman WS. Retinal arterial obstruction in association with presumed *Toxocara canis* neuroretinitis. *Ann Ophthalmol* 1981;13:1385–1387.
620. Moreno RJ, Weisman J, Waller S. Neuroretinitis: an unusual presentation of ocular toxoplasmosis. *Ann Ophthalmol* 1992;24:68–70.
621. Fish RH, Hoskins JC, Kline LB. Toxoplasmosis neuroretinitis. *Ophthalmology* 1993;100:1177–1182.
622. Parmley VC, Schiffman JS, Maitland CG, et al. Does neuroretinitis rule out multiple sclerosis? *Arch Neurol* 1987;44:1045–1048.
623. Ormerod LD, Dailey JP. Ocular manifestations of cat-scratch disease. *Curr Opin Ophthalmol* 1999;10:209–216.
624. Conrad DA. Treatment of cat-scratch disease. *Curr Opin Pediatr* 2001;13:56–59.
625. Centers for Disease Control. 1989 Sexually transmitted diseases treatment guidelines. *MMWR* 1989;38(Suppl 8):9.
626. Purvin VA, Chioran G. Recurrent neuroretinitis. *Arch Ophthalmol* 1994;112:365–371.
627. Edmunds W, Lawford JB. Examination of optic nerve from a case of amblyopia in diabetes. *Trans Ophthalmol Soc UK* 1883;3:160–162.
628. Silverstein A. Papilledema with acute viral infections of the brain. *Mt Sinai Med J* 1974;41:425–443.
629. Kline LB, Jackson WB. Syphilitic optic perineuritis and uveitis. In: Smith JL, ed. *Neuro-ophthalmology Focus* 1980. New York, Masson, 1979:77–84.
630. Rush JA, Ryan EJ. Syphilitic optic perineuritis. *Am J Ophthalmol* 1981;91:404–406.
631. McBurney J, Rosenberg ML. Unilateral syphilitic optic perineuritis presenting as the big blind spot syndrome. *J Clin Neuroophthalmol* 1987;7:167–169.
632. Toshniwal P. Optic perineuritis with secondary syphilis. *J Clin Neuroophthalmol* 1987;7:6–10.
633. Purvin V, Kawasaki A, Jacobson DM. Optic perineuritis: clinical and radiographic features. *Arch Ophthalmol* 2001;119:1299–1306.
634. Dutton JJ, Anderson RL. Idiopathic inflammatory peri optic neuritis simulating optic nerve sheath meningioma. *Am J Ophthalmol* 1985;100:424–430.
635. Gibbs AN, Moroney J, Foley-Nolan D, et al. Neuromyelitis optica (Devic's syndrome) in systemic lupus erythematosus: a case report. *Rheumatology (Oxf)* 2000;41:470–471.
636. Moll JW, Markusse HM, Pijnenburg JJ, et al. Antineuronal antibodies in patients with neurologic complications of primary Sjögren's syndrome. *Neurology* 1993;43:2574–2581.
637. Manley G, Wong E, Dalmau J, et al. Sera from some patients with antibody-associated paraneoplastic encephalomyelitis/sensory neuropathy recognize the Ro-52K antigen. *J Neurooncol* 1994;19:105–112.
638. Vitali C, Bombardieri S, Moutsopoulos HM, et al. Assessment of the European classification criteria for Sjögren's syndrome in a series of clinically defined cases: results of a prospective multicentre study. The European Study Group on Diagnostic Criteria for Sjögren's Syndrome. *Ann Rheum Dis* 1996;55:116–121.
639. Mochizuki A, Hayashi A, Hisahara S, et al. Steroid-responsive Devic's variant in Sjögren's syndrome. *Neurology* 2000;54:1391–1392.
640. Fukazawa T, Hamada T, Kikuchi S, et al. Antineutrophil cytoplasmic antibodies and the optic-spinal form of multiple sclerosis in Japan. *J Neurol Neurosurg Psychiatry* 1996;61:203–204.
641. Harada T, Ohashi T, Harada C, et al. A case of bilateral optic neuropathy and recurrent transverse myelopathy associated with perinuclear anti-neutrophil cytoplasmic antibodies (p-ANCA). *J Neuroophthalmol* 1997;17:254–256.
642. Fukazawa T, Morioka F, Mukai M, et al. Anticardiolipin antibodies in Japanese patients with multiple sclerosis. *Acta Neurol Scand* 1993;88:184–189.
643. Karussis D, Leker RR, Ashkenazi A, et al. A subgroup of multiple sclerosis patients with anticardiolipin antibodies and unusual clinical manifestations: do they represent a new nosological entity? *Ann Neurol* 1998;44:629–634.
644. Weiss TD, Nelson JS, Woolsey RM, et al. Transverse myelitis in mixed connective tissue disease. *Arthritis Rheum* 1978;21:982–986.
645. Flechtner KM, Baum K. Mixed connective tissue disease: recurrent episodes of optic neuropathy and transverse myelopathy: successful treatment with plasmapheresis. *J Neurol Sci* 1994;126:146–148.
646. Hughes RA, Mair WG. Acute necrotic myelopathy with pulmonary tuberculosis. *Brain* 1977;100:223–228.
647. Doutlik S, Sblova O, Kryl R, et al. Neuromyelitis optica as a parainfectious complication of varicella. *Cesk Neurol Neurochir* 1975;38:238–242.
648. Tateishi J, Ikeda H, Saito A, et al. Myeloneuropathy in dogs induced by iodoxy-quinoline. *Neurology* 1972;22:702–709.
649. Tateishi J, Kuroda S, Saito A, et al. Experimental myelo-optic neuropathy induced by clioquinol. *Acta Neuropathol (Berl)* 1973;24:304–320.
650. Donati E, Bargnani C, Besana R, et al. Subacute myelo-optic neuropathy (SMON) induced by antituberculous treatment in uraemia. *Funct Neurol* 1990;5:151–154.
651. Afifi AK, Follett KA, Greenlee J, et al. Optic neuritis: a novel presentation of Schilder's disease. *J Child Neurol* 2001;16:693–696.
652. Levin LA, Lessell S. Risk of multiple sclerosis after optic neuritis. *JAMA* 2003;290:403–404.

