

---

# The Torn Posterior Capsule: Prevention, Recognition, and Management

## INTRODUCTION

## GENERAL PREDISPOSING FACTORS

## INTRAOPERATIVE COMPLICATIONS

- Inadequate Capsulorrhexis
- Nucleus Rotation Problems
- Anterior Chamber Shallowing

## TORN POSTERIOR CAPSULE

- Recognition
- Management

## MANAGEMENT OF SELECTED COMPLICATIONS

- Vitrectomy for Vitreous in Anterior Chamber
- Lost Nucleus or Nuclear Fragments
- Zonular Dialysis
- Postoperative Care

## BRIEF CLINICAL REVIEW

## CONCLUSION

## CLINICIAN'S CORNER

---

**Cover: Figure 7.** Method of bimanual vitrectomy. An irrigation cannula provides irrigation through the paracentesis. Vitrectomy is performed deep to the posterior capsular tear to draw vitreous back without enlarging the tear.

## Focal Points Editorial Review Board

Michael W. Belin, M.D., Albany, NY; *Editor-in-Chief; Cornea, External Disease & Refractive Surgery; Optics & Refraction* • Careen Yen Lowder, M.D., Ph.D., Cleveland, OH; *Ocular Inflammation & Tumors* • Jeffrey A. Nerad, M.D., Iowa City, IA; *Oculoplastic, Lacrimal & Orbital Surgery* • Priscilla Perry, M.D., Monroe, LA; *Cataract Surgery; Liaison for Practicing Ophthalmologists Advisory Committee for Education* • Lyn A. Sedwick, M.D., Orlando, FL; *Neuro-Ophthalmology* • Charles Henry, Little Rock, AR; *Glaucoma* • Paul Sternberg Jr., M.D., Atlanta, GA; *Retina & Vitreous* • Kenneth W. Wright, M.D., Los Angeles, CA; *Pediatric Ophthalmology & Strabismus*

## Focal Points Staff

Susan R. Keller, Managing Editor • Kirsten E. Cowan, Editorial & Production Coordinator • Suzanne Olivier, Medical Editor • Bill Romano, Designer

## Clinical Education Secretaries and Staff

Thomas A. Weingeist, Ph.D., M.D., Iowa City; Senior Secretary • Michael A. Kass, M.D., St. Louis; Secretary • Kathryn A. Hecht, Ed.D., Vice President • Hal Straus, Director of Publications

*Focal Points* (ISSN 0891-8260) is published quarterly by the American Academy of Ophthalmology, 655 Beach St., San Francisco, CA 94109-1336. Yearly subscriptions are \$110 for Academy members and \$160 for nonmembers. Periodicals postage paid at San Francisco, CA, and additional mailing offices. POSTMASTER: Send address changes to *Focal Points*, P.O. Box 7424, San Francisco, CA 94120-7424.

The author(s) listed made a major contribution to this module. Substantive editorial revisions may have been made based on reviewer recommendations. This Continuing Medical Education activity was planned and produced in accordance with ACCME Essentials. *Focal Points* is one component of the Lifelong Education for the Ophthalmologist (LEO) framework, which assists members in planning their CME. LEO includes an array of products and programs that members may select to form individualized, self-directed learning plans for updating their clinical knowledge. Active members or fellows who use LEO components may accumulate sufficient CME credits to earn the LEO Award. Contact the Academy's Clinical Education Division for more information. ©1999 American Academy of Ophthalmology. All rights reserved.

The Academy provides this material for educational purposes only. It is not intended to represent the only or best method or procedure in every case, nor to replace a physician's own judgment or give specific advice for case management. Including all indications, contraindications, side effects and alternative agents for each drug or treatment is beyond the scope of this material. All information and recommendations should be verified, prior to use, with current information included in the manufacturers' package inserts or other independent sources, and considered in light of the patient's condition and history. Reference to certain drugs, instruments and other products in this publication is made for illustrative purposes only and is not intended to constitute an endorsement of such. Some material may include information on applications that are not considered community standard, that reflect indications not included in approved FDA labeling, or that are approved for use only in restricted research settings. The FDA has stated that it is the responsibility of the physician to determine the FDA status of each drug or device he or she wishes to use, and to use them with appropriate patient consent in compliance with applicable law. The Academy specifically disclaims any and all liability for injury or other damages of any kind, from negligence or otherwise, for any and all claims that may arise out of the use of any recommendations or other information contained herein.

Any significant financial interest or other relationship any author of this publication may have with the manufacturer(s) of any commercial product(s) discussed in sections to which he or she contributed is disclosed in text, after the author's affiliations.

NOTICE: THIS MATERIAL MAY BE PROTECTED BY  
COPYRIGHT LAW (TITLE 17, U.S. CODE)

## Learning Objectives

The study of this Focal Points module will help the reader to:

- Identify predisposing factors for posterior capsular rupture and where possible correct them
- Identify and treat the various causes of the intraoperative shallow anterior chamber
- Gain a greater degree of proficiency in dealing with capsular tears and nuclear pieces during phacoemulsification and conversion to extracapsular cataract extraction (ECCE)
- Describe the principles of performing bimanual vitrectomy
- Initiate postoperative treatment in cases of torn posterior capsule and vitrectomy

**Key Words:** capsulorrhexis complications, phacoemulsification, posterior capsular tears, shallow anterior chamber, suprachoroidal hemorrhage, vitrectomy

## Introduction

Modern cataract surgery performed with phacoemulsification allows meticulous intraocular control and minimal incision size, but has the inherent risk of capsular rupture. Therefore, surgeons performing cataract surgery will inevitably face the complication of a torn posterior capsule. Torn posterior capsules are reported to occur in 0.3%–6% of cases. Faced with this complication, it is best for a surgeon to approach its management with the same systematic analytical and objective evaluation that would be applied to any surgery. Keep in mind that “great opportunity is usually disguised as an unsolvable problem.” Proper resolution will then provide the patient with the best surgical, and therefore the best visual, outcome.

## General Predisposing Factors

Significant factors that may lead to a torn posterior capsule are listed in Table 1. The first of these factors is poor visibility, which may be caused by either physical problems or pathology. Physical problems that may lead to poor visibility include the relationship of the surgeon’s hand position to the patient’s brow,

**Table 1. General Predisposing Factors for the Torn Posterior Capsule**

### Significant Factors

Poor visibility:

Secondary to physical problems:

hand position, deep-set brow, fluid pooling, globe torsion

Secondary to pathology:

dense arcus senilis, pterygia, Fuch’s corneal dystrophy, band keratopathy, corneal scars, interstitial keratitis

Long and short axial length eyes

Pseudoexfoliation

Cataracts:

“Black”

“White”

Posterior polar (calcified)

Dense asteroid hyalosis

Small pupils

### Additional Factors

Previous trauma

(unseen capsular rupture or zonular damage)

Inadequate microscope illumination or alignment

Equipment malfunction

Inexperienced surgeons

Demented, disoriented, or anxious patients  
(inadvertent movement during procedure)

pooling of irrigation fluid, and torsion of the globe. If the brow is prominent (i.e., a deep-set eye), for example, a temporal rather than a superior approach will minimize inferior torsion of the globe. If there is pooling of fluid, turning the head temporally will allow fluid to drain. The use of an open-bladed speculum that allows easy access to the globe and will not impede phacoemulsification cannot be underestimated. Although it may be preferable to operate in the axis of plus cylinder, this cannot be done when the plus cylinder is at 90° in the presence of a large brow and deep-set eye. The surgeon is wiser to forego the issue of astigmatism and operate temporally for access and exposure rather than risk a capsular tear.

Poor visibility can also be caused by pathology such as dense arcus senilis, dense nasal or temporal ptery-

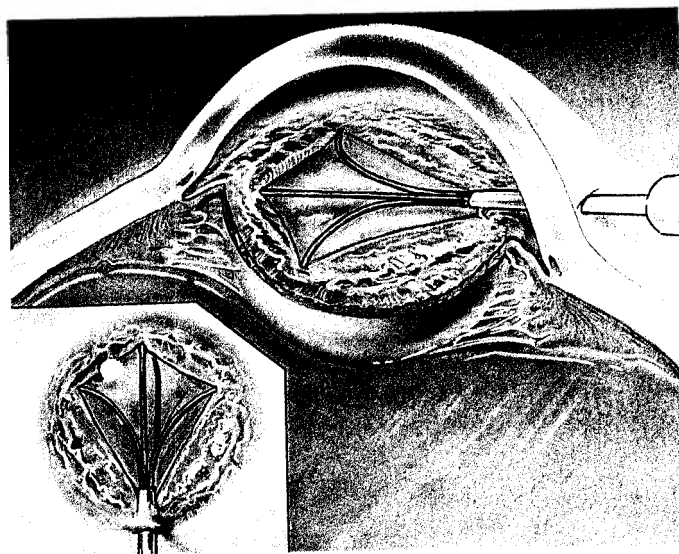
gia, severe Fuch's corneal dystrophy with or without associated corneal edema, band keratopathy, old corneal scars, and interstitial keratitis. Faced with these challenges to visualization, the surgeon can do nothing but slow down, pay more attention to detail and visualization, and be more careful about focusing (slow the microscope focus speed) through the corneal problem to allow visualization of the anterior segment.

Patients with long or short axial length eyes, with the associated deep or shallow anterior chambers, also have predisposing factors for torn capsules. In high myopia, the anterior chamber is deeper, with more trampolening of the posterior capsule due to the thinner, more resilient tissues. Eyes that have undergone previous vitrectomy behave in a similar manner. During phacoemulsification, lowering the infusion bottle lessens this tendency. In high hyperopia, the anterior chamber is crowded, making the posterior capsule closer to the area of phacoemulsification, increasing the risk of a torn capsule. In this situation the early use of pulsed or burst phacoemulsification will help to deepen the anterior chamber. Other causes of the shallow anterior chamber are considered later in this article.

Pseudoexfoliation is known to cause weak zonules and poor pupillary dilation secondary to fibrosis of the pupillary sphincter. These problems lead to an increased incidence of torn posterior capsules or dehiscence of the zonules.

Markedly brunescient or "black" cataracts as well as mature or "white" cataracts make capsulorrhexis more difficult. In the presence of an inadequate capsulorrhexis and a hard cataract, the chance of tearing the capsulorrhexis peripherally increases significantly. Sam Masket, M.D., has proposed using a retinal light probe held near the limbus to provide "side light" while lowering the microscope and room illumination. This allows the surgeon to better visualize the tearing edge of the capsule during capsulorrhexis, improving successful completion in these difficult situations. Other potential solutions include staining the anterior capsule with indocyanine green. To do this, dissolve 25 mg of indocyanine green dye in 0.5 mL aqueous solvent, then add 4.5 mL balanced saline solution (BSS Plus). The resulting solution will have a concentration of 0.5% and an osmolarity of 270 mOsm. With a TB syringe, inject 0.1 cc of this solution under an air bubble in the anterior chamber, and then wash out the stain and air. The resulting stained anterior capsule will be readily visualized. Methylene blue can be used in a similar fashion, although toxicity studies have not yet been performed with this dye.

In addition, posterior polar cataracts (especially



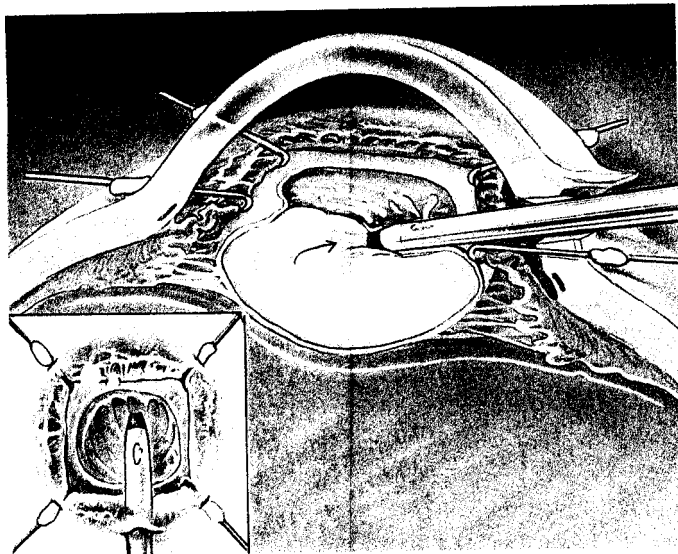
**Figure 1.** The use of the Beehler pupil dilator. The barrel of the instrument is rotated so that the hook is lateral as it is passed through the wound. It is then rotated further so that the hook is posterior and engages the subjacent iris. The three long prongs are then extended to create multiple microsphincterotomies and so dilate the iris (inset surgeon's view).

those that are calcified) are also a predisposing factor. This is due to an increased incidence of posterior capsular defects attributable to adherence of the cataract to the posterior capsule.

Dense asteroid hyalosis may make it difficult to visualize the posterior capsule during phacoemulsification. The surgeon must again use due caution, and if necessary viscoelastics, to stay away from the posterior capsule, thus avoiding inadvertent tears.

Small pupils are the final significant factor that may result in capsular tearing. Many regimens can provide adequate pharmacologic dilation in all patients. One recommended guideline is cyclopentolate hydrochloride (Cyclogel) 1%, phenylephrine (Neo-Synephrine) 2.5%, and a nonsteroidal anti-inflammatory such as ketorolac tromethamine (Acular) 0.5% given every 5 minutes for four doses prior to surgery. In those patients whose pupils have not dilated adequately, an additional dose of phenylephrine 10% gel is applied. Phenylephrine 10% solution is avoided, as recalcitrant cardiac arrhythmias have been reported in patients receiving this medication.

If the pupil does not dilate enough for the surgeon to safely perform phacoemulsification, or even to convert to ECCE, the surgeon is obligated to dilate it further surgically. This can be accomplished by stretching with iris hooks, using a pupil dilator such as the Beehler dilator made by Moria (see Figure 1), performing multiple sphincterotomies with microscissors,



**Figure 2.** The use of an iris retractor, this one made by Grieshaber. Four 1-mm paracentesis incisions are created parallel to the iris at the limbus. The hooks are then introduced and positioned to engage the iris. The hooks are tightened moderately to create a 6–7 mm square pupil (inset surgeon's view). After the procedure, the hooks are pushed forward to release the iris.

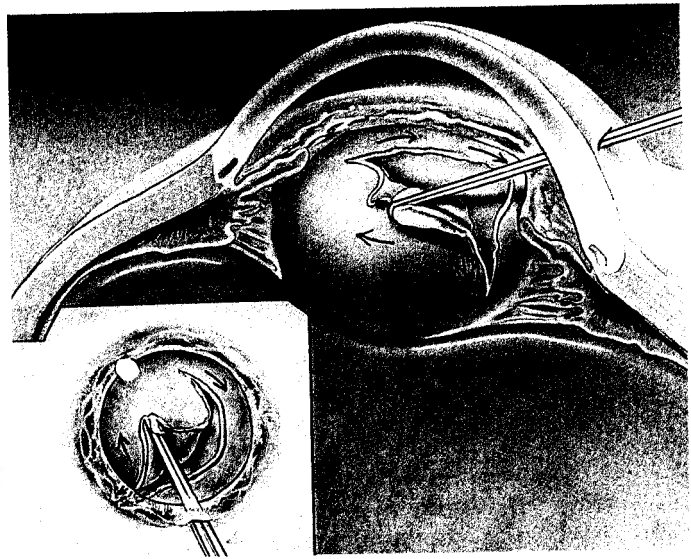
using iris retractors (see Figure 2), or using a pupil expander such as that made by Grieshaber.

Additional predisposing factors to complications could include the following: pre-existing trauma with unseen capsular rupture or zonular damage; poor microscope alignment or illumination; equipment malfunction; inexperienced surgeons; or demented, disoriented, or anxious patients with subsequent inadvertent patient movement. These additional predisposing factors are also listed in Table 1.

## Intraoperative Complications

### Inadequate Capsulorrhexis

Capsulorrhexis may be too small, too large, or non-continuous. If the capsulorrhexis is too small in relation to the maturity and size of the cataract, a zonulolysis (tearing or destruction of zonules while the capsular bag remains intact) may be created. This is accomplished either by catching the subincisional capsule with the phacoemulsification tip or by pulling on the capsule with aspiration opposite the incision. Removal of subincisional cortex may be considerably more difficult than with adequate capsulorrhexis. The additional instrument manipulation may be an antecedent to zonular disruption. During hydrodissection (the separation of the cortex from adjacent cortex or from the capsular bag), resistance to flow created by

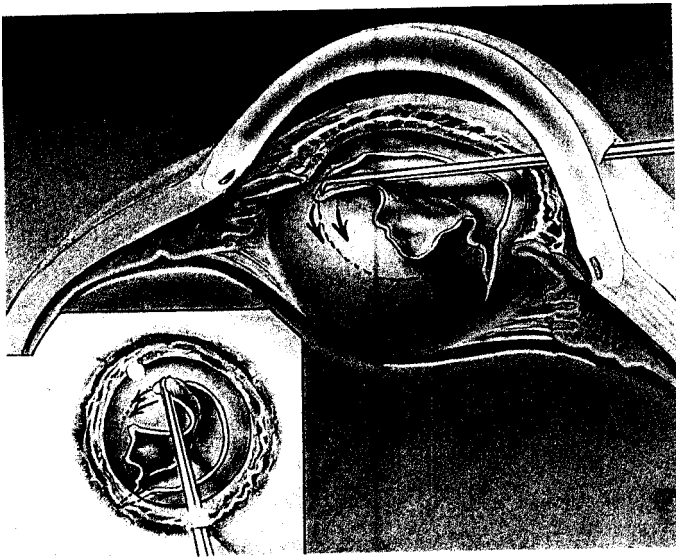


**Figure 3.** Posterior pressure causes the capsulorrhexis to extend peripherally into the zonules. Note the presence of posterior pressure by the anterior displacement of the iris (inset surgeon's view).

the small capsulorrhexis may lead to fluid accumulation deep to the nucleus and so may precipitate a posterior capsular tear. In contrast, a large capsulorrhexis may incorporate zonules, predisposing the procedure to causing zonular dehiscence.

Noncontinuous capsulorrhexis occurs when the tear inadvertently extends peripherally into the zonules (see Figure 3), under the iris, and can no longer be visualized. Once this occurs, the surgeon must determine the reason for the extension. It is most often caused by positive posterior pressure pushing the lens nucleus anteriorly. This creates vector forces on the tearing capsular bag, causing it to tear outward. In order to correct the situation, the speculum must be loosened, drape pressure must be relieved, and the anterior chamber should be refilled with a viscoelastic (preferably a dispersive one). The objective is to substantially deepen the anterior chamber, which then pushes the lens nucleus posteriorly, flattening its anterior surface and thus diminishing the anterior pressure on the capsule.

Once all this has been done, the next step is to complete the tear. If the tear can be visualized, it can be completed by pulling the tearing capsule directly to the center of the pupil, redirecting the tear vector away from the periphery. This will maintain a continuous capsulotomy. If the tear cannot be visualized, it must be completed from the opposite direction. This can be facilitated by deepening the anterior chamber with viscoelastics (see Figure 4). When the capsulorrhexis is completed, it should be made large enough to allow prolapse of the lens nucleus. Because this has



**Figure 4.** Deepening the anterior chamber with viscoelastic allows the capsulorrhexis to be completed from the opposite side. Note the iris is now flat (inset surgeon's view), indicating that the anterior chamber is adequately filled with viscoelastic.

created a noncontinuous capsulorrhexis, the nucleus should be prolapsed into the anterior chamber and phacoemulsified there. Additional viscoelastic should be placed above the lens to protect the endothelium. No pressure should be exerted on the posterior capsule, as this might cause the capsulorrhexis tear to extend peripherally around the equator into the posterior nucleus. This type of extension can lead to vitreous loss or a dropped nucleus.

### Nucleus Rotation Problems

Modern phacoemulsification techniques require free rotation of the lens nucleus in order to reach all of the nuclear material. If the surgeon does not lyse equatorial nuclear-cortical bag connections, nuclear rotation will be impeded. This then will require the surgeon to apply excessive rotational effort, during which zonular or capsular tears may occur.

When the lens nucleus will not rotate, the surgeon should perform additional hydrodissection in four quadrants. Gentle retropulsion of the nucleus will help to force fluid trapped behind the posterior pole of the nucleus around the equator, causing nuclear cortical connections at the equator to lyse. If the lens nucleus still does not rotate freely, the surgeon can perform a two-handed rotational maneuver under viscoelastic. A lens manipulator is placed through the paracentesis and across the nucleus to the opposite side. The phacoemulsification tip is then placed in the eye and into position, engaging the nucleus opposite

the manipulator. In footpedal position 0, when there is no inflow, outflow, or phaco power, the vitreous will support the lens nucleus, and both instruments are gently rotated in unison.

### Anterior Chamber Shallowing

If, during the surgery, the surgeon finds it difficult to maintain the depth of the anterior chamber, the likelihood of a torn posterior capsule increases. It is difficult to perform phacoemulsification in the presence of a shallow anterior chamber, as forward movement of, or significant pressure on, the posterior capsule may result in capsular rupture. In this situation, the surgeon must determine the cause for the shallow anterior chamber. Causes for shallow anterior chamber include excessive fluid outflow or inadequate inflow, and positive posterior pressure.

**Excessive Fluid Outflow/Inadequate Inflow.** If excessive outflow is being caused by faulty wound construction in addition to excessive inflow due to the height of the infusion bottle, the bottle should be lowered and the wound sutured appropriately. If fluid inflow is inadequate, the incision should be enlarged or the infusion bottle raised. This situation may also be caused by an obstructed phaco tip sleeve. Sometimes the use of a dispersive rather than a cohesive viscoelastic may help to minimize these causes of chamber shallowing.

**Posterior Positive Pressure.** If fluid inflow and outflow are appropriate, but the anterior chamber remains shallow, a posterior positive pressure cause should be suspected. Posterior pressure is caused by external physical forces such as a tight speculum or drapes, a retrobulbar hemorrhage, or internal physical forces such as fluid misdirection syndrome, or suprachoroidal effusion or hemorrhage.

If the surgeon eliminates physical forces and retrobulbar hemorrhage as causes, and the chamber remains shallow, either fluid misdirection or a suprachoroidal effusion is developing. The surgeon can confirm this by placing a finger on the patient's eye and sensing a firm globe with elevated pressure.

Fluid misdirection syndrome occurs when irrigating fluid passes through intact zonules or a zonular tear into the vitreous. This causes vitreous hydration, expansion of vitreous volume, and subsequent elevated posterior segment pressure. Fluid misdirection will usually respond to the treatment described below and allow the surgeon to cautiously proceed.

The treatment would include (1) lowering the infusion bottle to decrease fluid inflow, (2) giving acetazolamide (Diamox) (500 mg IV push) and/or mannitol

(Osmitrol) (1–2 g/kg 0.25% solution) intravenously, and (3) waiting approximately 20 minutes for both drugs to take effect, for the eye to stabilize and soften, and for the chamber to deepen.

If after this treatment the globe remains firm and the chamber shallow, a suprachoroidal effusion should be suspected. An indirect ophthalmoscopic evaluation or the use of an Osher Emergency Lens to view the posterior segment may reveal an elevated choroidal mass.

Suprachoroidal effusion is caused by rupture of the short posterior ciliary vessels, with subsequent outpouring of plasma and blood into the suprachoroidal space. The amount of extravasated material is limited by the increased intraocular pressure created by this process, which effectively tamponades continued hemorrhage. If the wound is opened, the resultant hypotony allows continued hemorrhage and eventual expulsion of intraocular contents. Suprachoroidal effusion will often be unresponsive to the treatment just described, with persistent high intraocular pressure and the resultant markedly shallow anterior chamber. In this situation it is best to interrupt the surgery, and return within the next 1–2 weeks to complete the surgical procedure. *Under no circumstance should the surgeon attempt to convert the procedure to ECCE, as enlargement of the wound will destabilize the eye and allow a suprachoroidal effusion to become hemorrhagic, with subsequent expulsive hemorrhage.*

## Torn Posterior Capsule

During phacoemulsification, a number of factors may lead to tears in the posterior capsule. For example, the phaco tip may capture and tear the posterior capsule. In addition, turning 30° and 45° phaco tips bevel down so that aspiration can be applied at the same time as phacoemulsification power can aspirate and tear the posterior capsule. If hydrodelineation (the separation of endonucleus from the epinucleus) is inadequate, the resultant nuclear fragments adhere to the lens cortex. This forces the surgeon to perform phacoemulsification further toward the equator, beyond the hydrodelineation line, which may lead to equatorial tears. Similarly, inadequate hydrodissection resulting in cortex adhering to the posterior capsule may cause capsular tears during irrigation and aspiration. Finally, it is possible, although debatable, that the sharp edges of a hard nucleus may tear the posterior capsule.

These problems can be avoided with the use of several strategies. These are (1) performing an adequate hydrodissection and hydrodelineation; (2) mobilizing

**Table 2. Four Cardinal Signs of a Torn Posterior Capsule**

1. Sudden deepening of the anterior chamber
2. Momentary pupillary dilatation
3. Nucleus falls away from and will not come toward the phaco tip
4. Vitreous aspiration into phaco tip

the nucleus; (3) selecting 0° and 15° phaco tips; (4) using machines with surge protection software to prevent trampolening and capture of the posterior capsule; and (5) either using bimanual irrigation and aspiration or performing irrigation and aspiration after the IOL insertion so that the lens holds the posterior capsule back, making it easier to remove difficult cortex adhesions.

## Recognition

The surgeon can recognize a torn posterior capsule by being alert for the four cardinal signs, as listed in Table 2. The first sign is sudden deepening of the anterior chamber, occurring instantaneously as a tear appears in the capsule. It happens because the hammocklike posterior capsular support is lost, causing the nucleus to begin to fall back. The second sign is that as the chamber deepens, the pupil will momentarily dilate. The third sign occurs during phacoemulsification, when the nucleus falls away from, and will not come toward, the phaco tip because the flow dynamics in the anterior chamber have been altered by the tear in the posterior capsule. The fourth sign is that sometimes vitreous will be preferentially aspirated to the phaco tip, literally pushing the nucleus away.

## Management

The posterior capsule can tear during hydrodissection, rotation, cracking, removal of the last nuclear fragments, irrigation and aspiration, capsular polishing, lens insertion, or viscoelastic removal. The management of the torn posterior capsule depends on the point in the procedure at which the tear occurs and the amount and density of the remaining lens nucleus.

Whenever the surgeon recognizes a tear in the posterior capsule, successful management requires that two questions be answered: First, is there vitreous present in the anterior chamber? Second, is conversion to a standard ECCE procedure indicated?

If no vitreous is present in the anterior chamber, dispersive viscoelastic may be used deep to the nucle-

us to isolate the vitreous face and stabilize the nucleus. Viscoelastic can also be used above the nucleus to protect the endothelium. Phacoemulsification can then usually be continued, following the principles enumerated for capsular tears during capsulorrhexis.

Although in most cases phacoemulsification can continue after a posterior capsular tear, when in doubt, it is prudent to convert to an ECCE rather than proceed with phacoemulsification. The consequences of an inappropriate decision could be the loss of some or all of the nucleus into the vitreous.

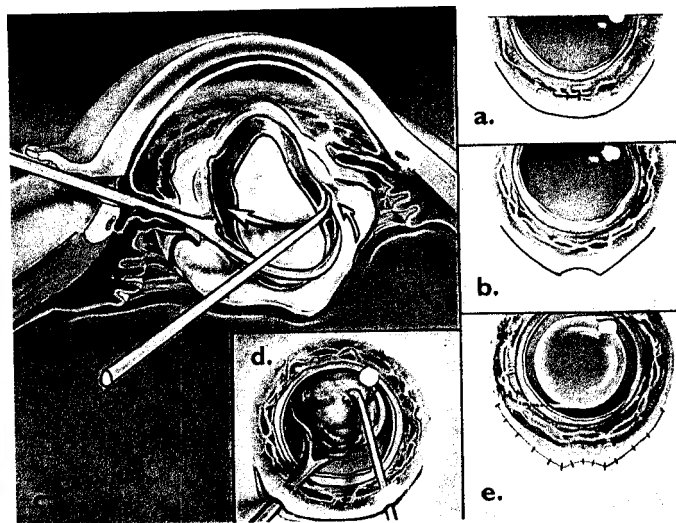
The decision to convert a procedure to ECCE may depend on multiple factors, including the hardness and size of the nuclear material in the anterior segment, the size of the pupil, the ability to maintain an adequately deep anterior chamber, ease of access to the anterior segment, and the perceived severity of the posterior capsular tear. The decision should also be based upon the surgeon's level of experience.

A key factor in this decision would be the presence of vitreous in the anterior chamber combined with a large piece of nucleus. If vitreous is present immediately after a capsular tear, this generally indicates a large capsular tear combined with synergetic poor vitreous support. The potential gravity of this situation would favor conversion to ECCE.

While considering the situation, the surgeon should be careful not to depressurize the anterior chamber by abruptly removing the phaco tip. The resultant sudden loss of anterior chamber fluid and pressure will allow the positive vitreous pressure to push the posterior capsule forward. The tear will enlarge, frequently the vitreous face will rupture, and vitreous will pass into the anterior chamber. To prevent this, the surgeon should pressurize the anterior chamber with viscoelastic before removing the phaco tip.

**Conversion to ECCE.** A general method of converting the phacoemulsification procedure to ECCE is outlined in Figure 5. An important preparatory step is to immediately secure the lens nucleus with a dispersive viscoelastic to prevent the loss of nuclear fragments into the vitreous. To do this, viscoelastic is injected underneath the nucleus to support it. Creating a paracentesis opposite the incision may be necessary to allow passage of a hook into the superior anterior chamber. This hook can be used to loosen and manipulate nuclear material embedded within the superior capsular bag into the anterior chamber, where it can be secured for later extracapsular extraction.

If a clear corneal incision is used, it may be sutured and abandoned (see Figure 5a). If a sclerocorneal (frown) incision has been used, it can be extended as



**Figure 5.** Converting phacoemulsification to ECCE. 5a: Clear corneal incision is sutured and extracapsular incision is created. 5b: Frown incision is extended. 5c: Side view of extraction of nuclear pieces with lens loop and second instrument, extruding nucleus through incision. 5d: Surgeon's view of procedure in 5c. 5e: Method of suturing.

demonstrated in Figure 5b. A well-constructed shelved limbal incision is created after appropriate conjunctival peritomy and cautery. The size of this incision depends on the size of the nuclear fragment in the anterior chamber. In general, the incision should be larger than the surgeon thinks is necessary for extraction of the nuclear remnant. Once the incision has been created, the wound is opened fully and then a lens loop and secondary lens manipulator are used to extrude the lens nucleus (see Figure 5c, side view, and Figure 5d, surgeon's view). Do not apply external pressure to the opposite limbus, as vitreous will be preferentially expelled.

Alternatively, the clear corneal incision can be enlarged for extracapsular extrusion of nuclear material and implantation of a PMMA or foldable IOL. The choice of lens implant depends on the amount of residual anterior capsule. Once the lens nucleus has been removed, anterior segment surgery should proceed as described below. The enlarged clear corneal or limbal incision is first sutured with interrupted or running 10-0 nylon radial sutures that are trimmed on the knot and buried (see Figure 5e).


**Continuing Phacoemulsification.** If the surgeon thinks that continued phacoemulsification is appropriate, a dispersive viscoelastic should be placed below the lens nucleus to raise and secure it in the anterior chamber. Infusion bottle height, vacuum, and flow should be lowered to create a low-flow system, e.g., if using high flow and vacuum the bottle is lowered from 65 mm to

55 mm, flow decreased to 18 cc/min and vacuum to 100 mm Hg. The nucleus is then emulsified in the anterior chamber in one piece using two instruments. The second instrument is used to feed the edges of the nucleus into the phaco tip, applying power in foot-pedal position 3 only when nucleus is adjacent to the phaco tip so as not to emulsify vitreous, which might be aspirated preferentially (see Figure 6 inset). It is best not to create multiple fragments of nucleus by cracking or other maneuvers, as these fragments are difficult to follow and may fall through the posterior chamber tear into the posterior segment.

If the tear seems too large to support continued phacoemulsification but small-incision surgery is desired, the surgeon can create a pseudoposterior capsule using a Sheets glide (see Figure 6). The Sheets glide must first be cut down to the appropriate size in relationship to the incision size. It is then placed through the incision into an anterior chamber well-filled with viscoelastic. The glide is manipulated behind the nuclear fragment (a second instrument may be helpful) and, if possible, into the opposite ciliary sulcus. The surgeon then performs phacoemulsification over the Sheets glide. The incision may need to be enlarged slightly to make room for both the phaco tip and the Sheets glide. The glide can be left in place during phacoemulsification of the remaining nucleus, as well as during irrigation and aspiration of any residual cortex.

If the capsular tear occurs when only a small fragment of nucleus remains, the fragment can be emulsified by moving it near the phaco tip and then applying aspiration and phacoemulsification power. This will immediately engage the nuclear fragment in the phaco tip, thus preventing the aspiration of vitreous.

**Irrigation and Aspiration of Cortex.** To remove cortex in the presence of a capsular tear, the remaining cortex should be stripped toward the tear. The 0.3 mm irrigation and aspiration tip should be embedded into the cortex before vacuum is applied so as not to aspirate vitreous. Lowering the infusion bottle will decrease fluid inflow and the resultant turbulence, which might enlarge the capsular tear or force more vitreous forward. The surgeon should try to avoid working directly over the capsular tear and never strip cortex directly away from the tear, as this will immediately enlarge it. If necessary, the surgeon can remove cortex manually. If cortex is difficult to remove and not too voluminous, it should be left behind.



**Figure 6.** Sheets glide in position to form pseudoposterior capsule. Note how it supports the nucleus for continued phacoemulsification. The inset shows how the nucleus, secured from falling into the vitreous by viscoelastic, is then pushed until it is in contact with the phaco tip. Aspiration and phacoemulsification power may now be applied.

## Management of Selected Complications

### Vitrectomy for Vitreous in Anterior Chamber

If vitreous is present in the anterior chamber immediately after the capsular tear, it should not be removed until after the nucleus or nuclear fragments are emulsified, as it might provide support to keep the nucleus from falling posteriorly. Once phacoemulsification is completed, the surgeon should perform a bimanual vitrectomy. This is accomplished by establishing irrigation through a 23-gauge cannula placed through the paracentesis. The infusion bottle is positioned at the appropriate height to maintain the anterior chamber during vitrectomy. A guillotine-type vitrector (with the irrigating sleeve removed) is then placed through the incision and through the posterior capsular tear to draw vitreous back through the tear into the posterior segment. The surgeon then performs the vitrectomy using a high cutting rate, i.e., 400 or 450 cuts per minute, and a flow of 200 cc/min with a vacuum of 100 mm Hg. The vitrectomy is continued until no vitreous is present anterior to the plane of the posterior capsule. Bimanual vitrectomy is preferred because it may prevent the capsular tear from enlarging (see Figure 7, cover).

If the capsular tear is small and only a small amount of vitreous is present, the surgeon can perform a dry vitrectomy. In this case, the anterior chamber is filled with a dispersive viscoelastic. Then the guillotine-type vitrector (with no irrigation sleeve) is placed through

the tear into the posterior capsule and into the vitreous. A small vitrectomy is performed using the parameters noted above. No irrigation is necessary, but the viscoelastic volume may be augmented as needed.

In certain situations, the nucleus cannot be stabilized. This is most likely to occur when the phaco tip creates a large zonular dehiscence opposite the incision. In such a circumstance zonules are present subincisionally, so that the distal pole of the nucleus falls into the vitreous but the nucleus remains attached subincisionally, preventing the entire nucleus from disappearing. In this unique setting, the surgeon should make a stab incision into the pars plana 3.5 mm posterior to the incisional limbus. Alternatively, the pars plana incision can be moved to wherever the zonular hinge occurs. As described by Charles Kelman, M.D., a cyclodialysis spatula is then used to lever the nucleus into the anterior chamber through the pars plana approach. Once the nucleus is secured within the anterior chamber, it can be removed either by phacoemulsification or preferentially by extruding it through an extracapsular incision (see Figure 8).

In all cases, if the posterior capsular tear is entirely within view, the surgeon can attempt a posterior capsulorrhexis. If the vitreous face is intact, this is done by placing viscoelastic above and below the tear and pushing the vitreous face back, allowing room to grasp the torn capsule. If the vitreous face is already broken, viscoelastic is necessary only to stabilize the anterior chamber and make room for the forceps. Using a capsulorrhexis forceps, the surgeon gently tears the capsule to create a 360° posterior capsulorrhexis. As the posterior capsule is more fragile than the anterior capsule, frequent regrasping of the tearing capsular flap is necessary to provide adequate control of the direction of the tear. A Masket modified Utrata Forceps is particularly useful for this procedure, as the curved blades allow easier access to the anatomically posterior capsular flap. The surgeon may encounter difficulty with visibility of the tearing capsule, and with forceps manipulation deep in the anterior chamber. Failed attempts may result in extension of the tear and, if not already present, vitreous loss.

### Lost Nucleus or Nuclear Fragments

When the posterior capsule is torn during phacoemulsification, small pieces of nucleus or cortex may fall into the vitreous. If the pieces are soft and more cortical in nature, they will usually resorb with little sequelae. If the piece of material is large (including the entire nucleus) or hard, the likelihood of vitritis with subsequent macular edema and/or secondary glaucoma is high. If vitritis or elevated IOP occurs, the frag-



**Figure 8.** Before vitrectomy, a cyclodialysis spatula is used to lever a hinged nucleus into the anterior chamber (Kelman technique).

ments should be retrieved within 2 weeks of the original surgery. To remove intravitreal nuclear fragments, a pars plana approach, vitrectomy, and fragmatome removal of the nucleus is recommended. Therefore, the lens implant can usually be placed into the ciliary sulcus at the time of the primary surgery.

### Zonular Dialysis

Zonular dialysis greatly increases the risk of both vitreous loss and nuclear fragments dislocating into the vitreous. Obviously, IOL implantation may be more difficult. The surgeon needs to evaluate the number of clock hours involved with the zonular dialysis and consider his or her experience performing phacoemulsification in this setting. The intracapsular ring and new viscoelastic techniques have increased the successful outcome of phacoemulsification in these challenging situations.

Intracapsular PMMA capsular-tension (Morcher) rings are placed within the capsular bag before phacoemulsification, using an injection instrument. They apply uniform pressure throughout the bag equator, discouraging its collapse during phacoemulsification and irrigation and aspiration. They also support the bag internally, decreasing the risk of spreading zonular loss. See Suggested Viewing for more detailed information.

### Postoperative Care

In the case of complications, the surgeon should consider adding subconjunctival triamcinolone (Kenalog)

**Table 3. Complications After Cataract Surgery: Various Surgeons' Experience**

	Osher-Cionni*	Fishkind**	Powe et. al.†
Vitrectomy %	1.00%	1.25%	0.80%
Vision $\geq$ 20/40	89.00%	80.00%	90.00%
<b>Early Complications</b>			
Endophthalmitis	0.00%	0.00%	0.13%
Hyphema	0.00%	0.00%	0.20%
Vitreous in AC	10.40%	5.00%	Not reported
Elevated IOP	0.00%	0.00%	0.20%
<b>Late Complications</b>			
Cystoid macular edema	2.00%	0.27%	1.50%
Retinal detachment	0.00%	0.10%	0.70%

\* Out of 4800 cataract extractions.

\*\* Out of 1834 cataract extractions by phacoemulsification.

† Out of 68,316 cataract extractions by phacoemulsification, extracapsular extraction, or intracapsular extraction.

20 mg to the usual topical medications. Prednisolone sodium acetate (Pred Forte) 1% and diclofenac sodium (Voltaren) may be given in a q.i.d. or more frequent dosage. A subconjunctival triamcinalone injection may be repeated at 3 weeks after surgery if cystoid macular edema (CME) is diagnosed, and more frequent office visits are often required.

### Brief Clinical Review

Posterior capsular tears worsen the prognosis for successful visual outcome of cataract surgery. When the posterior capsule is violated but vitreous is not lost and a posterior chamber IOL is implanted in the capsular bag or ciliary sulcus, there is increased risk of CME, vitreous prolapse into the anterior chamber, and retinal detachment. Intraoperative peripheral iridectomy may be necessary, increasing the risk of hyphema.

Vitreous loss appears to be the crucial factor influencing clinical outcome. Once vitreous is lost, the postoperative course is complicated in 30% of patients, with an increased number of visits due to hyphema, retained cortex, corneal edema, blurred vision, and vitreous strands. Long-term retinal problems include chronic CME, macular holes, and retinal detachment. These complications are shown in Table 3, which compares postoperative outcomes for three representative surgeons.

### Conclusion

Recognition and appropriate adjustment of the surgical plan in the presence of predisposing factors for a torn posterior capsule should help to decrease the incidence of this problem. Likewise, prompt recognition and treatment of torn capsules and vitreous loss should help to minimize serious complications and improve surgical outcomes. Methodical analysis of complications and appropriate treatment with nuclear and cortical fragment removal, preservation of as much posterior capsule as possible, careful vitrectomy, appropriate IOL selection and insertion, and postoperative modification of various medications will further improve the postoperative course.

**William J. Fishkind, M.D., F.A.C.S.,** is Clinical Professor of Ophthalmology, University of Utah, Salt Lake City, UT; and director of Fishkind and Bakewell Eye Care and Surgery Center, Tucson, AZ. Dr. Fishkind is a paid consultant to Allergan and Mentor.

*The Clinician's Corner section is intended to provide additional viewpoints on the subject covered in this issue of Focal Points. Consultants have been invited by the Editorial Review Board to respond to questions posed by the Academy's Practicing Ophthalmologists Advisory Committee for Education. While the advisory committee reviews the modules, consultants respond without reading the module or one another's responses.—Ed.*

**1. In what clinical circumstances would a pars plana vitrectomy be indicated over a limbal anterior vitrectomy?**

**Dr. Crandall:** Unless the surgeon is well-trained and comfortable with a pars plana approach in cataract surgery, there are probably few indications to use this approach. I will use it if I have had to do a Kelman's posterior assisted levitation of the lens. I also do it in pediatric cases to remove the central posterior capsule. The classic indication would be to remove fallen lens fragments. However, I would not ordinarily suggest anterior segment surgeons attempt this, as most are not comfortable with the three-part vitrectomy required to remove fallen lens fragments.

**Dr. Davison:** Vitreous is a normal resident of the posterior segment, while the lens is a normal resident of the anterior segment. When vitreous is found in the anterior segment, an anterior vitrectomy is the procedure of choice. When the lens or relatively large lens fragments are found in the posterior segment, then a pars plana vitrectomy is the procedure of choice.

I have had to employ emergency pars plana incisions without pars plana vitrectomy during cataract surgery several times. In these cases the zonular apparatus was so weak that the lens started to fall posteriorly during phacoemulsification. To do this, I passed a massive vitreous retraction (MVR) blade through the pars plana 3.5 mm from the limbus to pry the sinking lens forward; with that successfully accomplished, I still finished with an anterior limbal vitrectomy. If a posterior vitrectomy was performed, vitreous strands need to be trimmed from the pars plana incisions with Westcott scissors and the scleral and conjunctival incisions closed with 8-0 Vicryl.

**2. When a posterior capsule ruptures without vitreous prolapse, what technique do you employ to remove the remaining nuclear fragments?**

**Dr. Crandall:** The first goal is to stabilize the situation. I usually use a dispersive viscoelastic to tamponade and hold the vitreous face back. If the remaining nuclear piece(s) are small enough, they can be brought up and removed manually with visco-elastic and then forceps. The rupture can be stabilized and kept from expanding by doing a continuous tear capsulotomy.

If the piece of nucleus is large then it is brought up and the wound is enlarged by 0.5 mm to accommodate a Sheets phaco glide, which is placed under the nuclear remnant. The phacoemulsification unit is reintroduced with all parameters changed. The infusion bottle is lowered and the aspiration flow rate is reduced to 14, the vacuum to around 100 (normal 400 mm Hg Alcon Legacy). The nuclear pieces are then slowly phacoemulsified.

**Dr. Davison:** Very small fragments may be left in the anterior vitreous. Larger ones may be removed with anterior vitrectomy. If larger nuclear fragments have been forced posteriorly through the most anterior vitreous, a pars plana vitrectomy will be required. If the fragments are small or soft they may nibbled by the vitrector or forced bimanually into the vitrector opening. If the fragments are large or hard a fragmatome may be employed in the vitreous cavity center after vitreous removal. If this is unavailable, the fragments may be maneuvered into the anterior segment and removed by the Viscoat sandwich technique with a normal phacoemulsification tip.

Viscoat serves to isolate nuclear fragments in a kind of plastic gel. Phacoemulsification can then be used to remove the fragments. Viscoat may have to be reinjected several times in order to preserve appropriate anatomic relationships. It is important to have a relatively normal anterior chamber pressure and not over or underfill the anterior chamber.

If vitreous is encountered, instrumentation should be immediately changed to vitrectomy, strands cut, then Viscoat reinstilled to push remaining sheets

## Clinician's Corner



and strands back so that phacoemulsification can continue.

Make sure to establish aspiration flow and infusion inflows before applying phacoemulsification power. Circulating balanced salt solution (BSS) cools the incision surfaces—it is very easy to burn these surfaces instantaneously without adequate cooling. I have found it helpful to irrigate and aspirate a central core of the Viscoat material prior to phacoemulsification. A stirring motion with a cyclodialysis spatula near the phacoemulsification tip will facilitate creation of a central BSS space. Adequate vacuum and aspiration flow rate machine parameters must exist to aspirate Viscoat.

**3. When a defect is present in the posterior capsule, should a silicone lens be placed in the sulcus if there is adequate support, or should the surgeon use PMMA or acrylic lenses?**

**Dr. Crandall:** Silicone lenses have performed well over the years, but there are situations in which I would elect to use another material. For instance, I would choose alternate materials if the patient is diabetic or has a condition (i.e., myopic degenerative retinal problems) that may require the potential use of silicone oil, and for patients with uveitis and possibly those with glaucoma. Also the surgeon should definitely use a silicone lens with PMMA haptics and not polypropylene when the lens will sit in the sulcus.

Usually I use a 6.00-mm acrylic lens for sulcus fixation. The lenses are large enough and “quiet,” i.e., they generally do not induce inflammation. The new heparin-coated PMMA lenses would be an excellent alternative.

**Dr. Davison:** Because patients with posterior capsular defects may be at higher risk for detached retinas, they are at higher risk for pars plana vitrectomy and gas–fluid exchange. Because the posterior optic surfaces of silicone lenses tend to fog, they should not be used if pars plana vitrectomy is anticipated.

That consideration aside, a 1-mm, punched-out, circular posterior capsular defect could accommodate the placement of any style of posterior chamber IOL within the capsular bag. A larger 2-mm defect could accommodate an acrylic, PMMA, or three-piece silicone IOL within the capsular bag. If the posterior defect is larger but is still accompa-

nied by an intact anterior capsulorrhexis, any IOL except plate haptic silicone may be placed with its optic posterior to and captured by the capsulorrhexis with the haptics placed within the sulcus. The surgeon will need to subtract 0.5 diopters from the power of the selected IOL because it has been moved forward. If the posterior and anterior capsules are both torn and the eye is relatively short, a PMMA, larger acrylic, or three-piece silicone lens can be placed in similar style with the haptics in the sulcus. If the eye is larger, any of these three styles could be used, but a McCannal-type suture, or preferably two, will be needed.

**4. In what circumstances would you select an anterior chamber lens, a sulcus-fixed lens, and a sutured posterior chamber lens?**

**Dr. Crandall:** My preference would be a sulcus-fixed lens, which depends solely on enough capsular support. If this is not available, my next choice is an anterior chamber lens. The modern four-point flexible anterior chamber lenses have performed well. However, these cannot be used in certain situations, such as in eyes without irides (from trauma or aniridia), small eyes, and eyes with peripheral anterior synechia (no available angle structures). In these cases an IOL is sutured into the posterior capsule. In general, however, the extra manipulation this requires is not necessary.

**Dr. Davison:** If there were so little central capsule left that virtually no stabilization would be provided for an IOL optic or at least its midperipheral haptics, or if a segment of peripheral capsule and the accompanying zonular fibers were missing, I would place an anterior chamber lens. If there were enough capsule left, I would employ the method outlined in my answer to question 3. I would use sulcus suture fixation only if capsular support was virtually nonexistent and if angle anomaly was significant enough that an anterior chamber lens could not be placed.

**5. Following vitrectomy and lens placement, what is the preferred technique for removing viscoelastic in the presence of a torn posterior capsule?**

**Dr. Crandall:** Assuming that the lens is stable, sutures have been placed, and the iris has been constricted with a miotic, the goal is to remove the viscoelastic without bringing more vitreous forward

or displacing the lens. To reduce turbulence, the viscoelastic can be removed manually by exchanging it with BSS. This is labor intensive, especially with dispersing viscoelastics. If the surgeon has used an anterior limbal vitrectomy probe, then it can be used again to remove the viscoelastic. I am usually not too aggressive in this situation; if the patient can tolerate it I will use a beta blocker and oral acetazolamide (Diamox) to keep the intraocular pressure from increasing too quickly.

**Dr. Davison:** The surest way to remove viscoelastic in this situation is to serially exchange it with BSS using two 3-cc syringes. One should be tipped with a 22- or 25-gauge cannula and the other with a 30-gauge cannula. The larger can be used to remove viscoelastic and the smaller to replace the removed volume with BSS. Make sure to keep the anterior chamber relatively pressurized and full. Viscoat is more difficult to adequately remove, but it is associated with fewer high-pressure rises. Healon in its various preparations is easier to remove but more prone to pressure elevation if significant amounts are left in place.

#### 6. What are your recommendations for observing or removing a retained lens fragment?

**Dr. Crandall:** Retained lens material may be found in a number of situations, but certainly even when surgery proceeded with no intraoperative complications. In this case, from 1-7 days after surgery, a small piece of nuclear material that was missed (hidden in the sulcus or angle) will become visible. If it is small enough and the eye is "quiet," i.e., not irritated, the surgeon can observe and allow the eye to slowly remove it, as long as the eye does not become inflamed and the cornea tolerates it.

The most common situation, however, is in a complicated case where retained lens material falls posteriorly. If the material is cortical, it will swell and appear to enlarge. If the eye remains "quiet," this material will resolve over weeks. If the material is nuclear and large, it will usually lead to inflammation, and possibly chronic cystoid macular edema (CME). In this situation I believe referral to a retina/vitreous specialist is indicated for removal.

**Dr. Davison:** Anterior chamber lens fragments larger than 0.3 mm in diameter should generally be removed, because they damage corneal endothelium. If they find their way posterior and become

trapped within the zonular apparatus, they can be observed.

Vitreous cavity lens fragments 1.0 mm in diameter or smaller can be observed and treated medically for increased inflammation and intraocular pressure (IOP) if they occur. Seeing the fragment may trouble patients but it will usually be absorbed over time. Harder fragments will take longer to resolve than soft. Vitreous cavity fragments larger than 1.0 mm should probably be removed with pars plana vitrectomy.

#### 7. What, if any, intracameral or subconjunctival medications do you employ? Do you alter this routine in the event of capsular rupture with vitreous loss?

**Dr. Crandall:** In general the only intracameral medications I use are 1% unpreserved lidocaine (Xylocaine) for anesthesia and acetylcholine (Miochol-E) or carbachol (Miostat) for cases in which the pupil needs to be constricted, such as in combined procedures or capsular rupture. I do not use a miotic in routine cases.

I do not use either subconjunctival antibiotics or steroids. I will use a collagen shield soaked in dexamethasone phosphate (Decadron) and cefazolin (Ancef). If I suspect endophthalmitis, then I will use dexamethasone and vancomycin with ceftazidime after vitreous biopsy, but there is no evidence that using antibiotics in the line or in the anterior chamber at the end of the procedure reduces the chance of endophthalmitis.

**Dr. Davison:** In 500-cc BSS infusion volume I use vancomycin 30 mg, and preservative-free epinephrine (Epifrin) 1 cc of 1/10,000. I use no subconjunctival medications. I would not alter these medications for capsular rupture. However, if surgery was difficult, I might give more topical steroids for a longer period than my usual prednisolone acetate (Pred Forte) 1% q.i.d. for 2 weeks then b.i.d. for 2 weeks.

---

**Alan S. Crandall, M.D.,** is Professor of Ophthalmology, Clinical Track, University of Utah, Salt Lake City, Moran Eye Center.

**James A. Davison, M.D., F.A.C.S.,** is a practicing ophthalmologist at the Wolfe Clinic, Marshalltown, IA.

## SUGGESTED READING

1. Buratto L. *Phacoemulsification, Principles and Techniques*. Thorofare, NJ: Slack;1998.
2. Cimetta D, Guallapalli R. *Video J Cataract Refract Surg*. 1996;12:Issue 1.
3. Fishkind WJ. Unexpected vitrectomy as a complication of cataract surgery. *J Cataract Refract Surg*. Best Papers of Session 1994; 54-57.
4. Gills JP, ed. *Cataract Surgery, The State of the Art*. Thorofare, NJ: Slack;1998.
5. Hoffer KJ, McFarland JE. Intracameral subcapsular fluorescein staining for improved visualization during capsulorhexis in mature cataracts (letter). *J Cataract Refract Surg*. 1993;19:566.
6. Horiguchi M, Miyake K, Ohta I, et al. Staining of the lens capsule for circular continuous capsulorhexis in eyes with white cataract. *Arch Ophthalmol* 1998; 116(4): 535-537.
7. Lu LW, Fine IH, ed. *Phacoemulsification in Difficult and Challenging Cases*. New York: Thieme;1999.
8. Osher R, Cionni R. The torn posterior capsule; its intraoperative behavior, surgical management, and long-term consequences. *J Cataract Refract Surg*. 1990;16:490-494.
9. Powe NR, Schein OD, et al. Synthesis of the literature on visual acuity and complications following cataract extraction with intraocular lens implantation. *Arch Ophthalmol*. 1994;112:239-252.
10. Steinert R, ed. *Cataract Surgery, Technique, Complications, & Management*: Philadelphia: WB Saunders Co; 1995.

## SUGGESTED VIEWING

1. Nichamin L. Zonular Dialysis. In: Video Journal of Cataract and Refractive Surgery, Complications Symposium. Vol. XIII; Issue 3:1997.
2. Osher R. ed., Video Journal of Ophthalmology. Vol. XII; Issue 1, 2:1996. Vol. XIII: Issue 1, 3:1997.

### Related Academy Materials

*Cataract in the Adult Eye*. Preferred Practice Pattern, 1996.

Lane SS, Crandall AS, Koch DD, Steinert RF. *LEO Clinical Update Course on Cataract*. LEO Clinical Update Course, CD-ROM, 1999.

Lane SS, Skuta GL, eds. *ProVision: Preferred Responses in Ophthalmology*, Series 3. 1999.

*Lens and Cataract*. Basic and Clinical Science Course, Section 11, 1998-1999.

Osher RH. *Complications During Phacoemulsification*. Videotape. 1999.

Skuta GL, ed. *ProVision: Preferred Responses in Ophthalmology*, Series 2. 1996.

Tipperman R, Lichtenstein SB. *Cataract*. LEO Clinical Topic Update, 1996.