

# INSTRUCTIVE CASES

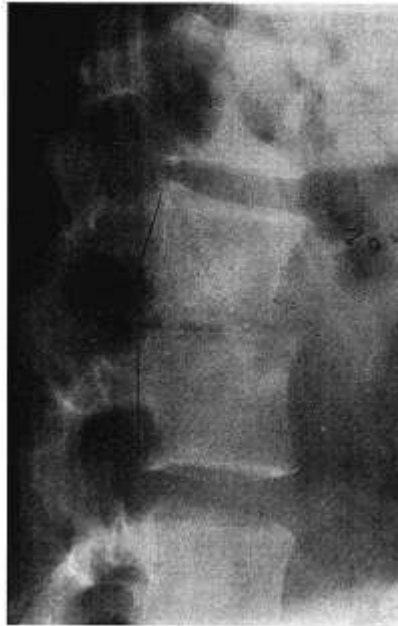## Miliary Tuberculosis and the Postpartum State

George F. Risi  
John D. Kriesel  
Marion L. Woods

In 1985, a resurgence of tuberculosis began in the United States. In conjunction with this resurgence, there has been an increase in the number of atypical presentations of the disease. We recently treated a patient who had disseminated tuberculosis that became manifest in the postpartum state. Whereas postpartum progression of tuberculosis was a well-recognized clinical entity in the preantibiotic era, few reports have dealt with the issue recently. We present this case as a timely reminder of the many faces of tuberculosis.

**Case Report.** A 19-year-old pregnant Hispanic woman entered the United States illegally immediately before the onset of labor. When she was evaluated in a hospital in Texas, she gave a history of 4 weeks of fever and a nonproductive cough.

A chest radiograph was normal. After the delivery of a healthy 6-pound 4-ounce boy, her temperature rose to 104° F. The common causes of postpartum fever were sought and were excluded. Her fever was unresponsive to broad-spectrum empiric antibiotic therapy. Physical examination revealed a firm mass in the anterior cervical lymph node chain as well as pain over the lumbar spine. Radiographs of the spine showed narrowing of the L-2-L-3 disc space as well as anterior cortical destruction (Figure 1). The patient refused to undergo a diagnostic biopsy of either



**FIGURE 1.** Radiograph of lumbar spine showing narrowing of the L-2-L-3 disc space and anterior cortical destruction.

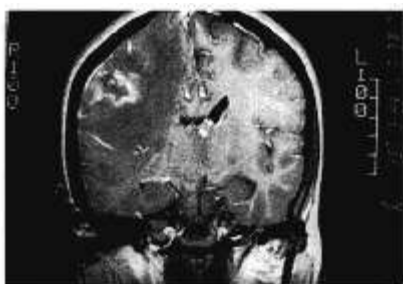the neck or back lesion. Records from the Texas hospital do not reflect tuberculin skin testing. Empiric therapy with isoniazid, rifampin, and pyrazinamide was instituted and was followed by rapid defervescence. However, after 1 week of therapy, the patient left the hospital against medical advice and did not continue therapy.

After a brief return to Mexico, she reentered the United States and settled in rural Nevada. Within a few weeks of arrival, she again began to experience fever and chills as well as a new symptom, right-sided headaches. Because of her status as an illegal alien, she was reluctant to seek medical attention. Headaches persisted, and a paresis of the left face, arm, and leg developed. After finally contacting a local hospital, she was transferred to the University of Utah Health Sciences Center for further evaluation and treatment.

At the time of admission, the patient was cachectic and lethargic and had complete paralysis of the left side. A chest radiograph showed infiltrates in a miliary pattern. A magnetic resonance imaging scan of the brain revealed an abscess in the right parietal lobe (Figure 2). A computed tomographic scan of the spine showed destructive changes in the L-2-L-3 area as well as bilateral paraspinal abscesses (Figure 3).

Tests for human immunodeficiency virus were negative. The patient underwent bronchoscopy with transbronchial biopsy that revealed noncaseating granulomas but no organisms on acid-fast stain. Aspiration of the paraspinal abscesses revealed acid-fast bacilli. Cultures from both specimens subsequently grew *Mycobacterium tuberculosis*, which was susceptible to isoniazid, rifampin, ethambutol, and pyrazinamide.

After therapy was begun with dexamethasone, isoniazid, rifampin, and pyrazinamide, the patient's fever decreased rapidly, and she regained neurologic function. She was discharged from the hospital with all three tuberculosis medications prescribed, but she stopped taking them shortly after discharge. Five weeks later she again presented with fever and left-sided weakness. Therapy was reinstated with dexamethasone and the same triple antimicrobial regimen, again with a rapid response. Upon her second discharge, directly observed therapy (DOT) was arranged with the Nevada State Health Department, and the patient continued to improve as an outpatient. However, after 3 months she left the state and was lost to follow-up.

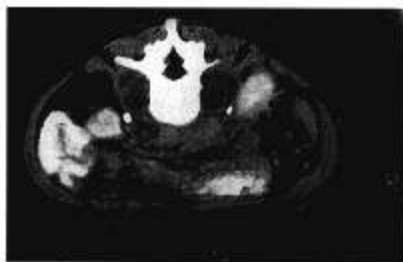


**FIGURE 2.** Magnetic resonance scan (coronal section) showing right parietal lobe brain abscess.

**Discussion.** Several issues are raised by this patient's presentation and subsequent medical management. The first is the delay in seeking medical attention because of her status as an illegal alien. The second is the effect of pregnancy or the postpartum state on the progression of tuberculosis. Third, there is the likelihood of development of drug-resistant organisms because of poor compliance with antituberculosis medications. The fourth issue is the ability of DOT to enhance markedly the likelihood of a successful outcome to therapy.

A discussion of the provision of medical care to illegal aliens is beyond the scope of this article. It is clear that the resources expended on this patient as the result of her profound illness at presentation were greater than would have been expended had she been diagnosed earlier.

This patient exhibited extrapulmonary tuberculosis at the time of



**FIGURE 3.** Computed tomographic scan showing bilateral paraspinous abscesses.

delivery and then clearly progressed during the postpartum state. The influence of pregnancy on the outcome of tuberculosis has been the subject of study and debate since antiquity. Opinions have ranged from believing that pregnancy exerted a beneficial effect to the idea that it exerted such a deleterious effect that abortion should be induced immediately to save the woman's life. Hedvall in 1953 [1] cited series in the preantibiotic era totaling more than 1000 cases purporting to show the adverse effect of pregnancy on women with tuberculosis, but he also found an equal number of reports that showed either no effect or a favorable effect. In Hedvall's own series of 250 pregnant women with tuberculosis who received sanatorium treatment only, 9% of the patients improved during pregnancy, 7% worsened, and 84% remained unchanged. However, he did find a higher risk of activation of disease during the first postpartum year with 8.8% improving and 15.2% worsening. Other investigators have found similar increased risk during the first postpartum year. Crombie [2] noted that of 101 pregnant women with inactive tuberculosis, 31 had relapses after delivery. Twenty of the women who had relapses were in their first postpartum year. In a study of 930 women with pulmonary tuberculosis, Gierke [3] found progression of disease in 90 cases within the first 6 weeks after delivery. Progression of tuberculosis in the postpartum state has also been ascribed to rapid hormonal changes, postpartum descent of the diaphragm, the nutritional strain of lactation, and insufficient sleep [4].

Lack of compliance with a multidrug regimen has been cited as the single most important reason

for emergence of resistant strains of *M. tuberculosis* [5,6]. Our patient responded on three separate occasions to isoniazid, rifampin, and pyrazinamide. The most plausible explanation for her response despite poor compliance is that she stopped all drugs simultaneously. There was thus no selective survival advantage to a spontaneously arising resistant organism.

Until the patient was lost to follow-up by leaving the state, DOT was highly efficacious in ensuring compliance. Weis et al. [7] recently demonstrated that commitment of the resources necessary for DOT can lead to markedly improved outcomes on a large scale. In their study, traditional unsupervised therapy for tuberculosis, which was given from 1980 to 1986, was compared with therapy given under direct observation from 1986 to 1992. Even though this latter period was associated with an increased rate of intravenous drug use, increased homelessness, and increased overall rates of tuberculosis, the frequency of primary drug resistance declined from 13% to 6.7%, the frequency of acquired resistance declined from 14% to 2%, and the relapse rate declined from 21% to 5%.

The patient described serves as a timely reminder that all physicians, despite their specialty or geographic location, must be alert to the resurgent problem of tuberculosis and its varied presentations.

1. Hedvall E. Pregnancy and tuberculosis. *Acta Med Scand.* 1953;147(286 Suppl):1S-101S.
2. Crombie JB. Pregnancy and pulmonary tuberculosis. *Br J Tuberc.* 1954;48:97-101.
3. Gierke HW. Tuberkuloseabläufe kurz nach schwangerschaftsbeendigung. *Z Tuberc.* 1956;108:1-8.
4. Snider D. Pregnancy and tuberculosis. *Chest.* 1984;86(Suppl):10S-13S.
5. Iseman MD. Treatment of multidrug-resistant tuberculosis. *N Engl J Med.* 1993;329:784-91.
6. Bellin E. Failure of tuberculosis control: a prescription for change. *JAMA.* 1994;271:708-9.
7. Weis SE, Slocum PC, Blais FX, et al. The effect of directly observed therapy on the rates of drug resistance and relapse in tuberculosis. *N Engl J Med.* 1994;330:1179-84.