

Chylorrhea: a rare complication of thoracoscopic discectomy of the thoracolumbar junction

Case report

AMIN AMINI, M.D., M.Sc., RONALD I. APFELBAUM, M.D., AND MEIC H. SCHMIDT, M.D.

Department of Neurosurgery, University of Utah, Salt Lake City, Utah

✓ The thoracic duct along with the cisterna chyli is a major lymphatic pathway near the anterior thoracolumbar spine. Despite the fragile nature of the lymphatic system and its proximity to the spinal column, chylorrhea is rarely encountered by spine surgeons. The authors present a unique case of chylorrhea associated with a left thoracoscopic, transdiaphragmatic discectomy and fusion for a T12–L1 herniated disc. The anomalous location of the thoracic duct at the left lateral vertebral column contributes to this unusual complication.

KEY WORDS • chylous leak • thoracoscopy • thoracic spine • thoracoscopic discectomy

MINIMALLY invasive thoracoscopic discectomy is gaining popularity over alternative open thoracotomy, costotransversectomy, and transpedicular approaches. Thoracoscopic discectomy provides several advantages over the other approaches, including less surgery-related pain, a lower incidence of morbidity, a shorter hospital stay, and a reduction in the number of complications. Nonetheless, with the increased number of surgeries performed using ventral spinal approaches including thoracoscopic spinal procedures, complications not previously encountered in posterior spinal surgery are now seen. Complications associated with thoracoscopic discectomy include intercostal neuralgia, retained disc fragments, inadvertent durotomies, and emergency conversion to open thoracotomy for vascular injuries. We present an unusual case of chylorrhea associated with a left-sided thoracoscopic approach to the thoracolumbar junction for a herniated disc.

Case Report

Presentation and Examination. This 51-year-old woman presented to our institution with an 8-year history of progressive severe back pain and bilateral leg pain that was unresponsive to conservative management. Magnetic resonance imaging of the thoracolumbar spine revealed a large

herniated nucleus pulposus at the T12–L1 level that was compressing the spinal cord (Fig. 1). On examination the patient was wheelchair-bound due to severe pain, and she exhibited bilateral lower-extremity myelopathy with pain-limited weakness.

Operation. After extensive counseling, the patient agreed to undergo a left-sided thoracoscopic discectomy and fusion with instrumentation. Because of the large disc fragment, partial corpectomies of T-12 and L-1 were performed so that the fragment could be removed safely. After decompression, the corpectomy defect was reconstructed with an iliac crest allograft. An anterolateral plate (MACS-TL, Aesculap) was placed for T12–L1 fixation, as described previously.¹ During the procedure, a small amount of creamy white material was noticed flowing from the lateral aspect of the T-12 VB (Fig. 2). We thought that this was unlikely to be a chyle leak because of the left-sided approach and the fact that we only exposed the left lateral aspects of the VB with minimal soft-tissue dissection. When the “milky” leakage persisted, we attempted to identify the possible site of the leak with the assistance of a thoracic surgeon; however, we were not able to identify any structures that resembled the thoracic duct or one of its branches. Hence, surgical clips and Tisseel fibrin sealant were applied to the site of the leak until leakage stopped. A chest tube was put in place, and mild suction was applied.

Postoperative Course. On the 2nd postoperative day, after oral intake was initiated, a white milky fluid began to drain from the patient’s chest tube that was consistent with a chy-

Abbreviation used in this paper: VB = vertebral body.

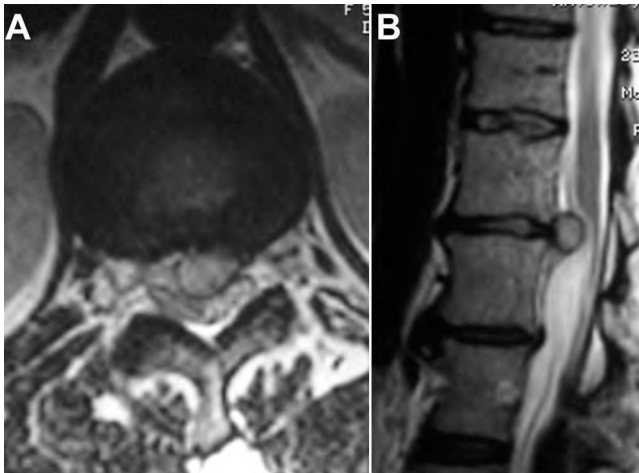


FIG. 1. Axial (A) and sagittal (B) T₂-weighted magnetic resonance images of the thoracic spine showing a large T12–L1 herniated disc compressing the spinal cord.

lous leak (Fig. 3). Because of this complication, oral intake was stopped, a peripherally inserted central catheter was placed for total parenteral nutrition, and the chest tube was converted from suction to a gravity drip. On postoperative Day 11 the chyle leak slowed dramatically, and it stopped completely on postoperative Day 12. The patient resumed oral intake that day, and she was observed closely for chylothorax. The chest tube was removed, and she was discharged home on postoperative Day 14, without any further complications. Chest x-ray studies obtained 4 weeks and 3 months after surgery did not show any pleural effusion.

Discussion

Thoracic duct injury and chylous leakage is a rare but known complication of anterior spinal surgery. In 1977,

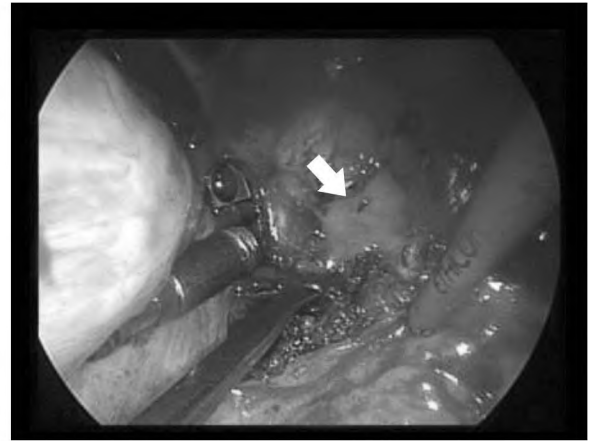


FIG. 2. Intraoperative thoracoscopic view of the left thoracolumbar junction demonstrating white milky fluid leaking at the T-12 level (arrow).

Eisenstein and O'Brien⁵ first reported a chylous leak after anterior spinal instrumentation. Since then, several cases of chylothorax have been reported in association with anterior spinal surgery.^{4,5,9,12,14,15} Hart et al.⁹ described a case of chylothorax associated with anterior cervical surgery and, in a review of the literature, found nine reported cases of chylothorax following anterior spinal surgery, all of which were in the thoracolumbar region. Most of these cases involved extensive, circumferential exposure to the thoracolumbar spine.

In contrast, we are aware of only one thoracic duct injury and chylous leak associated with thoracoscopic spinal surgery.¹³ In their series of 46 endoscopic thoracic microdiscectomies, Oskouian and Johnson¹³ reported a single thoracic duct injury. No chyle leak was noticed intraoperatively; however, on postoperative Day 2, as in our case, the patient presented with a high output chyle leak from the

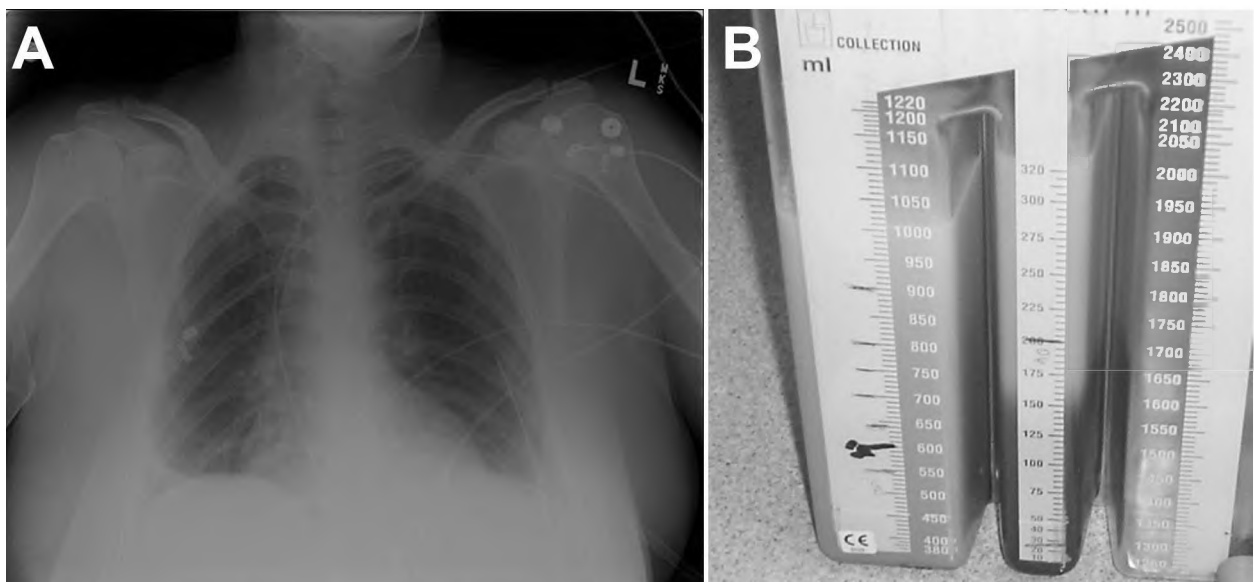


FIG. 3. A: Chest x-ray study demonstrating a small fluid collection obliterating the costodiaphragmatic angle. B: Photograph of a Pleurovac container showing the white, milky, creamy fluid collection from the pleural space.

Chylorrhea and thoracoscopic spinal surgery

chest tube but responded well to conservative treatment. Han et al.⁸ reported no thoracic duct injury or chylous leak in their series of 241 thoracoscopic procedures, including 60 thoracoscopic discectomies. In 371 cases of thoracoscopic spine surgery, Khoo et al.¹⁰ also reported no complications associated with thoracic duct injury. At the University of Utah, since 2003 we have performed more than 50 minimally invasive anterior spinal procedures for corpectomy and discectomies with stabilization, and this was our only case of chylorrhea.

The thoracic duct is a fragile, paper-thin tubular structure that is located in the posterior mediastinum. It is approximately 2 to 3 mm in diameter and 36 to 45 cm long and originates as cisterna chyli on the right side of the anterior surface of the L-2 VB. It enters the thorax via the aortic hiatus running superiorly initially on the right side of the anterior surface of the VBs between the esophagus and the azygous vein (Fig. 4). At the T-4 or T-5 VB it crosses to the left side and usually empties into the jugulosubclavian venous system.⁶ However, the anatomy of the thoracic duct is aberrant in almost 40% of patients.^{3,6}

Despite such proximity to the spinal column and a variable anatomy, the thoracic duct is usually not encountered or visualized during anterior spinal procedures. Probst-Proctor et al.¹⁴ surveyed 10 orthopedic surgeons who performed a total of 1000 anterior spinal procedures and found that the thoracic duct was seen only 12 times. Beisse et al., who have performed more than 900 thoracoscopic spinal surgeries at the Trauma Center Murnau in Germany, have not visualized the thoracic duct and have not encountered chylorrhea (personal communication, 2006). Although it is obviously rare, injury to thoracic duct with subsequent chylorrhea is a potentially serious complication of thoracoscopic spinal surgery that, if left untreated, can result in significant morbidity and even death. Hence, awareness and knowledge of the thoracic duct anatomy is very important in preventing chylorrhea. In addition, staying within the subperiosteal plane and ligaments anteriorly may help in avoiding injury to the thoracic duct.^{7,14}

Intraoperative spillage of creamy, milky white fluid should alarm the surgeon, and a prompt search to find the source should be undertaken. Because many patients are removed from oral intake prior to surgery, chyle flow is minimal during surgery and frequently very little or no leakage can be detected intraoperatively despite injury to the thoracic duct. The application of positive pressure ventilation by the anesthesiologist may help identify the leakage site. Postoperatively, chylorrhea should be suspected if a large amount of milky white output from the chest tube is observed once the patient's oral intake is resumed. The diagnosis can be confirmed by a high triglyceride level (> 110 mg/dl), presence of chylomicron, and positive Sudan stain if there is any question regarding the diagnosis.^{3,5} A cerebrospinal fluid leak after spinal surgery can also result in unusual fluid collection or pleural effusion, although cerebrospinal fluid is most commonly clear and not milky or white.

On diagnosis or suspicion of a chylous leak, oral intake should be stopped immediately to decrease the formation of chyle. The chest tube and surgical drains should be converted to a water seal or gravity drip to prevent high negative pressure. Total parenteral nutrition should be started and continued until the chylous leak is stopped. Most au-

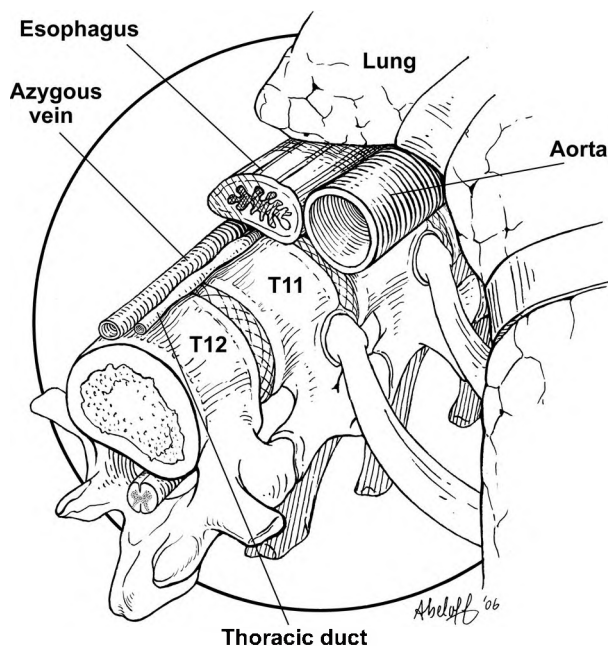


FIG. 4. Artist's illustration of the left thoracolumbar junction and the typical relationship of the thoracic duct to other anatomical structures.

thors recommend conservative management for up to 7 days.³ If the leakage continues despite conservative management for more than 7 to 9 days, consultation with a thoracic surgeon and surgical repair via clips applied to the thoracic duct is recommended.^{3,11} When conservative management fails, surgical reexploration and identification of the leakage site as well as primary closure via surgical clips are required. Surgical exploration may require extensive dissection and the assistance of a thoracic surgeon. If the chest tube has been removed before detection of the chyle leak, the patient may present in a delayed fashion with a pleural effusion, electrolyte abnormalities, or respiratory distress. In cases of delayed presentation, the patient should be admitted to the hospital to undergo placement of a chest tube and a peripherally inserted central catheter. Oral intake should be stopped, and total parenteral nutrition should be started.

The anomalous location of the thoracic duct at the left lateral thoracolumbar junction in our patient who underwent left-sided thoracoscopic discectomy is the most likely explanation for the thoracic duct injury. As with the other case reported in the literature, our patient responded well to conservative treatment, and the leakage stopped after 11 days.

Conclusions

Chylorrhea is a possible complication of thoracoscopic spinal surgery, and the surgeon should become suspicious if a white, milky, or creamy fluid is encountered intra- or postoperatively. The abundance of thoracic duct branches and the variability of its location place the thoracic duct and its tributaries at risk of injury during thoracoscopic procedures in the thoracolumbar region. Knowledge of the anatomy, recognition of potential leakage, and aggressive

early treatment are important in preventing morbidity associated with injury to this fragile structure.

References

1. Amini A, Beisse R, Schmidt MH: Thoracoscopic spine surgery for decompression and stabilization of the anterolateral thoracolumbar spine. **Neurosurg Focus** 19(6):E4, 2005
2. Bessone LN, Ferguson TB, Burford TH: Chylothorax. **Ann Thorac Surg** 12:527–550, 1971
3. Cerfolio RJ, Allen MS, Deschamps C, Trastek VF, Pairolero PC: Postoperative chylothorax. **J Thorac Cardiovasc Surg** 112:1361–1366, 1996
4. Colletta AJ, Mayer PJ: Chylothorax: an unusual complication of anterior thoracic interbody spinal fusion. **Spine** 7:46–49, 1982
5. Eisenstein S, O'Brien JP: Chylothorax: a complication of Dwyer's anterior instrumentation. **Br J Surg** 64:339–341, 1977
6. Gottlieb MI, Greenfield J: Variations in the terminal portion of the human thoracic duct. **AMA Arch Surg** 73:955–959, 1956
7. Hall JE: Dwyer Instrumentation in anterior fusion of the spine. **J Bone Joint Surg Am** 63:1188–1190, 1981
8. Han PP, Kenny K, Dickman CA: Thoracoscopic approaches to the thoracic spine: experience with 241 surgical procedures. **Neurosurgery** 51 (5 Suppl):S88–S95, 2002
9. Hart AK, Greinwald JH Jr, Shaffrey CI, Postma GN: Thoracic duct injury during anterior cervical discectomy: a rare complication. Case report. **J Neurosurg** 88:151–154, 1998
10. Khoo LT, Beisse R, Potulski M: Thoracoscopic-assisted treatment of thoracic and lumbar fractures: a series of 371 consecutive cases. **Neurosurgery** 51 (5 Suppl):S104–S117, 2002
11. Miller JJ Jr: Diagnosis and management of chylothorax. **Chest Surg Clin N Am** 6:139–148, 1996
12. Nakai S, Zielke K: Chylothorax—a rare complication after anterior and posterior spinal correction. Report on six cases. **Spine** 11:830–833, 1986
13. Oskouiian RJ, Johnson JP: Endoscopic thoracic microdiscectomy. **J Neurosurg Spine** 3:459–464, 2005
14. Propst-Proctor SL, Rinsky LA, Bleck EE: The cisterna chyli in orthopaedic surgery. **Spine** 8:787–792, 1983
15. Shen YS, Cheung CY, Nilsen PT: Chylous leakage after arthrodesis using the anterior approach to the spine. Report of two cases. **J Bone Joint Surg Am** 71:1250–1251, 1989

Manuscript submitted June 5, 2006.

Accepted February 23, 2007.

Address reprint requests to: Meic H. Schmidt, M.D., Department of Neurosurgery, University of Utah, 175 N. Medical Drive East, Salt Lake City, Utah 84132. email: meic.schmidt@hsc.utah.edu.