

Nerve sheath tumors involving the sacrum

Case report and classification scheme

PAUL KLIMO, JR., M.D., M.P.H., GANESH RAO, M.D., RICHARD H. SCHMIDT, M.D., PH.D., AND MEIC H. SCHMIDT, M.D.

Department of Neurosurgery, University of Utah, Salt Lake City, Utah

Nerve sheath tumors that involve the sacrum are rare. Delayed presentation is common because of their slow-growing nature, the permissive surrounding anatomical environment, and nonspecific symptoms. Consequently, these tumors are usually of considerable size at the time of diagnosis.

The authors discuss a case of a sacral nerve sheath tumor. They also propose a classification scheme for these tumors based on their location with respect to the sacrum into three types (Types I–III). Type I tumors are confined to the sacrum; Type II originate within the sacrum but then locally metastasize through the anterior and posterior sacral walls into the presacral and subcutaneous spaces, respectively; and Type III are located primarily in the presacral/retroperitoneal area. The overwhelming majority of sacral nerve sheath tumors are schwannomas. Neurofibromas and malignant nerve sheath tumors are exceedingly rare. Regardless of their histological features, the goal of treatment is complete excision. Adjuvant radiotherapy may be used in patients in whom resection was subtotal. Approaches to the sacrum can generally be classified as anterior or posterior. Type I tumors may be resected via a posterior approach alone, Type III may require an anterior approach, and Type II tumors usually require combined anterior–posterior surgery.

KEY WORDS • sacrum • nerve sheath tumor • schwannoma • neurofibroma

Sacral and presacral tumors are uncommon. Rasmussen, et al.,²⁶ found only 35 (7%) of 557 intraspinal tumors involving the sacrum. It has been estimated that these tumors occur in only one of 40,000 hospital admissions, but they are probably even more rare.⁴⁰

Nerve sheath tumors comprise only a small portion of the wide variety of lesions that occur in the sacral region.³⁹ In two reviews of more than 250 sacral and presacral tumors, the authors found only one NST.^{21,28} These tumors can often reach enormous dimensions before producing neurological symptoms and are difficult to diagnose at an early stage. The vast majority of sacral NSTs are schwannomas. En bloc resection is the treatment of choice. Because of their size and the presence of critical sacral nerve roots, however, this is often difficult and usually requires a team approach involving neurosurgeons and general surgeons. We discuss the recent case of a patient treated at our institution and report on the presentation, diagnosis, pathological features, and management of these rare spinal pathological entities.

Abbreviations used in this paper: CT = computerized tomography; EMG = electromyography; MR = magnetic resonance; NST = nerve sheath tumor.

CASE REPORT

Presentation. This 25-year-old woman was involved in a motor vehicle accident in which she sustained numerous injuries including a severe head injury. As part of the routine evaluation, she underwent imaging studies that revealed a pelvic mass. Prior to her accident, the patient had suffered mild low-back pain radiating bilaterally to her quadriceps as well as episodes of urinary incontinence; other features had also been suggestive of an atonic bladder.

Examination. Initial studies included an anteroposterior pelvic radiograph and an abdominal/pelvic CT scan. The plain radiograph demonstrated enlarged left sacral foramina (Fig. 1). The CT scan revealed a 9 × 6 × 6-cm heterogeneous calcified mass in the left pelvis emanating from the sacrum with concomitant osseous changes (Fig. 2). An MR imaging study suggested that the contrast-enhancing tumor originated from the S-2 nerve root (Fig. 3).

Operations. After almost 1 year of rehabilitation for her head injury, the patient was ready to undergo surgery. The tumor was first approached posteriorly through a midline, multilevel sacral laminectomy. The lamina had been significantly eroded by the mass. The intracanalicular portion of the tumor was carefully resected, and we periodically

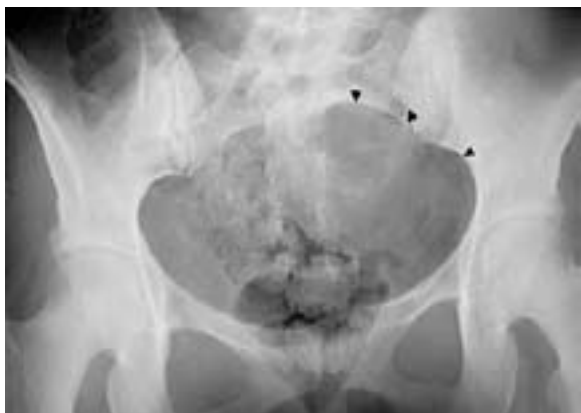

Fig. 1. Plain anteroposterior pelvic radiograph demonstrating a large asymmetrical lytic lesion of the left sacrum (arrowheads).

used a nerve stimulator and EMG to identify neural structures. Intradural exploration did not reveal tumor. One month later, a transabdominal approach was used to excise the presacral portion of the tumor. A midline incision was made from the umbilicus to the pubic bone. On entering the peritoneal cavity, the retroperitoneal space containing the mass was opened. A nerve stimulator and EMG were again used. Much of the tumor's capsule contained neural structures. The S-2 nerve root was found to enter the tumor eccentrically at its superior pole. A safe entry point was identified, and the tumor was debulked internally. With careful dissection, a gross-total resection was achieved.

Histological Examination. The patient's tumor was shown to be a classic schwannoma. It exhibited mild pleomorphism, varying degrees of cellularity, rare mitotic figures, and both Antoni A and B patterns.

Postoperative Course. The patient recovered well from her surgeries. She regained normal sphincter function and suffered no motor or sensory deficits. She underwent a re-

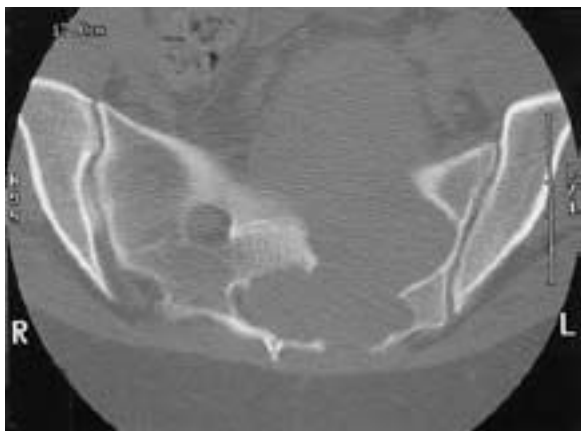


Fig. 2. Axial bone window CT scan revealing a large left sacral mass expanding into the presacral space. Note the markedly enlarged left neural foramen compared with the normal one on the right. The sclerotic margins suggest that the mass is slow growing and has been present for some time.

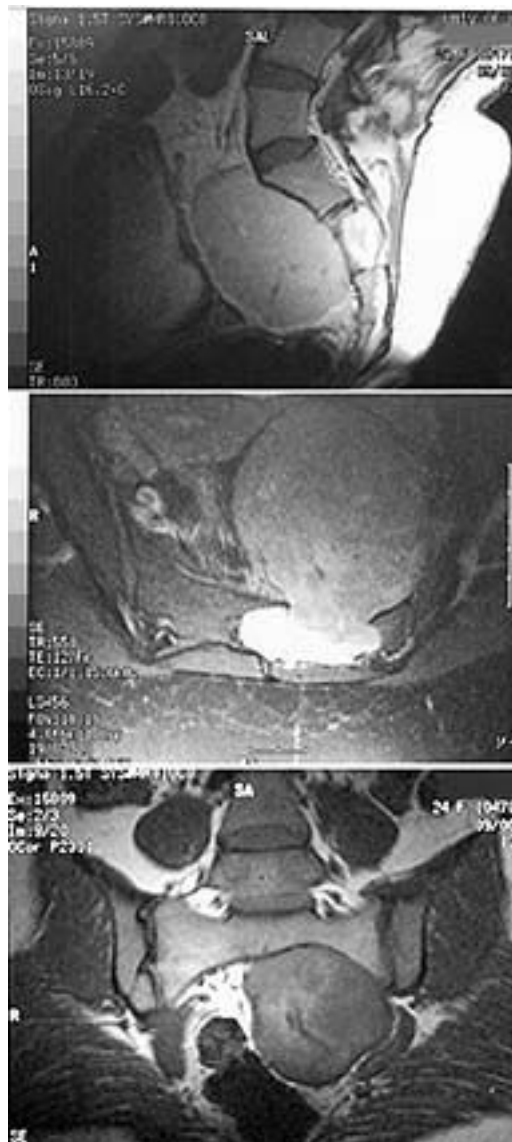


Fig. 3. Magnetic resonance images. *Upper:* Contrast-enhanced sagittal image revealing the intra- and presacral components of the tumor. Note the marked enhancement of the intrasacral portion compared with the presacral. *Center:* Axial image demonstrating the same features. *Lower:* Coronal image.

peated MR imaging study 1 year postoperatively, which revealed no recurrence.

CLINICAL MANIFESTATIONS

In most patients signs and symptoms have manifested by presentation because of the long period of latency since onset. The mean duration of symptoms ranges from 1 to 7 years.^{1,3,6,7,36} There is a report of a patient harboring a tumor for more than 25 years before the onset of symptoms.¹⁶ The constellation of signs and/or symptoms is similar for tumors that arise within the sacrum and extend into the pelvis and those that originate anterior to the sacrum and subsequently erode into the sacrum, regardless of histology. Pain is the most common presenting symptom and

Sacral nerve sheath tumors

may be localized low-back or radicular pain, extending in the distribution of one or more lumbar or sacral roots.^{1,3,6,7,38} Sensory symptoms include paresthesias and dysesthesias. Urinary hesitancy, retention, weak stream and overflow, and unconscious incontinence are present in patients with an acontractile bladder. Patients may present with repeated bouts of cystitis.³ A neurogenic bladder must be ruled out in patients, especially males, who present with repeated urinary tract infections and no obvious cause. Some patients complain of constipation and an unpleasant feeling of rectal fullness or pain.^{7,19}

Signs include lower-extremity weakness, atrophy, decreased deep tendon reflexes (particularly the Achilles), and diminished saddle and lower-extremity sensation. One of the most important physical examination maneuvers in patients with a suspected sacral mass is the digital rectal evaluation. The mass is often palpable and may provide the physician with a more limited differential diagnosis.³⁶ Developmental enteric cysts are usually in the midline, soft, and nontender. Anterior sacral meningoceles are also midline, soft, and may cause headache or cough on palpation. Chordomas are often irregular and solid. Inflammatory lesions are often painful. Finally, NSTs are firm, smooth, and often off the midline.

IMAGING FEATURES

A wide variety of pathological masses may involve the sacrum: chordomas, giant cell tumors, osteoblastomas, plasmacytomas, lymphomas, chondrosarcomas, teratomas, inflammatory and congenital lesions, anterior meningoceles, neuroblastomas, and aneurysmal bone cysts.³⁹ Nerve sheath tumors may arise from the within the sacrum or anterior to it in the presacral/retroperitoneal space. Prior to the CT/MR imaging era, plain pelvic radiography was the only available imaging modality. Features such as lytic lesions, distortion, and expansion of the normal sacral anatomy, enlargement of sacral neural foramina, and abnormal calcifications are present in almost all patients. Overlying bowel shadows can obscure details, however, especially when the tumor causes hypomotility of the bowels.^{18,19,39} Many patients will undergo a barium enema on the presumption that the mass represents a primary enteric entity.

A more complete and detailed assessment of the sacrum is provided by CT scanning. It also demonstrates the relationship between the tumor and anatomical structures within the pelvis. Sagittal and coronal CT reconstructions provide added detail. Lesions adjacent to the sacrum typically cause anterior sacral erosion, whereas one arising from within the sacral canal causes erosion of both the anterior and posterior sacral borders as well as expansion of the sacrum.^{5,36} Magnetic resonance imaging provides superior resolution of soft-tissue structures with multiplanar capability. Sacral NSTs do not exhibit the typical MR imaging features characteristic of NSTs found elsewhere, such as a fusiform shape, eccentric tumor with respect to the host nerve, “split-fat” sign, “target” sign, and the “fascicular” sign.²⁵ Sacral NSTs are large, eccentric, well-defined heterogeneous, enhancing masses. Because of their slow growth, they may exhibit degenerative changes such as cyst formation, hemorrhage, necrosis, and calcification. These features are common in “ancient” or degenerative

schwannomas but rare in neurofibromas. A pseudocapsule is often visible as a rim of hypointensity in schwannomas, whereas only 30% of neurofibromas possess a capsule.²⁵ Benign sacral NSTs are typically not markedly vascular; however, malignant NSTs can be.^{7,9,18} Tumors in this region may be fed by multiple vascular pedicles, including the medial and lateral sacral arteries, as well as branches of the lumbar and internal iliac vessels.

HISTOPATHOLOGICAL FEATURES

The vast majority of sacral NSTs are schwannomas. In much of the early literature, there is no differentiation between terms such as schwannoma, neurofibroma, and neurilemmoma, making the exact diagnosis uncertain.^{3,5} Schwannomas are benign, encapsulated tumors composed entirely of cells with the immunophenotype and ultrastructural features of Schwann cells.³² There are numerous schwannoma variants. In its classic form, the cells are spindle shaped with pale, eosinophilic cytoplasm arranged in two characteristic patterns: Antoni A (“dense”) and B (“loose”). The hallmark histological feature of a schwannoma are the Verocay bodies. The proportion of each pattern varies, and the interface between them may be gradual or sudden. Although not officially considered a specific variant, ancient schwannomas or longstanding schwannomas often show stromal and vascular degenerative changes including central tissue loss with cystic formation, necrosis without nuclear palisading, nuclear atypia, widespread hyalinization, and calcification.^{20,22,32,38} Cellular schwannomas differ from the classic type in that the dense Antoni A pattern comprises 90% or more of the tumor area with a more uniform pattern, a lack of Verocay bodies, and frequent lymphocytic infiltration.^{1,24,32} There is one report of a sacral melanocytic schwannoma in the literature.¹³

Neurofibroma is a benign nerve sheath tumor composed of cells with a polymorphic cellular phenotype. These include Schwann and perineural cells as well as endoneurial fibroblasts. Neurofibromas are composed of widely spaced cells with ovoid-to-thin elongate nuclei and scant cytoplasm embedded in a mucopolysaccharide-rich, variably collagenous matrix. The neurofibroma cells are usually aligned along the course of nerve fibers traversing the lesion. These rarely involve the sacral region.^{7,18,37}

Malignant nerve sheath tumors also very rarely occur in the sacrum.^{7,9,12} Again, the terminology in the literature is confusing and involves various terms such as malignant schwannoma and neurofibrosarcoma interchangeably. Previous radiotherapy has also been shown to contribute to the development of malignant NST.¹² The hallmark features of malignant NSTs include intrafascicular spread within or beyond the main tumor mass and invasion of the surrounding tissue. Most are surrounded by a fibrous pseudocapsule and areas of gross necrosis. Microscopically, most are highly cellular with numerous mitoses (usually > 10/hpf), pleomorphism, and necrosis.

TREATMENT AND RESULTS

The goal of treatment is the same for NSTs located elsewhere: complete resection. This is often difficult because of their size, robust blood supply, and proximity to elo-

quent neurological and nonneurological structures. Approaches to these tumors may be anterior, posterior, or combined. The approach is dictated by the amount of intrapelvic and intrasacral involvement. A team approach comprising a neurosurgeon, orthopedist, and an abdomen surgeon is often needed for successful resection. Intraoperative EMG and nerve stimulators should always be performed to verify critical neural structures.

Presacral NSTs may arise from the retroperitoneal space or by local extension from the sacrum. In general, tumors with a large presacral/retroperitoneal component should be approached anteriorly.^{2,4,11,20,22,24} The most significant challenge in this approach is controlling arterial and venous vasculature. Profuse bleeding is usually due to tearing of the numerous delicate venous channels.^{1,24} Some authors believe that most of the intrasacral component can be removed anteriorly.² An extraperitoneal approach to the retroperitoneal space by making a right-sided flank incision has also been described in a patient with a predominantly presacral tumor.³⁷

Posterior approaches are performed in cases of tumors involving a significant intrasacral component.^{7,15,18,19,23,27,30} Intradural proliferation, which is usually found in tumors with a cephalad extension, is an absolute indication for a posterior approach.² Similar to proponents of the anterior approach, some authors have indicated that presacral components, if less than 10 cm, may be removed via a posterior approach.^{27,36}

In tumors with large pre- and intrasacral components, combined anterior–posterior surgical approaches are usually needed.^{1,17,38,41} This can be conducted in two stages, as in our patient, or in a single sitting. The abdominosacral approach allows a combined abdominal–transsacral approach.^{17,38} The patient is placed in a lateral decubitus position, and the abdomen is entered through an oblique incision starting between the iliac crest and the costal margin, running parallel to the inguinal ligament. To achieve maximum cytological reductive surgery, total sacrectomy is sometimes needed.^{31,33,35} This formidable task involves anterior and posterior approaches and internal fixation by fusion with L-5.³¹ Alternatively, a high sacral amputation may be performed at one of two levels: between S-1 and S-2 and through S-1.³⁵ Such procedures, however, may cause significant neurological deficits. Bilateral sacrifice of all sacral nerves except the S-1 nerve will result in loss of bowel, bladder, and sexual function.³⁵ Ambulation should be marginally affected. Gluteus maximus weakness may be evident when climbing stairs. Most authors agree that sparing the first three sacral nerve roots bilaterally or all the sacral nerves unilaterally guarantees preservation of autonomic function.^{7,10,34,35,41,42}

Core needle biopsy procedures are often performed and have positive and negative attributes. Opponents of this procedure have cited a high rate of inconclusive results, the potential for misdiagnosis of a malignant neoplasm, complications such as infection and hemorrhage, and the possibility of tumor dissemination along the biopsy tract as reasons not pursue it.^{1,4,11,18} Others have contended that it is useful in excluding other diagnoses that would not benefit from surgery such as lymphoma, planning a less radical operation, and easy accessibility through the vagina or rectum.^{7,24}

Radiotherapy is generally avoided in the treatment of benign tumors, primarily because of the risk of developing secondary neoplasms. The use of conventional external beam radiation therapy, however, has been reported in a patient with an incompletely excised sacral schwannoma.¹⁴ More recently, stereotactic radiosurgery has become an alternative therapy for spinal neoplasms.^{8,29} Although it would not be a feasible option for most sacral NSTs, it could conceivably be conducted to treat those tumors that are small (< 3 cm) and isolated to the sacrum.

Most articles regarding sacral NSTs are single case reports.^{2,15,20,22,23,27,30,38} There are several case series, the largest involving 13 patients.^{1,6,7,42} Feldenzer, et al.,⁷ treated nine cases with presacral extension, in four of which NSTs were present. A combined anterior–posterior approach was performed in two patients, and the other two underwent surgery via a posterior approach. Two patients harbored malignant NSTs, and both died within 3 years of diagnosis. In the other two patients gross-total resection was achieved, and there was no evidence of recurrence. Dominguez, et al.,⁶ reported on six patients who harbored giant intrasacral schwannomas. Four patients underwent a posterior approach, whereas the other two had a combined procedure. Intradural extension was present in three cases. In one patient a recurrence developed 17 years after her initial resection.

In the series by Abernathy, et al.,¹ 10 patients underwent a posterior and three an anterior approach. Intradural invasion was demonstrated in four patients, requiring open dural procedures. Gross total resection was achieved in four patients. Of the nine patients in whom a subtotal resection was achieved, five remained symptom free during the study period but four (44%) required a second operation. The disease-free interval ranged from 7 to 84 months. The second operation was anterior in three and combined in one patient. One patient also required internal fixation. All 13 patients reported improvement in their pain, and all were ambulatory and functional. Six patients suffered surgery-induced neurological deficits: sensory loss in four, bowel/bladder dysfunction in one, and the last had both motor and autonomic deficits. Wound complications developed in three patients.

CLASSIFICATION OF SACRAL NSTS

In reviewing the literature, we devised a straightforward classification system for sacral nerve sheath tumors. As stated previously, these tumors may anatomically arise from the presacral space or within the sacrum and extend into the presacral or posterior subcutaneous space. The precise anatomical distribution of the tumor determines the surgical approach (Fig. 4). We propose that a Type I sacral NST is one that is confined to the sacrum; a Type II has eroded either the anterior or posterior sacral wall and spread to adjacent spaces; and a Type III is confined to the presacral space. Thus, a Type II tumor (the most common) would probably require a combined anterior–posterior approach, a Type I a posterior approach, and a Type III an anterior approach.

CONCLUSIONS

A variety of neoplasms may occur at the sacral region.

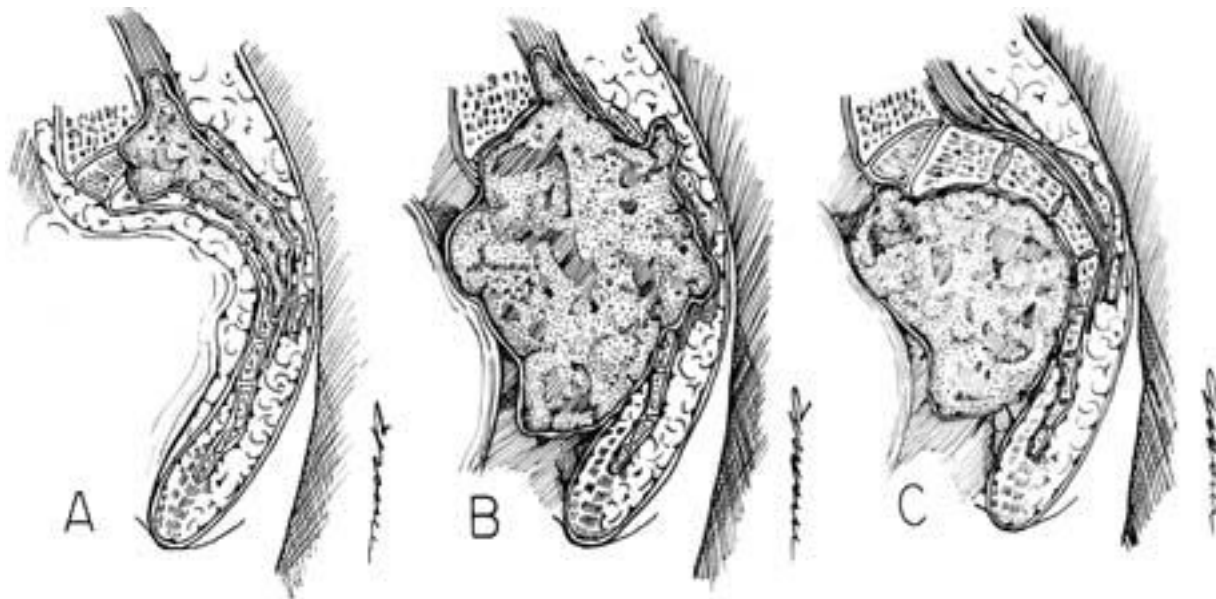


Fig. 4. Schematic drawings depicting the classification system for sacral NSTs. A: Type I in which the tumor is confined to the sacrum. Note that the tumor may invade and track along the spinal canal. B: Type II in which the tumor has breached the anterior and/or posterior osseous margins of the sacrum. This is the most common type. C: Type III in which the tumor is located within the presacral space. There may be mild osseous changes to the sacrum as a result of longstanding compression.

Nerve sheath tumors, which include schwannomas, neurofibromas, and malignant NSTs, comprise a small percentage of lesions in this area. They are characterized by slow steady growth and vague nonspecific symptoms. The workup involves extensive imaging studies, namely CT and MR imaging. Type I tumors are located exclusively within the presacral/retroperitoneal space, Type II have both pre- and intrasacral components, and Type III are only intrasacral. Surgery is the treatment of choice. A cure may be achieved by gross-total resection, but this goal should be tempered by consideration of the potential morbidities, and treatment should be individualized. Surgical approaches include anterior, posterior, and combinations of both.

References

1. Abernathy CD, Onofrio BM, Scheithauer B, et al: Surgical management of giant sacral schwannomas. *J Neurosurg* **65**: 286–295, 1986
2. Acciarri N, Staffa G, Poppi M: Giant sacral schwannoma: removal by an anterior, transabdominal approach. *Br J Neurosurg* **10**:489–492, 1996
3. Adson AW, Moersch FP, Kernohan JW: Neurogenic tumors arising from the sacrum. *Arch Neurol Psychiatry* **41**:535–555, 1939
4. Bastounis E, Asimacopoulos PJ, Pikoulis E, et al: Benign retroperitoneal neural sheath tumors in patients without von Recklinghausen's disease. *Scand J Urol Nephrol* **31**:129–136, 1997
5. DeSanto DA, Burgess E: Primary and secondary neurilemmoma of bone. *Surg Gynecol Obstet* **71**:454–461, 1940
6. Dominguez J, Lobato RD, Ramos A, et al: Giant intrasacral schwannomas: report of six cases. *Acta Neurochir* **139**: 954–960, 1997
7. Feldenzer JA, McGauley JL, McGillicuddy JE: Sacral and presacral tumors: problems in diagnosis and management. *Neurosurgery* **25**:884–891, 1989
8. Gertszten PC, Ozhasoglu C, Burton SA, et al: Feasibility of frameless single-fraction stereotactic radiosurgery for spinal lesions. *Neurosurg Focus* **13** (4):Article 2, 2002
9. Grnja V, Allen WE III, Osborn DJ, et al: Sacral neurofibrosarcoma: an angiographic evaluation. Case report. *J Neurosurg* **40**:767–771, 1974
10. Gunterberg B, Kewenter J, Petersen I, et al: Anorectal function after major resections of the sacrum with bilateral or unilateral sacrifice of sacral nerves. *Br J Surg* **63**:546–554, 1976
11. Guz B, Wood DP Jr, Montie JE, et al: Retroperitoneal neural sheath tumors: Cleveland Clinic experience. *J Urol* **142**: 1434–1437, 1989
12. Isler MH, Fogaca MF, Mankin HJ: Radiation induced malignant schwannoma arising in a neurofibroma. *Clin Orthop* **325**: 251–255, 1996
13. Killeen RM, Davy CL, Bauserman SC: Melanocytic schwannoma. *Cancer* **62**:174–183, 1988
14. Kotoura Y, Shikata J, Yamamuro T, et al: Radiation therapy for giant intrasacral schwannoma. *Spine* **16**:239–242, 1991
15. Lesoin F, Krivosic I, Cama A, et al: A giant intrasacral schwannoma revealed by lumbosacral pain. *Neurochirurgia* **27**: 23–24, 1984
16. Lin PP, Horenstein MG, Healey JH: Sacral mass in a 56-year-old woman. *Clin Orthop* **344**:333–337, 341–333, 1997
17. Localio SA, Eng K, Ranson JH: Abdominosacral approach for retrorectal tumors. *Ann Surg* **191**:555–560, 1980
18. Luken MG III, Michelsen WJ, Whelan MA, et al: The diagnosis of sacral lesions. *Surg Neurol* **15**:377–383, 1981
19. MacCarty CS, Waugh JM, Coventry MB, et al: Surgical treatment of sacral and presacral tumors other than sacrococcygeal chordoma. *J Neurosurg* **22**:458–464, 1965
20. Maneschg C, Rogatsch H, Bartsch G, et al: Treatment of giant ancient pelvic schwannoma. *Tech Urol* **7**:296–298, 2001
21. Mayo CW, Baker GS, Smith LR: Presacral tumors: differential diagnosis and report of a case. *Proc Staff Meet Mayo Clin* **28**: 616–622, 1953

22. Ogose A, Hotta T, Sato S, et al: Presacral schwannoma with purely cystic form. **Spine** **26**:1817–1819, 2001
23. Ortolan EG, Sola CA, Gruenberg MF, et al: Giant sacral schwannoma. A case report. **Spine** **21**:522–526, 1996
24. Patocskai EJ, Tabatabaian M, Thomas MJ: Cellular schwannoma: a rare presacral tumour. **Can J Surg** **45**:141–144, 2002
25. Popuri R, Davies AM: MR imaging features of giant presacral schwannomas: a report of four cases. **Eur Radiol** **12**:2365–2369, 2002
26. Rasmussen TB, Kernohan JW, Adson AW: Pathologic classification, with surgical consideration, of intraspinal tumors. **Ann Surg** **111**:513–530, 1940
27. Rengachary SS, O'Boynick P, Batnitzky S, et al: Giant intrasacral Schwannoma: case report. **Neurosurgery** **9**:573–577, 1981
28. Ross ST: Sacral and presacral tumors. **Am J Surg** **76**:687–693, 1948
29. Ryu S, Kim D, Martin D, et al: Image-guided spinal stereotactic radiosurgery. **Tech Neurosurg** **8**:56–64, 2003
30. Salvant JB Jr, Young HF: Giant intrasacral schwannoma: an unusual cause of lumbrosacral radiculopathy. **Surg Neurol** **41**:411–413, 1994
31. Santi MD, Mitsunaga MM, Lockett JL: Total sacrectomy for a giant sacral schwannoma. A case report. **Clin Orthop** **294**:285–289, 1993
32. Scheithauer B, Woodruff J, Erlandson R: **Atlas of Tumor Pathology. Tumors of the Peripheral Nervous System, ed 3, fascicle 24.** Washington, DC: Armed Forces Institute of Pathology, 1999, pp 105–415
33. Shikata J, Yamamuro T, Kotoura Y, et al: Total sacrectomy and reconstruction for primary tumors. **J Bone Joint Surg Am** **70**:122–125, 1988
34. Smith PH, Ballantyne B: The neuroanatomical basis for denervation of the urinary bladder following major pelvic surgery. **Br J Surg** **55**:929–933, 1968
35. Stener B, Gunterberg B: High amputation of the sacrum for extirpation of tumors. Principles and technique. **Spine** **3**:351–366, 1978
36. Stewart RJ, Humphreys WG, Parks TG: The presentation and management of presacral tumours. **Br J Surg** **73**:153–155, 1986
37. Topsakal C, Erol FS, Ozercan I, et al: Presacral solitary giant neurofibroma without neurofibromatosis type 1 presenting as pelvic mass—case report. **Neurol Med Chir** **41**:620–625, 2001
38. Turk PS, Peters N, Libbey NP, et al: Diagnosis and management of giant intrasacral schwannoma. **Cancer** **70**:2650–2657, 1992
39. Turner ML, Mulhern CB, Dalinka MK: Lesions of the sacrum. Differential diagnosis and radiological evaluation. **JAMA** **245**:275–277, 1981
40. Whittaker LD, Pemberton JD: Tumors ventral to the sacrum. **Ann Surg** **107**:96–106, 1938
41. Wuisman P, Harle A, Matthiass H, et al: Two-stage therapy in the treatment of sacral tumors. **Arch Orthop Trauma Surg** **108**:255–260, 1989
42. Xu WP, Song XW, Yue SY, et al: Primary sacral tumors and their surgical treatment. A report of 87 cases. **Chin Med J** **103**:879–884, 1990

Manuscript received June 2, 2003.

Accepted in final form July 3, 2003.

Address reprint requests to: Meic H. Schmidt, M.D., Department of Neurosurgery, University of Utah, 30 North 1900 East, Suite 3B-409 SOM, Salt Lake City, Utah 84132-2303. email: meic.schmidt@hsc.utah.edu