

## Historical vignette

# William Osler at McGill University: the Baby Professor and his early contributions to neurosurgery

WILLIAM T. COULDWELL, M.D., PH.D.,  
WILLIAM FEINDEL, M.D., C.M., D.PHIL., F.R.C.S.(C),  
AND RICHARD L. ROVIT, M.D., M.Sc.

*Department of Neurosurgery, University of Utah, Salt Lake City, Utah; Department of Neurology and Neurosurgery, Montreal Neurological Institute, McGill University, Montreal, Quebec, Canada; and Department of Neurosurgery, New York Medical College, Valhalla and New York, New York*

✓ Between 1870 and 1884, as both a medical student and a member of the faculty, Sir William Osler performed approximately 1000 postmortem examinations at McGill University in Montreal. He conducted 786 of these examinations during his 7 years (1877–1884) of service as a pathologist at the Montreal General Hospital. The results of these were carefully recorded and catalogued either by him or by those who compiled the Pathological Report of the Hospital. Included in this material are many early descriptions of neurosurgical disease. Osler used this information for subsequent teaching in both Philadelphia and Baltimore. Osler's early and lifelong special interest in diseases of the nervous system not only led him to make seminal observations but also served to initiate his influence and relationships with the emerging leaders in neurology and neurosurgery.

**KEY WORDS** • William Osler • neurosurgical history • neurosurgery • neuropathology

**I**N August 1874 barely 2 years after graduation from its medical school, 25-year-old William Osler returned to McGill University in Montreal as the newly appointed lecturer on the Institutes of Medicine, a course encompassing primarily pathology and physiology. His youthfulness led some students to refer to him as the Baby Professor (Fig. 1).<sup>7</sup> Osler had spent the 2 years after his graduation from McGill in Great Britain, Germany, and Austria. He was greatly impressed with Rudolph Virchow, who was probably Germany's most outstanding medical scientist of the nineteenth century.

It is the mastermind of Virchow and the splendid Pathological Institute . . . that specially attract foreign students to Berlin. This most remarkable man is yet in his prime. . . . comprehensive intellect and untiring energy . . . Virchow himself performs a post-mortem every Monday morning making it with such care and minuteness that three or four hours may elapse before it is finished.<sup>18,29</sup>

Late in 1874, Osler obtained an appointment as a physician in the smallpox ward at the Montreal General Hospital (Fig. 2), for which the hospital paid him \$600. He spent most of this sum to obtain 15 Hartnack microscopes from Paris for his students' use in an optional practical course he introduced on microscopy and histology. "Progress must be our watchword, and we must endeavor to keep pace with the old country institutions. . . . I may venture to congratulate McGill College as the first in this country to offer such a course."<sup>32</sup>

In the summer of 1876, Osler repeated his histology course and added a new course, "Practical Pathological Demonstrations." Both were conducted in the postmortem room at the Montreal General Hospital. Osler and his students volunteered to conduct all of the hospital's autopsies, which previously had been performed, if at all, by the attending physicians. These courses—probably the first of their kind in North America—were repeated on Saturday mornings in the winter in a stove-heated shack behind the hospital. There, Osler and his students amassed the pathological findings and, following Virchow's techniques, correlated them with the clinical history. Each case report was transcribed in the Montreal General Hospital Pathological Reports on a yearly basis.<sup>31</sup>

During his 2 years (1870–1872) as a medical student (Fig. 3) and the 10 years (1874–1884) he was a member of McGill's faculty, Osler or his students performed approximately 1000 autopsies. Among these, during his 7 years (1877–1884) of service as a pathologist at the Montreal General Hospital, he conducted 786 postmortem examinations. Some of the pathological specimens, suitably preserved and labeled, can still be observed today at McGill's Pathological Institute. The reports, transcribed and bound chronologically by personnel at the Montreal General Hospital under the supervision of Maude Abbott,<sup>12</sup> are still available in the Osler Library.

Osler subsequently used the collected clinical and pathological data as material for his classroom lectures. He com-



FIG. 1. Photograph depicting William Osler in 1881, the Baby Professor of the Institutes of Medicine, McGill University, who was a rising star in the North Atlantic medical world. Reproduced courtesy of the Osler Library of the History of Medicine, McGill University, Montreal, Quebec, Canada. Photograph by William Notman.

monly presented his findings at meetings of the Medico-Chirurgical Society of Montreal, for whom he became the unofficial pathologist, and published many of those findings in the *Canada Medical and Surgical Journal*.<sup>8,10,13,17,25,39,27,28,30,37,40</sup> Many important novel observations of neurosurgical disease are included in this material.

We present in this paper some of Osler's most important observations on neurosurgical disease collected from his case reports as well as materials from other venues that highlight his particular interest in the brain and its disorders.

### Vascular Disease: Illustrative Cases

Osler's records include many cases with clinical and pathological descriptions of intracranial vascular disease. His broad interest in the pathological features of aneurysms extended to those on the cerebral arteries, and from his Montreal material he sketched the location of ten aneurysms on the circle of Willis and its branches.<sup>12</sup> Several cases of cerebral aneurysms, including berry aneurysms, may be cited (Fig. 4).

#### Case 1

John Bell, A.M., M.D. (1845–1878), was a surgeon and physician at the Protestant Infants' Home and the Montreal Dispensary; he and Osler published one of the early papers on pernicious anemia.

On the morning of May 29th Mrs. R. was found by her children lying speechless in bed. She was 40 years old, was married at 21, and had borne five children, the youngest of whom is now 15. She was of medium height and rather thin. It was said that she was sometimes abused by her husband, who beat her about the head, and finally left her to earn a living by washing. . . .<sup>5</sup>



FIG. 2. Photograph of the Montreal General Hospital, November 1874. Reproduced courtesy of the Osler Library of the History of Medicine, McGill University, Montreal, Quebec, Canada.

## William Osler at McGill University

(On paralysis with aphasia, by Dr. John Reddy, who read the paper and demonstrated the specimen before the Medico-Chirurgical Society of Montreal, March 9, 1872.) Specimen, from the first of the four cases reported, prepared by W. Osler. *Canada M. J.*, Montreal, 1871-72, viii, 407-408.

"I am much indebted to Mr. William Osler, who assisted me at the post mortem, and who has kindly made me this very valuable wet preparation by which you will be enabled readily to perceive the clot *in situ* in the arteries." (Drawing of same also published).

[Graduation thesis on pathological anatomy.] (Unpublished.) Statement in *Canada M. J.*, Montreal, 1872, viii, 473-474.

FIG. 3. Entry from Abbott's bibliography noting that Osler, while still a medical student, assisted at a postmortem in a patient who had died from an embolus in the middle cerebral artery. Reproduced courtesy of the Osler Library of the History of Medicine, McGill University, Montreal, Quebec, Canada.

A postmortem was performed by Dr. Osler 11 hours after the woman's death.

Body that of an average sized poorly nourished woman . . .

Head . . . In the removal of the brain, clots were met with in the neighborhood of the middle fossa of the base of the skull on the right side, and they were seen to have proceeded from a large extravasation which had taken place in the right Sylvian fissure. The convolutions of the middle lobe in the vicinity were considerably lacerated, the brain tissue broken down and replaced by a dark clot. About a handful of coagulated blood was removed, most of which was in and about the Sylvian fissure. Only a thin layer of blood existed in the base, around the optic commissure and perforated spaces. A delicate coagulum also extended over the convolutions in the lateral region on the right side. The circle of Willis and middle cerebral artery were removed for subsequent examination. . . . On carefully washing away the clots from the right middle cerebral artery, the source of the haemorrhage was ascertained to be a small aneurism, situated in the fork of the chief bifurcation of the vessel. This had ruptured, and the blood had escaped through a large ragged orifice.<sup>5</sup>

### Case 2

The following includes what is likely a very early description of a case of Terson syndrome (retinal or vitreous hemorrhage, usually associated with subarachnoid hemorrhage; Fig. 4):

F.E., aged 17, shoemaker, well-built, admitted to Hospital insensible on the evening of Dec. 18<sup>th</sup>. Patient lies in bed, eyes closed, pupils contracted, muscles of arms and forearms rigid and flexed, legs slightly rigid, but straight; respirations stertorous, 18 a minute; pulse small, 100; temperature normal. . . .

Autopsy.—Extensive hemorrhage at the base of the brain, involving the meninges, anterior to the optic chiasm, and extending in to the longitudinal fissure, and over the anterior part of the corpus callosum. On separating the orbital surfaces of the frontal lobes, an aneurismal sac, the size of a large pea, was seen springing from the anterior communicating artery and partially embedded in the contiguous brain substance, which was a little lacerated. When removed and washed, the sac was found to arise by a small orifice from the anterior communicating artery close to the right anterior cerebral. It was full of dark red blood, and had ruptured at the lower surface, the rent being about two millimetres in length. The hemorrhage had extended along the sheaths of the optic nerves to the eyeballs. The other cerebral vessels were healthy. There was no heart disease.<sup>3</sup>

### Case 3

On November 17, 1882, at a meeting of the Medico-

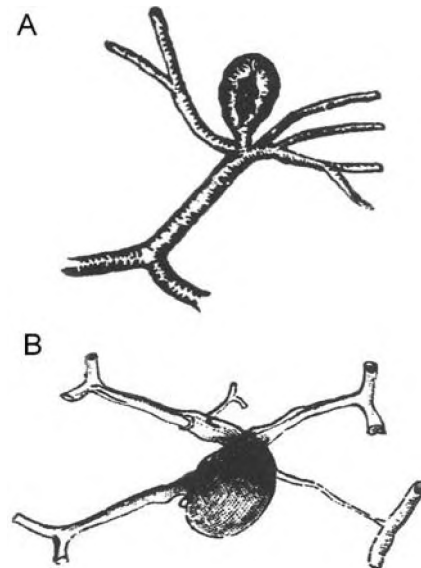


FIG. 4. Illustrations depicting examples of ruptured cerebral aneurysms. Case 1. A ruptured middle cerebral artery aneurysm (A). Case 2. A ruptured anterior cerebral artery aneurysm (B). Reproduced from Hospital report. *Can Med Surg J* 11:548-549, 1882/83.

Chirurgical Society of Montreal, Osler described the case of a young man who succumbed to a likely carotid-cavernous fistula several weeks after head trauma:

Erosion of Internal Carotid in Cavernous Sinus six weeks after a blow on the head. Fatal haemorrhage from the nose.—The patient, aet. 21, had received a blow over the left eye, being one of the victims of the "Beauharnois" boiler explosion. There was a long wound extending the whole length of the eyebrow, but it was not thought he had received any other injury, as he recovered quickly. Some time after, however, he noticed that the sight of that eye was failing, and he consulted Dr. Buller [Frank Buller (1844-1905), the first professor of ophthalmology and otology at McGill University], who diagnosed commencing atrophy of the optic nerve, due probably to extravasation in the sheath. He had several attacks of epistaxis, but not of an alarming character. One morning, about six weeks after the accident, while washing his face, profuse haemorrhage took place from the nostrils, and he died before assistance could be procured. . . . Though no fracture of the sphenoid was evident, yet it was believed that at the time of the accident a slight fracture must have occurred leading to ulceration and erosion of the bone and subsequent perforation of the carotid. Dr. Osler remarked that the case was unique in many respects, but Mr. Prescott Hewitt, in his lectures upon fractures at the base, mentions an instance in the practice of Mr. Scott of the London Hospital in which after an injury a pulsating tumor of the orbit occurred, and during an examination profuse haemorrhage from the nostrils took place, which was controlled by compression of the common carotid, and subsequently cured by ligation of that vessel.<sup>4</sup>

### Case 4

At a meeting of the Medico-Chirurgical Society of Montreal on November 14, 1879, Osler provided the following account of a spontaneous hemorrhage into the basal ganglia and discussed the likely source of the hemorrhage:

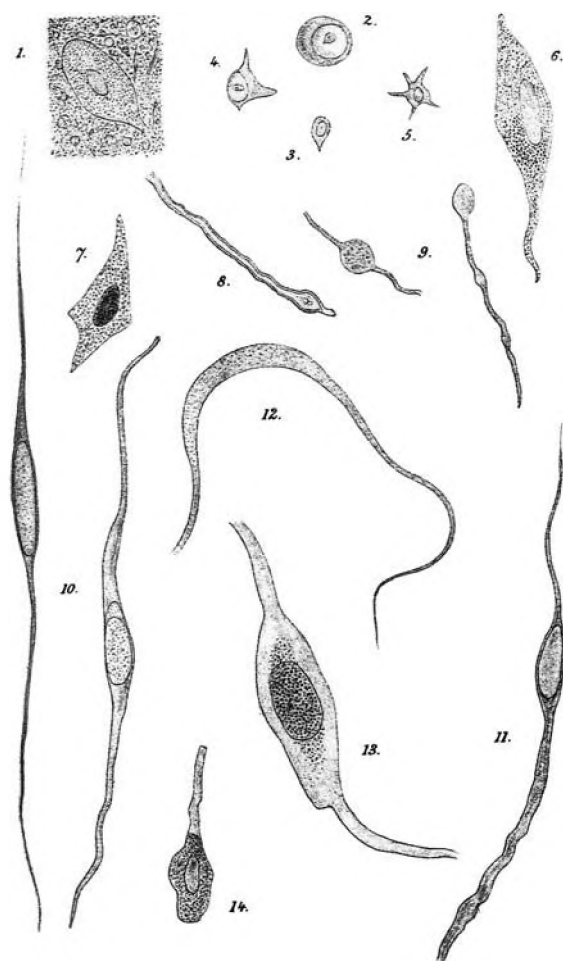


FIG. 5. Drawings by Osler of the various cell types observed in a thalamic glioma. "1-9, From mass on left thalamus. 10-14, From tumour in 3d ventricle. (1), General appearance of the matrix, with a ganglion cell embedded in it; (2, 3, 4, and 5), small cells, some looking like corpuscles of the neuroglia; (6 and 7); large ganglion cells; (8), double contoured nerve fibre; (9), fibres, probably nervous, with curious bead-like swellings; (10 and 11), elongated fibre-cells from mass in 3d ventricle; (12), very translucent fibre without nucleus; (13 and 14), cells resembling nerve corpuscles, with ribbon-like processes." Reproduced from Osler W, Case of medullary neuroma of the brain. *J Anat Physiol* 15:217-225, 1880/81.

Case II—Haemorrhage into left caudate nucleus; softening of anterior fibres of internal capsule and outer section of lenticular nucleus. Hemiplegia; early rigidity. Loss at first, subsequent return, of sensation in paralysed side. . . .

Autopsy

Frontal—On right side, the ganglia and white matter look natural; on left side, a brownish-red coagulum occupies the position of the caudate nucleus. It is immediately beneath the floor of the lateral ventricle, the lining membrane of which is thickened at this spot. Below, it rests on the optic thalamus and internal capsule, the fibres of which, between the caudate and lenticular nuclei, are softened, and, in places, have a greyish, almost puriform appearance. . . .

Remarks

First, *the distribution of the lesion*. The degenerative

changes in the brain substance depend for their distribution upon the vessels. The large ganglia at the base of the brain are nourished by arteries which are given off from the main trunks of the circle of Willis. Of these the most important pass perpendicularly up from the first portion of the Sylvian arteries and supply the corpora striata and anterior part of thalami optici. These are divided into two sets by Duret—internal and external. Of the latter, some are anterior, others posterior. The former, named the lenticulo-striated, supply the external portion of lenticular ganglion, the upper and anterior part of the internal capsule, and the caudate nucleus. One artery of this set is large, and has been called by Charcot, "on account of its predominant rôle, in intra-encephalic haemorrhage," the artery of cerebral haemorrhage. Now in both of these cases it is the territory supplied by these vessels which is involved.<sup>41</sup>

Case 5

This case of a young man with temporary left hemispheric dysfunction prompted a discussion of possible origins:

Case III—Stricture, operation followed by high temperature—Temporary right-sided Hemiplegia, with Aphasia.

J.T., aged 33, civil engineer, admitted Sept. 5th, '79 under Dr. Roddick [Thomas George Roddick (1846-1923), professor of clinical surgery at the Montreal General Hospital; he studied with Lister at Edinburgh and introduced the Lister carbolic acid ritual in Montreal in 1877], with stricture of urethra. There is a history of venereal disease some years before—(patient says he had chancre at 12 years of age)—and the stricture is of old standing. . . .

Feb. 15th

This is a case of more than ordinary interest. There must have been some temporary interference with the speech center and also with the integrity of the motor tract. We cannot suppose this to have been due to any gross lesion of these parts, else the recovery would not have been so rapid, but more probably to some impairment of their functional activity owing to a deranged blood supply. In this view we suppose a small extravasation to have taken place, or a thrombus to have formed in some vessel, causing a slight lesion in the neighborhood of the anterior convolutions of the Island of Reil on the left side, not directly involving either the speech centre or the motor tract, but doing so indirectly or temporarily by pressure, or a collateral hyperaemia.

The hemiplegia may possibly have been caused by the rupture of a small vessel during the struggles attending the aetherization. In the discussion upon this paper a case was mentioned which occurred some years ago in this city, of an old man who was aetherized for a cataract operation. He seemed to "go off" nicely, and the extraction was made, but the patient could not be roused from the heavy soporose condition into which he had fallen, and died the same night. At the autopsy an apoplectic clot was found in the brain.<sup>41</sup>

Tumors: Illustrative Cases

Case 6

Osler published 10 case reports or editorials concerned with brain tumors. In the following case of an adolescent female patient with obvious hydrocephalus and a thalamic tumor, Osler discusses Virchow's previous description of brain tumors.

Josephine N—age 16, admitted to the Montreal General

## William Osler at McGill University

Hospital, under Dr. Ross [George Ross (1845–1892), professor of medicine at McGill University who was editor of the *Canada Medical and Surgical Journal*], 2<sup>nd</sup> Dec. 1879. . . .

Convolutions are flattened, and the sulci are almost obliterated. On separating the hemispheres the corpus callosum looks thin, particularly in its posterior half. Projecting from behind it is a large clear cyst, which lies upon the upper surface of the cerebellum. The lateral ventricles were then exposed and found to be enormously distended. So much fluid escaped in the manipulation of the organ that the total quantity could not be estimated, but it must have amounted to nearly a pint. . . . The brain substance of the hemispheres is much reduced. . . .

Lying upon the left thalamus opticus is a brownish yellow elevated mass, about 3 cm. in length, 2.5 cm. in breadth, extending over the choroid plexus towards the descending cornu. At the inner side it is attached to the fornix, beneath which it extends, and is continuous with a rounded greyish-white body in the third ventricle. The part on the thalamus is firm, and several yellowish-brown bands pass from it over the corpus striatum. The choroid plexus lies beneath its hinder part, and is closely adherent. On the surface are several small calcareous particles. The growth in the third ventricle, when fully exposed, is found to project from the upper part of the side of the thalamus, and to be continuous with the mass in the lateral ventricle. It occupies the anterior half of the third ventricle, touching the thalamus of the other side, and in front is closely united to the pillars of the fornix. It has a greyish colour, is soft, surface smooth, and altogether it has the appearance of a young, rapidly-growing neoplasm. On making an incision through the anterior part of the tumor, it is found to extend to the depth of about 8 mm., has a greyish brown translucent aspect, and though it appears to grow directly from the thalamus, yet the difference in the two is evident. . . .

Remarks.—The so-called medullary or ganglionic neuroma is perhaps the most uncommon form of tumour met with. So far as I can ascertain, no case has been reported in the British journals. The literature of the subject is fully given in Virchow's work on Tumours (French edition, vol. iii, p. 457). In most of the instances there referred to the new growth was in the lateral ventricles, and, as in the present case, in connection with hydrocephalus. In a few the growth was situated in the white substance of the centrum ovale. . . .<sup>24</sup>

As part of his histological examination, Osler created a drawing of the various cell types found in the thalamic glioma (Fig. 5).

### Case 7

This was a most remarkable case of a child with likely optic glioma.

L.P., aged 5 years, was admitted into the Montreal General Hospital, on the 10<sup>th</sup> of December, 1875, suffering from glioma of the retinae of both eyes.

History.—The father states that three years ago the child suffered from sore eyes. They were tender, red, slightly inflamed; had little specks or pimples on the sight, and there existed great difficulty in looking at the light. Very little was done for the child, except bathing the eyes with a wash that had been procured from an apothecary. This state of things continued. Last March the family removed to Rouses Point, and at this time the child was almost perfectly blind. . . .<sup>14</sup>

Osler completed a histological examination of the tumors and provided the following description.

The tumour of the right eye filled the whole orbit, and, on removal, presented a somewhat rounded mass about the size of a small orange. A meridional section, made through both eye

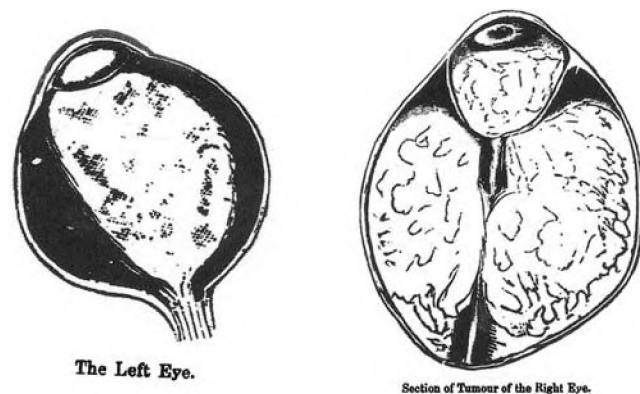


FIG. 6. Drawings illustrating tumor involving both orbits in a child. Reproduced from Fenwick GE, Case of glioma of both retinae. Extirpation of both eyes. *Can Med Surg J* 4:301–308, 1875/76.

and tumour, displayed a foreign growth filling up the former and extending above and posteriorly to the extent of about an inch in either direction. A tolerably firm capsule, strongly adherent to the tumour, enveloped the whole, and was at no point perforated. The eye-ball itself occupied the lower and anterior position, and quite half its mass projected beyond the tumour. Its limit was sharply defined by the sclerotic, which persisted as a pale white band, intimately united to the growth and much narrowed in certain localities. Posteriorly the eye-ball was of triangular shape, due to pressure of the tumour, the apex corresponding to the optic nerve.<sup>14</sup>

Osler drew the orbits with associated tumor (Fig. 6). Other case records of tumor include a description and detailed drawings of cholesterol crystals and cells associated with a cholesteatoma of the floor of the third ventricle (Fig. 7).<sup>23</sup>

## Trauma: Illustrative Case

### Case 8

Osler reported several cases of brain injury. The following abstract is one example.

C.G., aet. 22, was admitted to Hospital on March 8<sup>th</sup>, suffering from the effects of a bullet wound, situated above and a little in front of right ear. It was stated to have been caused by the accidental discharge of a pistol. When seen by Dr. Drake [J. Morley Drake (1828–1886), professor at the Institutes of Medicine, McGill University, whom Osler succeeded in 1875], shortly after the accident, he was perfectly conscious, not paralyzed, and gave a rational account of the whole affair. A probe was inserted into the wound, and it passed freely into the frontal lobe in the direction of the bullet. . . . After a residence of nearly three weeks in Hospital, symptoms of phthisis manifested themselves, and it was ascertained that he had previously suffered from haemoptysis, with cough, and occasional night sweats. He left the Hospital on the 27<sup>th</sup> of April with well-marked disease at apices of lungs, but with complete absence of any cerebral symptoms. The disease of the lungs having steadily progressed, he subsequently entered the Hotel-Dieu Hospital, and died on the 12<sup>th</sup> of August. . . .

The bullet entered the brain substance in the right inferior frontal convolution, just in front of the ascending branch of Sylvian fissure. From this point the course of the bullet was upwards and forwards, passing out at the inner surface of the frontal lobe and lodging between the brain substance and the

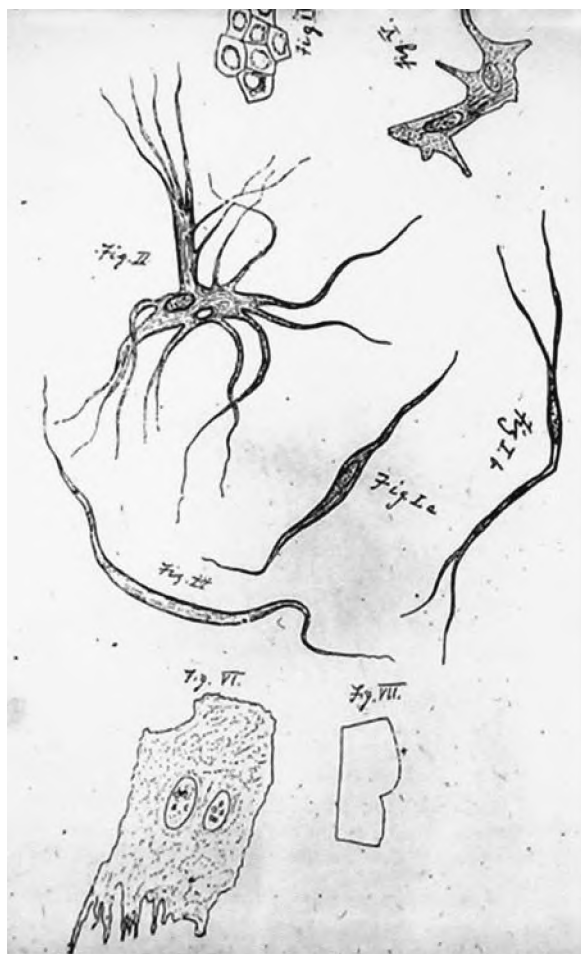


FIG. 7. Osler's sketches of cell types and characteristic cholesterol crystals from his case report of a cholesteatoma of the third ventricular floor. Reproduced from Osler W, *Bullet wound of the right frontal lobe—entire absence of cerebral symptoms. Montreal General Hospital Pathol Report 2:258–260, 1877/79.*

falx, where it lay surrounded by a firm membrane. It was situated 6 cm. in front of, and in a line with, the anterior extremity of the corpus callosum. A firm membranous canal marks the course of the bullet, and the brain substance about this is somewhat softened.<sup>21</sup>

### Infection: Illustrative Case

#### Case 9

At a meeting of the Medico-Chirurgical Society on December 14, 1883, Osler presented a description of extensive cerebrospinal tuberculosis:

Meninges of brain unaffected; central softening. Spinal meninges extensively involved. . . .

Brain, extremely soft, and with difficulty removed. Subarachnoid fluid in excess. Large veins of pia mater moderately full. Convolutions pale and flattened . . . On section of the hemispheres the brain substance is soft, moist, and glistening; puncta vasculosa indistinct. Lateral ventricles much dilated, and contain excess of fluid. The dilatation affects especially the posterior horns, which extend far back towards the cerebellum. The walls are excessively soft, and, for the most part, converted

into a reddish-white creamy substance, consisting of degenerating brain matter, blood corpuscles, and Gluge's cells. A gentle stream of water washes the layer off, leaving the parts beneath rough and irregular, and to the touch very friable. Septum lucidum soft, and on removal separated from the fornix. Velum interpositum and choroid plexuses pale, no lymph or tubercles. Walls of third ventricle soft, but intact, commissures uninjured. Corpora striata and thalami optici soft and moist; grey substance reddened.

The most careful examination failed to detect any tubercles either in the meninges or brain substance.

Spinal cord. On removal, the arachnoid stretching from the cerebellum is noticed to be opaque and granular. Laid upon the table the cord presents at the lower part slight irregularities and bulgings. The dura mater is thick and opaque; the arachnoid lining its inner surface is scattered over with numerous miliary tubercles, like grains of sand, very abundant in the dorsal and lumbar regions, less so in the cervical. As far as the lower part of the cervical enlargement the visceral arachnoid is clear and transparent, and the pia mater can be distinctly seen through it. From this point to the termination of the cord the arachnoid is opaque, and the sub-arachnoidal space filled with turbid lymph, the membrane over the centre of the lumbar enlargement being much distended. On exposing the pia mater a thin layer of yellowish-white lymph covers it in the dorsal and lumbar regions, becoming more abundant at the cauda equina, the filaments of which are surrounded by thick lymph as far as the termination of the sacral canal. On the lumbar enlargement is an isolated white mass, looking like an enlarged tubercle, attached to the pia mater, but on section the contents are soft, and like the lymph over the general surface. The vessels of the pia mater on the posterior part of the cord are full, on the anterior empty. Scattered over the membrane, chiefly along the course of, and about the vessels, are numerous miliary granulations, most abundant below the cervical enlargement, only a few being noticed above this point. The cord appears very tightly embraced by the pia mater, so much so that the surface looks wrinkled, and on puncturing it at the cervical enlargement, the white substance bulges out as a soft rounded mass.<sup>22</sup>

### Studies of the Brain and its Disorders

In the spring of 1878, Osler was appointed full physician to the Montreal General Hospital (Fig. 8), promoting him over several other faculty members who had much more clinical experience. He now had access to patients to collect data for teaching in addition to his pathological material. With his insatiable curiosity and boundless energy, he began publishing reports on a wide variety of medical conditions as well as veterinary subjects. Around this time he became particularly interested in the brain and its disorders. During a trip to England in 1878 where he successfully completed the examinations to become a Member of the Royal College of Physicians, he visited the National Hospital at Queen Square where he "began a long friendship with that brilliant ornament of British medicine, Gowers."<sup>16</sup> He also came to know Victor Horsley and was stimulated by his reading of Charcot's "Lectures on Localization in Diseases of the Brain."<sup>13</sup>

Osler was intrigued by the anatomy of the brain. At a meeting of the Canadian Medical Association in London, Ontario, during 1879, he described his use of Giacomini's process for preserving entire brains. At a meeting of the Medico-Chirurgical Society of Montreal that same year,<sup>34</sup> he also described Dalton's slicing apparatus, which enabled him to produce excellent coronal and transverse sections.

## William Osler at McGill University

A method by which brains could be permanently preserved as dry preparations has long been a desideratum to anatomists and physiologists. I should like, therefore, to call the attention of those interested in the subject to the following method devised by Prof. Giacomini, of Turin, and communicated to the Academy of Medicine in that city in 1878. A summary of his article, by Prof. Turner, appeared in the *Journal of Anatomy and Physiology* for January, 1879. I was struck with the description, and though somewhat sceptical, determined to give the process a trial. The results have greatly exceeded my expectations, and I am able to state that by this method the brain can be permanently prepared in the dry condition, retaining the external form and general character in such a way that it appears like a beautiful wax model. I exhibited a set of brains thus prepared, at the Saratoga meeting of the American Association for the Advancement of Science, and from the numerous letters which I have received from various quarters respecting the process, I feel sure that its publication in full will be satisfactory to many.<sup>34</sup>

This presentation was also described in the Society's proceedings.

Dr. Osler then proceeded to demonstrate by means of specimens and illustrative diagrams the chief points in the medical anatomy of the brain. Dr. Dalton's apparatus for slicing the entire brain was shown. By means of it the whole organ can be divided into 8 or 10 vertical or transverse sections, and the relations of the parts or of a focus of disease very accurately shown.

The interest of the evening centred in preparations of the entire brain made after a process of Giacomini's, of Turin, by means of which the organ retains its form and colour, is firm, can be handled, and looks like a beautiful wax model. The method is briefly as follows: Brain is put into solution of zinc chloride (about 50 p.c.), on second day remove membrane, turn in the fluid two or three times a day. At first it floats in the solution, but gradually sinks. Let it remain until it no longer sinks (ten or twelve days), then transfer to alcohol of commerce for ten days, after which it is immersed in glycerine of commerce with one per cent of carbolic acid added.<sup>11</sup>

In 1879 Moriz Benedikt<sup>6</sup> in Vienna proposed that the brains of criminals were deformed and thus contributed to a criminals' aberrant behavior. Osler examined 34 preserved normal brains from his material at the Montreal General Hospital and found that some demonstrated the same "abnormalities" in brain fissures that Benedikt had described as characteristic of criminals. He concluded that either Montreal harbored a highly indigenous criminal population or Benedikt had failed to examine normal brains adequately.

To further test this hypothesis Osler was able to procure the brains of two murderers who had been executed in the province of Quebec. In one case he personally attended the hanging of one Hugh Hayvern, who had committed a brutal murder, and persuaded the jail surgeon to give him the brain. In the second instance he sent a young medical student, H. V. Ogden, to Rimouski, Quebec, to procure without fail the brain of an individual named Moreau after his judicial hanging on January 13, 1881. Ogden was able to remove the brain and place it in his Gladstone bag to keep it cool during the trip back to Montreal where "W.O. expressed the greatest delight—but he did not give me a new Gladstone bag."<sup>15</sup> In a subsequent paper, "On the Brains of Criminals,"<sup>35</sup> Osler refuted Benedikt's hypothesis (Fig. 9). He wrote that "as society is at present constituted it cannot afford to have a class of criminal automata and to have every rascal pleading faulty grey matter in extenuation



FIG. 8. Photograph of William Osler (left), Francis J. Shepherd (1851–1929; professor of anatomy and surgery at McGill University; right), and George Ross (seated), the young professors at McGill, 1878. Reproduced courtesy of the Osler Library of the History of Medicine, McGill University, Montreal, Quebec, Canada.

of some crime." Subsequently, he further examined brains from other criminals to substantiate his conclusions that they harbored no specific underlying abnormality in gyral patterns (Fig. 10).<sup>38</sup>

### Osler's Influence on Neurosurgery, Neurology, and Their Practitioners

Sir William Osler became the great American physician of the late nineteenth and early twentieth centuries. He was an acknowledged pathologist, clinician, teacher, author, editor, and humanist. In his day he was the epitome of that unique individual who could practice the art and the science of medicine simultaneously. Although a "generalist,"<sup>37</sup> Osler had a special interest in neurology and neurosurgery.<sup>19,20,26,34</sup> Of his 1400 publications, nearly 200 relate to the nervous system including early observations of neurological disease.<sup>12</sup> From his extensive review of pathological material and the correlation of those data with the clinical observations in the patient before death, he developed an awareness of the focal nature of many neurological entities. These symmetries led inexorably in his mind to the possibilities of a surgical cure.<sup>36</sup> Osler's interest in the nervous system, begun at McGill (1870–1884), continued during his years

REPRINTED  
FROM THE  
"Canada Medical & Surgical Journal," Montreal.  
FEBRUARY, 1882.

## ON THE BRAINS OF CRIMINALS.

WITH A DESCRIPTION OF THE BRAINS OF TWO MURDERERS.

(PLATES I. AND II.)

By WILLIAM OSLER, M.D., M.R.C.P., LOND.  
Professor of the Institutes of Medicine in McGill University, and Physician  
to the Montreal General Hospital.

[Read before the Medico-Chirurgical Society of Montreal.]

Mentally and bodily, we are largely the result of an hereditary organization, and the environment in which we have been reared. The child of a bushman nurtured in the family of a philosopher will not be able, with favourable surroundings, to rise much above his race level; the child of a philosopher, reared among the bushmen, will not reach his paternal standard, but the grossness of the savage natures around him will have weight to pull him down, and what is fine will learn to sympathize with the clay. In the former case, the individual cannot transcend his organization; and in the latter, he cannot burst the iron bars of his environment. That the mental and moral status of a man is determined by the conformation and development of his brain is an axiom with the school of physiological psychologists. The conformation is a matter of inheritance; the development, of education (in its widest sense). The different mental conditions of individuals are the expression of subtle differences in cerebral structure, just as the diversity in the features of men is the result of minute variations in the arrangement of the tissues

FIG. 9. Photograph of the title page from Osler's "On the Brains of Criminals: With a Description of the Brains of Two Murderers." Reproduced courtesy of the Osler Library of the History of Medicine, McGill University, Montreal, Quebec, Canada.

in Philadelphia (1884–1889) and at Johns Hopkins (1889–1905). During his lifetime, he interacted with many of the foremost individuals in this area of medicine. He was a friend of Gowers and Horsley, a student of Marie and Charcot, a colleague and companion of Weir Mitchell and W. W. Keen, and a mentor to Cushing and Penfield.<sup>12,42</sup> During these varied interactions, Osler's influence was spread through the developing community of neurological physicians.

### Conclusions

Osler was a prodigious worker and a firm believer in publishing his astute observations. The detailed pathological records created at the Montreal General Hospital and much of his other work from his time at McGill University encompass many seminal observations on neurosurgical disease. These data also underscore Osler's formidable power of observation; his associated discussions regarding etiology would prove in many cases to be surprisingly accurate.

W. T. Couldwell, W. Feindel, and R. L. Rovit

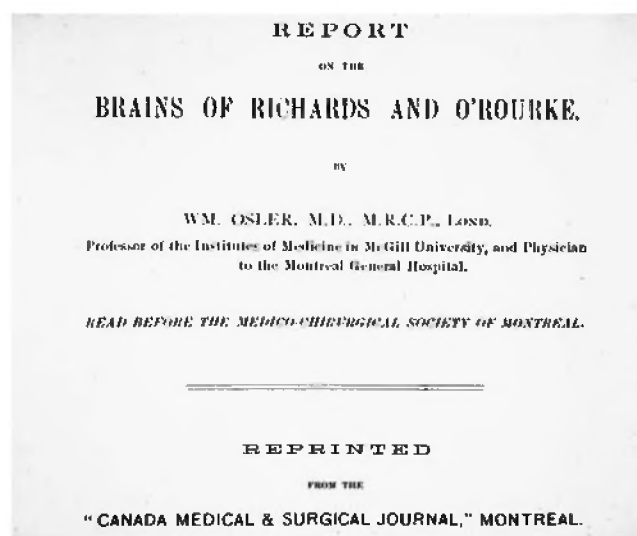


FIG. 10. Photograph of the title page from Osler's "Report on the Brains of Richards and O'Rourke." Reproduced courtesy of the Osler Library of the History of Medicine, McGill University, Montreal, Quebec, Canada.

### Acknowledgments

We thank Lily Szczygiel and Pamela Miller at the Osler Library of the History of Medicine, McGill University, for helping to collate the pathological case records reviewed in this report. We also thank Arlene Stolper Simon, New York Medical College, and Kristin Kraus, University of Utah, for superb editorial assistance.

### References

1. Abbott ME (ed): **Classified and Annotated References of Sir William Osler's Publications**, ed 2. Montreal: The Medical Museum, McGill University, 1939
2. Abbott ME: Osler's pathological collections and his literary output. *Can Med Assoc J* 42:284–288, 1940
3. Anonymous: Hospital report. *Can Med Surg J* 11:548–549, 1882/83
4. Anonymous: Society proceedings. Medico-Chirurgical Society of Montreal. *Can Med Surg J* 11:355–358, 1882/83
5. Bell J: A case of cerebral aneurysm. *Can Med Surg J* 5:56–58, 1876/77
6. Benedikt M: **Anatomical Studies upon Brains of Criminals: A Contribution to Anthropology, Medicine, Jurisprudence, and Psychology (Trans. Fowler EP)**. New York: Wm Wood & Co, 1881
7. Bliss M: **William Osler. A Life in Medicine**. Oxford: Oxford University Press, 1999
8. Canale DJ: William Osler and "the special field of neurological surgery." *J Neurosurg* 70:759–766, 1989
9. Cushing H: **The Life of Sir William Osler**. Oxford: Clarendon Press, 1925
10. Ebers GC: Osler and neurology. *Can J Neurol Sci* 12:236–242, 1985
11. Edwards OC: Proceedings of Societies. Chirurgical Society of Montreal—July 25. *Can Med Surg J* 8:16–17, 1879/80
12. Feindel W: Highlights of neurosurgery in Canada. *JAMA* 200:853–859, 1967
13. Feindel W: Osler and the "medico-chirurgical neurologists": Horsley, Cushing, and Penfield. *J Neurosurg* 99:188–199, 2003
14. Fenwick GE: Case of glioma of both retinae. Extirpation of both eyes. *Can Med Surg J* 4:301–308, 1875/76

## William Osler at McGill University

15. Ogden HV: Manuscript: "The murderer's brain." **P417 Harvey Cushing Fonds, CUS417/77.4**. Osler Library. McGill University. 1881
16. Osler W: An address on "The Medical Clinic." A retrospect and a forecast. **Br M J I**:10–16. 1914
17. Osler W: Aneurism of the cerebral arteries. **Can Med Surg J 14**: 660–666. 1885/86
18. Osler W: Berlin correspondence. **Can Med Surg J 2**:231–233. 308–315. 1873
19. Osler W: Book review of Charcot JM: *Lectures on Localization in Diseases of the Brain*. New York: Wood & Co. 1878. **Can Med Surg J 7**:409–410. 1878
20. Osler W: Book review of Mitchell. SW: *Lectures on Diseases of the Nervous System, Especially in Women, ed 2*. Philadelphia: Lea Bros. & Co. 1885. **Med News 47**:162. 1886
21. Osler W: Bullet wound of right frontal lobe—entire absence of cerebral symptoms. **Montreal General Hospital Pathol Report 2**: 258–260. 1877/79
22. Osler W: Case XVIII—small cavity and caseous masses in lung. General tuberculosis. Meninges of brain unaffected: central softening. Spinal meninges extensively involved. **Montreal General Hospital Pathol Report 1**:79–81. 1877
23. Osler W: Case of Cholesteatoma of the floor of the third ventricle and of the infundibulum. **J Nerv Ment Dis 14**:657–673. 1887
24. Osler W: Case of medullary neuroma of the brain. **J Anat Physiol 15**:217–225. 1880–81
25. Osler W: Catalogue of a series of specimens illustrative of the morbid anatomy of the brain and spinal cord. **Can Med Surg J 9**: 106–107. 1880/81
26. Osler W: **The Cerebral Palsies of Children: A Clinical Study From the Infirmary for Nervous Diseases, Philadelphia**. London: KR Lewis. 1889
27. Osler W: A contribution to Jacksonian epilepsy and the situation of the leg centre. **Am J Med Sci 89**:31–37. 1885
28. Osler W: Fibro-glioma of the upper end of the ascending frontal gyrus; Jacksonian epilepsy of fourteen years standing; the leg-centre. **Can Med Rec 12**:82–83. 1883/84
29. Osler W: Fragmentary notes. William Osler to Chattie. 23 Nov. 1873. **P417 Harvey Cushing Fonds, CUS417/69.33**. Osler Library. McGill University. 1873
30. Osler W: Glioma of the medulla oblongata. **J Nerv Ment Dis 15**: 172–175. 1888
31. Osler W: The growth of a profession. **Can Med Surg J 14**: 150–155. 1885
32. Osler W: Introductory remarks to, and synopsis of, practical course on institutes of medicine. **Can Med Surg J 4**:202–207. 1875
33. Osler W: Notes and comments on Gowers WR: *A Manual of Diseases of the Nervous System*. Philadelphia: Blakiston. 1888. **Can Med Surg J 16**:732–734. 1887/1888
34. Osler W: On Giacomini's method of preserving the brain. **Can J Med Sci 5**:125–127. 1880
35. Osler W: On the brains of criminals. With a description of the brains of two murderers. **Can Med Surg J 10**:385–398. 1881/82
36. Osler W: On the conditions of the brain suitable for operative interference. **Can Practitioner 14**:165–167. 1889
37. Osler W: **The Principles and Practice of Medicine: Designed for the use of Practitioners and Students of Medicine**. New York: D Appleton. 1892
38. Osler W: Report on the brains of Richards and O'Rourke. **Can Med Surg J 11**:461–466. 1882/83
39. Osler W: The VII International Medical Congress. London, August 10. 1881. **Can Med Surg J 10**:121–125. 1881
40. Osler W: The structure of certain gliomata. **Med Times 16**: 394–395. 1885/86
41. Osler WM: Three cases of brain disease. **Can Med Surg J 8**: 295–304. 346–349. 1879/80
42. Penfield W: William Osler, the man I remember. **Proc Charaka Club 12**:52–58. 1985

Manuscript received January 5, 2004.

Accepted in final form May 14, 2004.

Address reprint requests to: William T. Couldwell, M.D., Ph.D., Department of Neurosurgery, University of Utah, Suite 3B409, 30 North 1900 East, Salt Lake City, Utah 84132. email: William.couldwell@hsc.utah.edu.