

## Atlantoaxial transarticular screw fixation: a review of surgical indications, fusion rate, complications, and lessons learned in 191 adult patients

WAYNE M. GLUE, M.D., MEIC H. SCHMIDT, M.D., AND RONALD I. APFELBAUM, M.D.

Department of Neurosurgery, University of Utah Health Sciences Center, Salt Lake City, Utah

*Object.* In this, the first of two articles regarding C1–2 transarticular screw fixation, the authors assessed the rate of fusion, surgery-related complications, and lessons learned after C1–2 transarticular screw fixation in an adult patient series.

*Methods.* The authors retrospectively reviewed 191 consecutive patients (107 women and 84 men; mean age 49.7 years, range 17–90 years) in whom at least one C1–2 transarticular screw was placed. Overall 353 transarticular screws were placed for trauma (85 patients), rheumatoid arthritis (63 patients), congenital anomaly (26 patients), os odontoideum (four patients), neoplasm (eight patients), and chronic cervical instability (five patients). Among these, 67 transarticular screws were placed in 36 patients as part of an occipitocervical construct. Seventeen patients had undergone 24 posterior C1–2 fusion attempts prior to referral. The mean follow-up period was 15.2 months (range 0.1–106.3 months).

Fusion was achieved in 98% of cases followed to commencement of fusion or for at least 24 months. The mean duration until fusion was 9.5 months (range 3–48 months). Complications occurred in 32 patients. Most were minor; however, five patients suffered vertebral artery (VA) injury. One bilateral VA injury resulted in patient death. The others did not result in any permanent neurological sequelae.

*Conclusions.* Based on this series, the authors have learned important lessons that can improve outcomes and safety. These include techniques to improve screw-related patient positioning, development of optimal instrumentation, improved screw materials and design, and defining the role for stereotactic navigation. Atlantoaxial transarticular screw fixation is highly effective in achieving fusion, and the complication rate is low when performed by properly trained surgeons.

**KEY WORDS** • atlantoaxial junction • craniocervical junction • instability • transarticular screw fixation • fusion

**A**TLANTOAXIAL and craniocervical instability present unique challenges in spinal surgery. It can be difficult to achieve a balance between optimizing the chance for fusion and minimizing the risk to patients. The use of C1–2 transarticular screws to achieve this goal has been well documented in adult and pediatric populations.<sup>3,4,8,11,20,24,28,32</sup> First introduced by Magerl and Seeman,<sup>26</sup> the technique has since been refined to be less invasive while still achieving very high fusion rates. Previously, graft/wire constructs were reported to be associated with a nonunion rate as high as 30% for C1–2 fusion; however, this incidence improves considerably with the use of a halo orthosis.<sup>5,10,12,15,18</sup> Transarticular screw placement creates immediate atlantoaxial joint stability and, in contrast to previous posterior wiring/graft constructs, does not require postsurgical brace therapy. The procedure requires surgical precision because serious potential risks are associated with improper screw placement. Thus, despite the very high fu-

sion rate and low associated complication rate reported in the literature, many spine surgeons are reluctant to perform this procedure.

Our overall experience in performing C1–2 transarticular screw fixation encompasses 480 screws placed in 258 patients between May 1991 and December 2003. Our experience in the pediatric population involves 67 patients younger than 16 years of age is presented as a companion paper in the following article.<sup>17</sup> In the present report we discuss our experience in 191 adult patients (> 17 years of age) in whom at least one transarticular screw was placed. In 187 patients an autologous iliac crest bone graft was placed and in four patients a bicortical iliac crest allograft was placed and secured using multistranded titanium cable. Surgery-related indications, rates of fusion and complications, and the lessons learned are discussed.

### Clinical Material and Methods

#### Patient Population

We retrospectively reviewed data obtained in 191 con-

Abbreviations used in this paper: AVF = arteriovenous fistula; CT = computerized tomography; RA = rheumatoid arthritis; VA = vertebral artery; 3D = three-dimensional.

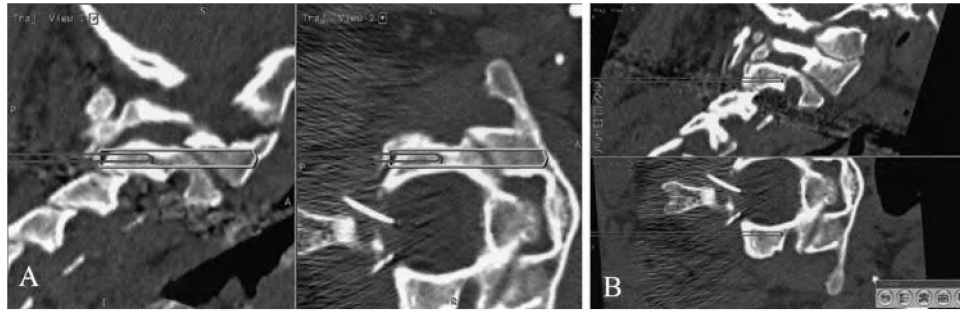


FIG. 1. Reformatted CT scans in the multiple planes of the proposed screw placement are used to ensure that a safe pathway exists. A: A safe trajectory is demonstrated for placement of a 4-mm transarticular screw. B: Stereotactic workstation images of the contralateral side in same patient demonstrated a very large VA foramen, which prevented safe screw trajectory.

secutive patients (107 women and 84 men) in whom at least one transarticular screw was placed. One hundred eighty-seven patients underwent surgery at the University of Utah Health Sciences Center between May 1991 and October 2003; the procedures were performed by five different surgeons, and in an additional four patients the senior author (R.I.A.) performed the surgery at other institutions while teaching the technique. The senior author directly participated in the surgery of 175 of the 191 patients in this series. Atlantoaxial or craniocervical instability was documented prior to surgery, or patients were scheduled for transoral odontoidectomy and required C1–2 stabilization as a result of this procedure.<sup>9,14</sup> Patients who underwent C1–2 or occipitocervical fusions that did not include transarticular screw placement were not included in this study.

#### Radiographic Studies

All patients underwent plain radiography and fine-cut, multiplanar reformatted CT scanning prior to surgery. Either CT workstation reformatting or stereotactic computer navigation with 3D modeling was performed in all cases to determine the feasibility of transarticular screw placement. Reformatted CT scans obtained in the direct plane of the screw trajectory were used to determine whether a screw could be safely placed in each case (Fig. 1). Attention was paid to bone anatomy and quality, the course of the VA, and other pathological entities that could preclude screw placement.

In the immediate postoperative period (postoperative Day 1 or 2), all patients underwent both anteroposterior/lateral plain radiography and a fine-cut, reformatted CT scanning to assess screw placement. Patients were then followed on an outpatient basis until fusion occurred. Fusion was defined by a lack of motion on flexion–extension plain radiographs and bridging trabecular bone between the graft and C-1 and C-2 on plain x-ray films or thin-section CT scans.

In general, no cervical orthosis was used in the postoperative period, unless bone quality was determined to be particularly poor intraoperatively. When this was the case, a rigid cervical collar (nine patients) or a halo vest (12 patients) was used.

#### Surgical Technique

The following is an outline of our method of C1–2

transarticular screw fixation.<sup>1,2</sup> The patient is positioned prone on the operative table on padded gel rolls (Fig. 2A). The cranium is held in a Mayfield three-point pin fixation device. The cervical spine is positioned for fracture reduction while simultaneously ensuring that a trajectory for transarticular screw placement is attainable. This requires a neutral head position, extension of the lower cervical spine with flexion, and posterior translation of the skull and C-1 in a “military tuck” position (Fig. 2B). The upper cervical spine cannot be extended because this would prevent the surgeon from establishing a manageable screw trajectory. The operative table is positioned with the back up, the legs up, and in reverse Trendelenburg to optimize the surgical trajectory while drilling, tapping, and placing the transarticular screws. The patient positioning is done using lateral fluoroscopic imaging to confirm the desired alignment prior to connecting the Mayfield head holder system rigidly to the table. A long, straight instrument is then placed alongside the C1–2 region in the desired screw trajectory to ensure that the positioning allows for drilling, tapping, and screw placement. If necessary, minor adjustments are made that allow for the desired trajectory. A small midline area is shaved to expose the inferior occipital region down to C-3, and a standard surgical preparation and draping are then performed.

Exposure of the occiput through C-3 is performed in a subperiosteal fashion. The C2–3 interspinous ligament is preserved. The soft tissue intervening between the occiput–C1 and C1–2 is carefully removed to the level of the dura mater. The superior, inferior, and anterior aspects of the posterior C-1 ring are clearly delineated with curettes to prepare for later passage of the multistranded titanium cable. The C-2 pars interarticularis must be clearly defined prior to initiation of drilling (Fig. 3). Dissecting this structure subperiosteally defines it well and reduces bleeding. A line in the plane of the medial border of the pars is drawn on the C-2 lamina by using a sterile marking pen to assist with trajectory guidance in the mediolateral plane. Medial to this line is the spinal canal. The entry sites for the percutaneous drill guides are determined by placing a long drill bit or other straight instrument alongside the patient and aligning it fluoroscopically to the desired trajectory. Marking the midline on the drapes from the inferior end of the incision to the midthoracic region is also helpful for orienting the drill guide. After the skin is

## Atlantoaxial transarticular screw fixation

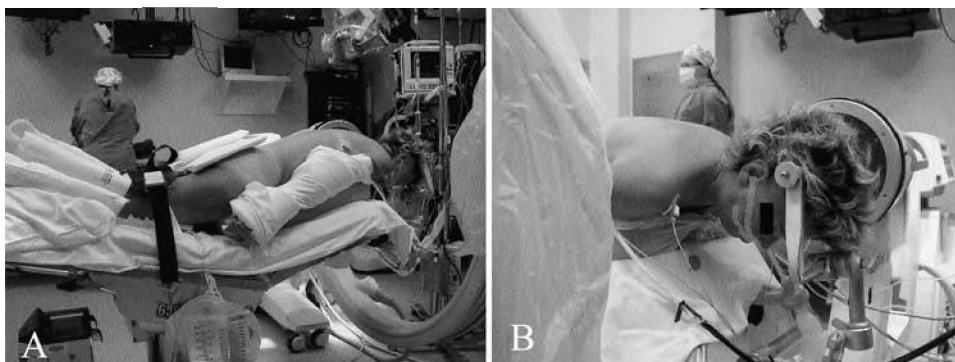


FIG. 2. Photographs showing patient positioning. A: The back and legs of the surgical table are elevated, and slight Trendelenburg is used to optimize trajectory. B: The patient is in a military tuck position with the lower cervical spine in slight extension, the upper cervical spine and occiput in neutral or slight flexion, and the head translated posteriorly.

incised at the drill guide entry site, the deep fascial layer must be opened prior to the passage of the drill guide.

Once the drill guide is in place, an awl is used to create a starter hole in C-2 at the desired entry site for drilling of the transarticular screws. A typical starting point is approximately 2 to 3 mm lateral to the medial edge of the ipsilateral C-2 pars interarticularis and 2 to 3 mm superior to the C2–3 facet joint. The actual starting point in the sagittal plane is best determined on the lateral fluoroscopic image, in a path that will follow the presurgical plan. Near-continuous lateral fluoroscopy is used while the screw path is drilled. It is essential to drill as dorsally and medially as possible within the pars interarticularis to minimize potential injury to the VA. We place a Penfield No. 4 dissector on the center of the dorsum of the pars, and use this as an aiming guide while drilling is performed under fluoroscopic guidance. Ideally, the drill will skive immediately below this instrument while drilling the screw trajectory (Fig. 4). Prior to proceeding, we save the fluoroscopic image and transfer it to the reference fluoroscopy screen. Comparing the live image with this stored image ensures that the tap and screw follow exactly in the drilled pathway. After drilling to the anterior cortex of C-1, we tap the hole and place the screw. The procedure is repeated on the contralateral side if the anatomy allows.

An autologous iliac crest allograft is then harvested, and the exposed bone on C-1 and C-2 is decorticated prior to graft placement. The graft is carefully fashioned to fit precisely to the prepared posterior and inferior surface of C-1. It is notched to allow contact with both of these surfaces and should fit in contact with them creating minimal gapping. The graft is also notched in an inverted “V” shape inferiorly to straddle the C-2 spinous process and contacts both this structure and the lamina (Fig. 5). The graft is held in place with a titanium cable (Dickman and Sonntag technique<sup>12</sup>) and tensioned appropriately. In cases of normal bone quality, we apply 30 in-lb of tension, but if at the time of surgery the bone is considered to be of poor quality, less tension is used. Multilayered closure is performed in the standard fashion. No external orthosis is used after surgery unless the patient’s bone quality is very poor. In such cases, consideration is given to placing a hard cervical collar or even a halo.

## Results

One hundred ninety-one consecutive patients underwent placement of one or more C1–2 transarticular screws between May 1991 and October 2003. Indications for surgery included trauma in 85 patients (44.5%), RA in 63 (33%), congenital anomaly in 26 (13.6%), os odontoidem in four (2.1%), neoplasm in eight (4.2%), and chronic nontraumatic instability in five patients (2.6%). Seventeen patients (8.9%) had undergone a total of 24 posterior cervical C1–2 fusion attempts before being referred to our medical center. Twenty-three patients (12%) underwent a transoral odontoidectomy for either RA (15 patients), congenital anomaly (six patients), or neoplasm (two patients) immediately prior to posterior fusion. In patients requiring transoral odontoidectomy, a posterior fusion was then performed in the same sitting after induction of general anesthesia. Thirteen patients required C1–2 fusion and 10 patients required occiput–C2 fusions after completion of the transoral procedure.

The mean age at time of surgery was 49.7 years (range 17–90 years) and the mean follow-up period was 15.2 months (range 0.1–106.3 months). Clinical and operative data are summarized in Table 1.

### Follow-Up Study

One hundred thirty-seven patients were followed until fusion was achieved or for a minimum of 24 months postoperatively. In this subset of patients fusion was achieved in 134 (98%) during a mean follow-up duration of 20.3 months (range 3–106 months). The mean time to fusion was 9.5 months (range 3–48 months). Three patients died during the postoperative period (< 30 days): one patient suffered a fatal bilateral VA injury, one patient died of a pulmonary embolism on postoperative Day 7, and one died of tumor burden of diffusely metastatic disease. Thirty patients were lost to follow up prior to documentation of solid fusion, and in 22 patients who have been followed for less than 24 months the fusion mass is progressing toward complete arthrodesis.

### Surgery-Related Complications

Table 2 provides a summary of surgery-related compli-

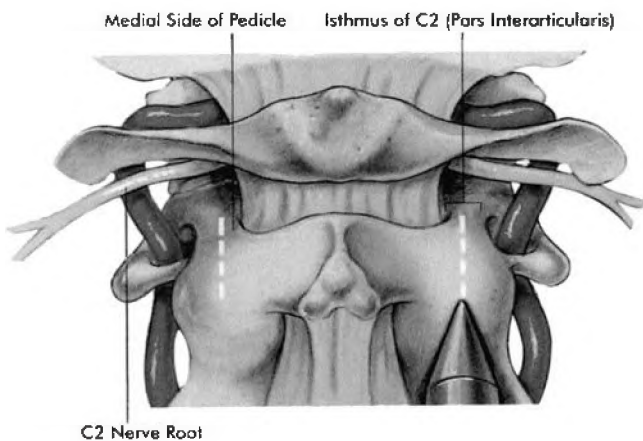


FIG. 3. Illustration. The C-2 pars interarticularis is the key landmark for safe passage of C1–2 transarticular screws. Note the relationship to the adjacent structures. The desired screw pathway is indicated by the dashed line.

cations, which occurred in 32 (16.8%) of 191 cases. Most complications were minor; however, there were six VA injuries (1.7%) in five patients in the overall series in which 353 consecutive transarticular screws were placed. One bilateral VA injury resulted in the patient's death; the others did not result in any permanent neurological sequelae. In two patients who suffered a VA injury an AVF developed. Both patients underwent endovascular occlusion of the VA and neither suffered a neurological complication as a result of the fistula or its treatment. All VA injuries occurred in the first one third of the cases treated in this series (between April 1992 and March 1996). The procedure for C1–2 transarticular screw placement, as with many complex surgeries having a "steep learning curve," experience leads to better patient outcomes and reduced morbidity.

Screw fracture occurred in nine (6.5%) of the first 138

screws placed. Because we switched to a new thicker-core screw, no breakage has occurred in 215 consecutively placed screws. Poor screw trajectory was defined as the requirement for repeated operation for screw repositioning. All of our repeated operations occurred within the first half of this series. Of two cases in which cerebrospinal fluid leakage occurred, neither was a direct result of drilling, tapping, or transarticular screw placement. Therefore, of the 32 complications 19 (59%) occurred as a direct result of transarticular screw placement.

## Discussion

### *Treatment of Atlantoaxial and/or Occipitocervical Instability*

Atlantoaxial instability has historically been treated using various posterior C1–2 autologous graft/wiring techniques. The Gallie,<sup>16</sup> Brooks–Jenkins,<sup>5</sup> and Sonntag–Dickman<sup>12</sup> approaches have been most commonly used. Gallie's technique for posterior graft/wire fusion was briefly described in 1939.<sup>16</sup> This method involved placing an onlay graft from the C-1 ring to the C-2 lamina, and securing it with a midline wire. Fielding, et al.,<sup>15</sup> reported their experience with 46 Gallie-type fusions for atlantoaxial instability in 1976. Their fusion rate after 10 to 14 days of postoperative skeletal traction and long-term Minerva jacket or halo therapy was 93%. Brooks and Jenkins<sup>5</sup> introduced the wedge compression technique for atlantoaxial arthrodesis in 1978. Their technique involved the placement of two trapezoidal interposition grafts between C-1 and C-2, one on either side of the spinous process. The grafts were secured and placed under compression by using two wires per interposition graft. Their initial work in 14 patients resulted in solid fusion in 12 cases (86%), nonunion in one, and one death of unknown cause 8 weeks after surgery. Each patient was placed in either a Minerva jacket or other rigid orthosis after surgery. Griswold, et al.,<sup>18</sup>

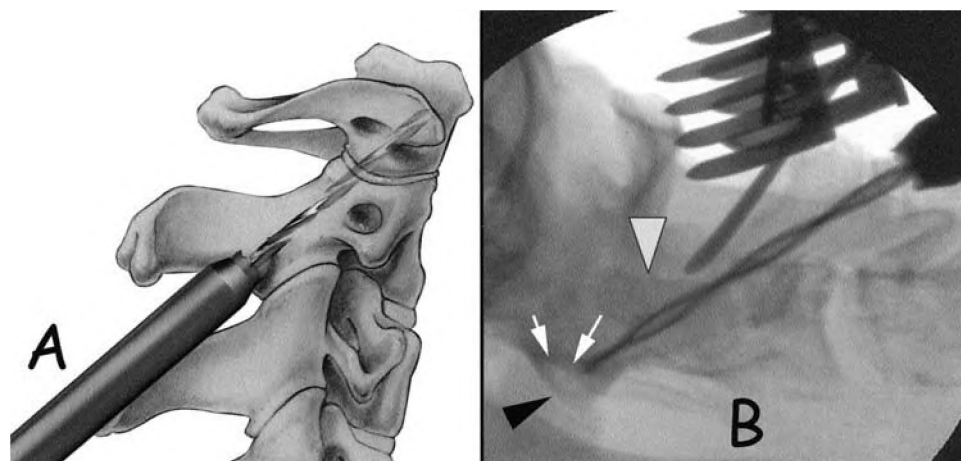


FIG. 4. Artist's illustration. A: The drill bit is placed through the drill guide tube and a pilot hole is drilled under fluoroscopic visualization through the C-2 pars, across the C1–2 lateral mass articulation, and into the anterior cortex of the lateral mass of C-1 (white arrows in B). B: Fluoroscopic image showing a Penfield No. 4 dissector on the dorsal surface of the C-2 pars, where it serves as a landmark as the drill is advanced. The drill should pass immediately below this instrument and is usually aimed at the upper half of the C-1 anterior arch (black arrowhead). It ideally crosses the C1–2 joint (white arrowhead) near its midsection.

## Atlantoaxial transarticular screw fixation

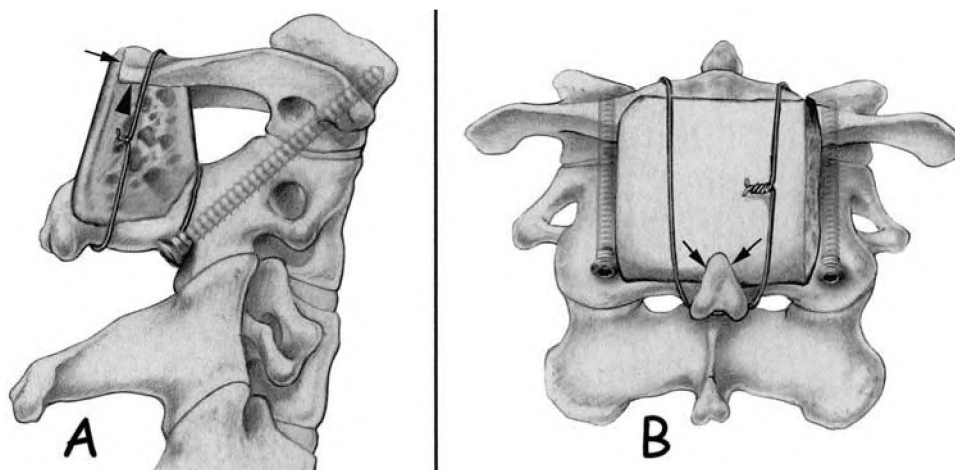


FIG. 5. Illustrations. Lateral (A) and posterior (B) views of the bone graft and cable construct. The superior edge of the bone is notched to fit snugly against both the posterior surface (*arrow*) and inferior surface (*arrowhead*) of the C-1 posterior ring as seen in A. A V-shaped notch is also cut in the inferior edge of the bone graft to fit over the spinous process of C-2 (*arrows* in B).

performed 11 Gallie-type and 30 Brooks-type fusions for atlantoaxial instability. There was a 60% fusion rate in the Gallie group after the first operation, with fusion occurring in an additional 20% after a second Gallie procedure. All patients were treated with long-term postsurgical rigid orthosis (mean duration 6.5 months). A 96% fusion rate was achieved in the 30 patients in whom a Brooks-Jenkins C1-2 fusion was performed. Postoperatively, all patients were fitted with a neck brace augmented by a molded plastic occipital support that extended down to the midthoracic region. Dickman and colleagues<sup>12</sup> introduced their C1-2 interspinous fusion method in 1991. In this procedure, the so-called Dickman-Sonntag technique, a single interposition graft is placed between the C-1 and C-2 laminae. It is held in place and compression is applied to the graft by using a looped wire. With this method, the authors reported a 97% fusion rate (osseous union in 31 patients and fibrous union in three) in 35 surviving patients. All patients underwent halo immobilization for 12 weeks after surgery and 4 to 6 weeks of Philadelphia collar therapy thereafter. Dickman, et al.,<sup>10</sup> and others<sup>21</sup> reported their findings in a biomechanical comparison of two variants of the Gallie-type fusion technique with the Brooks-Jenkins and interspinous methods. The Brooks-Jenkins and interspinous constructs were superior to the Gallie methods, with the former slightly superior to the interspinous method in terms of lateral bending. The authors recommended that each of these techniques be augmented by postsurgical rigid orthosis to maximize fusion results. Magerl's C1-2 transarticular screw fixation<sup>20</sup> functions as an internal fixator that achieves significant immediate stability of the C1-2 joint complex. When transarticular screw fixation is used in conjunction with an autologous bone graft and cable construct, it results in the highest fusion rate. The transarticular screw traverses four cortical surfaces and fixes the two vertebrae anteriorly and posteriorly, which eliminates translational motion and rotatory motion. The cable prevents flexion and the interposed graft prevents extension. Thus, all motion is prevented, providing strong immediate stability and an opti-

mal milieu for bone graft incorporation. The construct is biomechanically superior to posterior graft-and-wire-augmented procedures, and it therefore allows for omission of a postsurgical orthosis.<sup>19,22</sup>

The placement of C1-2 transarticular screws is not without potential risks. In addition to a thorough understanding of the surgical technique, careful and thorough preoperative planning is mandatory for optimal safety and success. In our series, malpositioned screws were noted in five (1.4%) of 353 screws, and six VA injuries (1.7%) in 353 screws were identified. Hardware failure, which can occur before bone fusion develops if the latter is delayed, has now been eliminated in our series by the use of a non-cannulated 4-mm-outer-diameter/2.9-mm-inner-diameter cortically threaded titanium alloy screw developed by Aesculap for the senior author (RI Apfelbaum, unpublished poster presentation).

Our fusion rate of 98% is similar to that reported in other series involving this procedure. Dickman and Sonntag<sup>11</sup> reported a 98% fusion rate in 121 patients in whom C1-2 transarticular screws were placed for atlantoaxial instability. Haid, et al.,<sup>20</sup> documented fusion in 96% of 75 patients receiving C1-2 transarticular screws. Approximately one third of the patients in our series have RA, which presents a multitude of challenges to the spine surgeon. The significantly increased fusion rate compared with conventional posterior graft/wiring constructs in the absence of a need for postsurgical bracing, which is especially difficult and creates major functional problems in these impaired patients, makes this technique superior for direct C1-2 instability in patients with RA.<sup>6,13,28,31</sup>

The VA injury rate (1.7%) and the malpositioned screw rate (1.4%) in our series favorably compare with those of other series involving this technique. Madawi, et al.,<sup>25</sup> cited an 8% per patient VA injury rate and a 14% incidence of malpositioned screws in 61 patients who underwent C1-2 transarticular screw fixation. Grob, et al.,<sup>19</sup> reported a 15% screw malposition rate and a VA injury rate of 0% in 161 patients. Dickman and Sonntag<sup>11</sup> reported

five malpositioned screws (2%) and one VA occlusion (0.4%) in 226 C1–2 transarticular screw placements. Haid, et al.,<sup>20</sup> reported no incidence of malpositioned screws or VA injury in their 6-year experience involving the placement of 141 C1–2 transarticular screws in 75 consecutive patients. Wright and Laurysen<sup>33</sup> surveyed 847 active members of the American Association of Neurological Surgeons/Congress of Neurological Surgeons Section on Disorders of the Spine and Peripheral Nerves regarding VA injury in C1–2 transarticular screw fixation. One hundred one surgeons reported placing 2949 C1–2 transarticular screws in 1318 patients. The confirmed VA injury rate in this collective group of experienced surgeons was 4.1% per patient or 2.2% per screw placed. There was an additional 0.8% rate of suspected, but unconfirmed, VA injury per screw placed in this study.<sup>33</sup>

Vertebral artery injury usually presents with brisk bleeding from the screw hole in excess of that which would be expected from bone bleeding, but it is not usually pulsatile bleeding. When this has occurred, we have opted for placement of the screw, because we believe that once the vessel is injured it is unlikely to be salvageable. The screw placement resolves the bleeding, which might be problematic if unchecked, because it is in a location that is not readily accessible. Also in this manner, at least one-sided fixation can be achieved.<sup>30</sup> If a suspected injury occurs, the second screw should not be placed. We perform an angiography, CT angiography, or MR angiography study after any suspected injury. These have allowed us to detect the two asymptomatic AVFs in our series that occurred at the site at which the screw injured the VA. In both cases, the artery was occluded distal to the screw. The AVFs were easily occluded endovascularly, preventing the type of complication that Coric, et al.,<sup>7</sup> reported that resulted in delayed-onset myelopathy due to distended arterialized epidural veins. Neither of our patients with this problem suffered any neurological sequelae.

The risk of VA injury is minimized when one obtains multiplanar reformatted CT scans. We have found that by studying these images and using oblique reconstructions, the number of patients in whom screws cannot be placed, at least unilaterally, is reduced and the number of bilateral screws can be increased. In our series, 29 patients (15%) received only one transarticular screw because the anatomy on the side contralateral to the first screw placement was incompatible. Madawi, et al.,<sup>25</sup> cited a 20% rate of unacceptable anatomy for screw placement. Paramore, et al.,<sup>27</sup> reported that in as many as 23% of patients a transarticular screw cannot be accommodated because of anatomical constraints.

#### Lessons Learned

As our experience has broadened, we have identified several key points that we believe improve patient safety and outcomes while simultaneously improving operative efficiency.

**Patient Positioning.** Atlantoaxial instability is typically best reduced in extension. This position, however, would require such a shallow screw trajectory that screw placement would be impossible. To achieve the desired trajectory without excessively flexing the patient's neck, a mil-

TABLE 1  
Data obtained in 191 patients in whom one or more transarticular screws was placed

Op Indication	No. of Patients	No. of Screws	Mean Age (yrs)	Mean Mos to Fusion
trauma	85	161	47.2	7.1
RA	63	112	58.0	12.3
congenital anomaly	26	48	34.6	10.0
os odontoideum	4	8	37.0	9.5
neoplasm	8	14	55.7	7.0
chronic instability	5	10	64.0	14.4
total	191	353	49.7	9.5

itary tuck posture is effected. The patient is placed in rigid Mayfield three-point fixation and the cervical spine is positioned by applying axial traction and then translating the head posteriorly with only minimal flexion, if needed. This typically extends the inferior cervical spine and holds the superior cervical spine in a neutral or slightly flexed but nearly reduced position. The positioning of the operative table (Fig. 2A) allows for surgical access even in patients in whom the anatomy is very challenging. Final anatomical reduction can be achieved intraoperatively by grasping the C-2 spinous process with a towel clamp and translating C-2 anteriorly or posteriorly. After C1–2 screw placement, the head position should be readjusted by repositioning the Mayfield table clamp if the fusion is to be extended up to the occiput, because fixing the head with posterior translation may result in swallowing difficulty.

**Screw Material.** Early in this series (in the treatment of 69 cases), stainless steel and then titanium alloy screws were used. These were 4-mm-outer-diameter and 1.9-mm-inner-diameter screws with a cancellous thread. Screw fracture was noted in nine (6.5%) of 138 screws. The design was changed such that a 4-mm-outer-diameter and 2.9-mm-inner-diameter cortically threaded screw was created. The thinner-core, cortically threaded screws are designed to resist pullout, although this is not a major force on the screws in this construct. The screws are primarily subjected to bending forces. The thicker minor-diameter screws have less thread depth but are much stronger with regard to bending (RI Apfelbaum, unpublished poster presentation). Since we changed to the new screws, no screw failure has occurred in 215 screws consecutively placed in this adult population. All of the screws we use are non-cannulated because we do not use a K-wire in the performance of this surgery.

**Development of Surgical Instruments.** Magerl's initial technique<sup>26</sup> required exposing the spine from C-1 to T-2. We have developed an instrument set that uses a percutaneously introduced guide tube placed from about the T-2 to the C-2 lamina.<sup>1,2</sup> This allows a minimally invasive approach and the surgical exposure is limited to the inferior occiput to the C2–3 junction. The instrument sets have been refined over the years to produce devices that allow for optimum drilling, tapping, and screw placement. We use a version of the guide tube fitted with a tracking device to allow for stereotactic registration and real-time tracking. The refinements have included making the instruments long enough to accommodate virtually any patient body habitus, adding retractable splines to the

## Atlantoaxial transarticular screw fixation

TABLE 2  
Summary of surgery-related complications

Complication	No. of Patients
poor screw trajectory	5
screw fracture	9
wound infection	4
requiring reop	2
nonop management	2
VA injury	5
AVF	2
CSF leak	2
graft site hernia (pelvis)	2
graft site fracture (pelvis)	2
pulmonary embolism	1
metastatic disease fatality	1
intraventricular hemorrhage	1
total	32

screwdriver that securely engage the screwhead while the screw is placed through the drill guide and using a 3-mm drill held securely in the drill guide. The latter improvement allows for excellent directional authority when drilling so that small changes in the drilling trajectory, by redirecting the drill, are easily accomplished to allow very precise screw placement. A balldriver is also available for final screw tightening. This instrument allows for up to 30° angulation between the screwdriver trajectory and that of the screw. It delivers excellent driving force to place the screw securely and allows access to the screw through the surgical site.

**Graft.** An autologous iliac crest bone graft is harvested in virtually all cases. Recently in four patients with very poor bone quality noted at time of surgery, bicortical iliac crest allograft bone was used. The bone is cut to fit very snugly at the C-2 spinous process–lamina junction, which requires an angled cut, with tapered walls. Historically, the graft–C1 interface is the most common site for nonunion. With this in mind, the graft is notched for a very tight press fit onto the C-1 ring, which has been drilled flat where the graft contacts it. The C-1 and C-2 posterior elements are decorticated prior to placement of the graft. The graft is secured in position with a multistranded titanium cable tensioned to 30 in-lb, or a lesser value when there is poor bone quality.

**Stereotaxy.** We use the Stealth Treon System (SNT Division of Medtronic Sofamor Danek, Louisville, CO) to construct a 3D model prior to surgery. From the careful analysis of this model and using two orthogonal “trajectory views” along the proposed screw pathway, we determine the feasibility of a transarticular placement. Various proposed screw paths can be tested to determine whether a screw can be safely placed. This often allows us to find a safe pathway when it initially appears from study of the regular CT scans that none exists. By adjusting the screw plan diameter, the safe diameter of the proposed pathway can also be determined during the preoperative analysis.

Although we frequently register and attempt to use stereotactic guidance at surgery, we often find the accuracy insufficient to navigate with confidence. This is primarily due to constraints imposed by the tracking devices on C-2 and the inherent registration limitations produced when the accessible registration points are all posterior

and nearly coplanar. Sufficient navigation error can result, precluding navigation in real time when drilling the screw trajectory; however, the knowledge of a safe trajectory gained from the preoperative planning as well as the depiction of this trajectory and the entrance site on the 3D model are very helpful in executing the safe screw placement, even when actual guidance is not used. In all cases, fluoroscopy is used when drilling, tapping, and placing the transarticular screws. Whenever a conflict exists between the information derived from stereotactic navigation and that directly observed and obtained on fluoroscopy, it is best to use the direct visualization and fluoroscopy rather than the stereotactically derived information. The goal of stereotaxy is to assist in safe navigation through the C-2 pars interarticularis. For that reason, C-2, which is very mobile, must be tracked. It is not adequate to track the region from C-1 or the skull headholder. Once the screw is placed to the C1–2 joint, the alignment is corrected using fluoroscopy and the drill is advanced solely under fluoroscopic control to the anterior surface of C-1.

Future advances in this technique will likely include significant improvements in the area of stereotactic navigation. Improvements in registration are being developed that will enable surgeons to navigate with much greater confidence. Advances in image guidance, however, will never supplant intimate familiarity with the intraoperative anatomy and technique.

**Screw Placement on the Best Side First.** After analysis of preoperative screw trajectories, the “best side” is selected for placement of the first transarticular screw. The best side refers to the side in which a screw can most easily and safely be placed. Assuming the screw on this side is placed without VA injury, the second, more difficult screw trajectory can then be performed if it is determined that it can accommodate a transarticular screw. Should a VA injury occur or be suspected with this more difficult second screw, it would result in a unilateral injury and bilateral fixation would still have been accomplished. Conversely, if placement of the screw on the more difficult side is attempted first and results in a VA injury, placement of a second screw should not be attempted. This failure to place both screws might result in reduced stability and require postsurgical immobilization.

**Fluoroscopy.** The use of fluoroscopy in the safe performance of this procedure is essential. The fluoroscope is positioned to provide a magnified lateral view of the C1–2 region and left in place for the entire procedure. It is used to confirm positioning, anatomical reduction, and the attainable trajectory for drilling, tapping, and placing the screws. The facet joints and mandible are carefully aligned to ensure a true lateral view and to minimize possible error. When drilling and tapping, it is helpful to place a Penfield No. 4 dissector on the posterior-most aspect of the C-2 pars interarticularis, centered left to right. This instrument serves as an aiming device visually for the mediolateral trajectory and fluoroscopically by using the lateral fluoroscopic image for the craniocaudal trajectory. The ideal trajectory is to remain as posterior and usually either centered or as medial as possible within the pars, skiving immediately beneath the Penfield No. 4 dissector when viewed on the lateral image.

**Occipitocervical Fusion.** Atlantoaxial transarticular

screws were placed as part of an occipitocervical construct in 36 patients in our series. During patient positioning, it is critical to ensure that the patient's head is in the neutral position when fusing to the occiput. If the patient is placed in too much extension or flexion, it may pose a safety hazard when ambulating or create dysphagia when eating. When performing an occipitocervical fusion, the C1–2 transarticular screws are placed first using the technique described in this paper. After transarticular screw placement, the Mayfield headholder may be loosened, if necessary, to achieve final optimal skull position.

The OMI U-Loop<sup>29</sup> (Ohio Medical Instruments, Inc., Cincinnati, OH) was used in 26 of the 36 occipitocervical cases. In each of these cases, a special coupling device, developed by the senior author (R.I.A.), was used to connect the transarticular screw to the OMI loop. The OMI U-Loop is no longer commercially available, however, so other instrumentation must be used. We favored the OMI U-Loop because it allowed the use of our preferred 4-mm transarticular screw, mated to the OMI U-Loop via this coupling device through which the screw was passed. After the titanium loop was bent to fit securely to the occiput and into the couplers, the system was secured using two nuts at the couplers and three screws in the occiput. A multi-stranded titanium cable was placed around the vertical rod portion of the loop and tensioned to fix the autologous graft securely to the occiput, C-1, and C-2. The occipital screw holes were positioned such that a long central screw would engage the midline "keel" of the occipital bone, and two equally offset screw holes would each accept a shorter bicortical screw to achieve three-point fixation to the occiput. It has been shown that a one-piece loop fixed to the skull with screws provided for greater stiffness in rotation than devices wired to the skull.<sup>23</sup> Reduced motion should therefore lead to higher fusion rates, although data to support this are not yet available.

Presently, when occipitocervical fixation is needed we have used a 3.5- or 4-mm polyaxial C1–2 transarticular screw combined with individual rods that either attach separately to the occiput or preferably mate to a central occipital plate. We use the longest possible occipital screws and try to achieve bicortical purchase with each screw.

An autologous iliac crest graft is harvested for fusion. The graft is fully decorticated on the surfaces that contact the occiput and the posterior elements of the first two cervical vertebrae. The graft is fashioned to best achieve osseous contact with these surfaces prior to placement of the multistranded titanium cable. A single fixation screw through the upper end of the graft into the occiput is used to ensure firm apposition of the connecting surfaces to enhance fusion success.

### Conclusions

Atlantoaxial transarticular screw fixation, with proper patient selection and meticulous presurgical planning, is a highly effective means of achieving fusion with a low associated complication rate. In our series, a 98% fusion rate was achieved with a 1.4% incidence of malpositioned screws and 1.7% incidence of VA injury. Surgery-related complications were greatly reduced in our series by the lessons learned.

### Disclosure

Dr. Apfelbaum is a paid consultant for the Aesculap Corporation and a Medtronic stockholder.

### References

1. Apfelbaum R: Posterior C1–2 screw fixation for atlantoaxial instability, in Rengachary SS, Wilkins RH (eds): **Neurosurgical Operative Atlas**. Baltimore: Williams & Wilkins, 1995. Vol 4, pp 19–28
2. Apfelbaum RI: Posterior transarticular C1–2 screw fixation for atlantoaxial instability. **Aesculap Scientific Information** 25: 1–4, 1994
3. Brockmeyer D, Apfelbaum R, Tippets R, Walker M, Carey L: Pediatric cervical spine instrumentation using screw fixation. **Pediatr Neurosurg** 22:147–157, 1995
4. Brockmeyer DL, York JE, Apfelbaum RI: Anatomical suitability of C1–2 transarticular screw placement in pediatric patients. **J Neurosurg (Spine 1)** 92:7–11, 2000
5. Brooks AL, Jenkins EB: Atlanto-axial arthrodesis by the wedge compression method. **J Bone Joint Surg Am** 60:279–284, 1978
6. Clark CR, Goetz DD, Menezes AH: Arthrodesis of the cervical spine in rheumatoid arthritis. **J Bone Joint Surg Am** 71: 381–392, 1989
7. Coric D, Branch CL Jr, Wilson JA, Robinson JC: Arteriovenous fistula as a complication of C1–2 transarticular screw fixation. Case report and review of the literature. **J Neurosurg** 85: 340–343, 1996
8. Coyne TJ, Fehlings MG, Wallace MC, Bernstein M, Tator CH: C1–C2 posterior cervical fusion: long-term evaluation of results and efficacy. **Neurosurgery** 37:688–693, 1995
9. Dickman CA, Crawford NR, Brantley AG, Sonntag VK: Biomechanical effects of transoral odontoidectomy. **Neurosurgery** 36:1146–1153, 1995
10. Dickman CA, Crawford NR, Paramore CG: Biomechanical characteristics of C1–2 cable fixations. **J Neurosurg** 85: 316–322, 1996
11. Dickman CA, Sonntag VK: Posterior C1–2 transarticular screw fixation for atlantoaxial arthrodesis. **Neurosurgery** 43: 275–281, 1998
12. Dickman CA, Sonntag VK, Papadopoulos SM, Hadley MN: The interspinous method of posterior atlantoaxial arthrodesis. **J Neurosurg** 74:190–198, 1991
13. Eleraky MA, Masferrer R, Sonntag VK: Posterior atlantoaxial facet screw fixation in rheumatoid arthritis. **J Neurosurg** 89: 8–12, 1998
14. Fielding JW, Cochran GB, Lawsing JF III, Hohl M: Tears of the transverse ligament of the atlas. A clinical and biomechanical study. **J Bone Joint Surg Am** 56:1683–1691, 1974
15. Fielding JW, Hawkins RJ, Ratzan SA: Spine fusion for atlantoaxial instability. **J Bone Joint Surg Am** 58:400–407, 1976
16. Gallie WE: Fractures and dislocations of the cervical spine. **Am J Surg** 46:495–499, 1939
17. Gluf WM, Brockmeyer DL: Atlantoaxial transarticular screw fixation: a review of surgical indications, fusion rate, complications, and lessons learned in 67 pediatric patients. **J Neurosurg Spine** 2:164–169, 2005
18. Griswold DM, Albright JA, Schiffman E, Johnson R, Southwick W: Atlanto-axial fusion for instability. **J Bone Joint Surg Am** 60:285–292, 1978
19. Grob D, Crisco JJ III, Panjabi MM, Wang P, Dvorak J: Biomechanical evaluation of four different posterior atlantoaxial fixation techniques. **Spine** 17:480–490, 1992
20. Haid RW Jr, Subach BR, McLaughlin MR, Rodts GE Jr, Wahlgig JB Jr, et al: C1–C2 transarticular screw fixation for atlantoaxial instability: a 6-year experience. **Neurosurgery** 49: 65–70, 2001

## Atlantoaxial transarticular screw fixation

21. Hanley EN Jr, Harvell JC Jr: Immediate postoperative stability of the atlantoaxial articulation: a biomechanical study comparing simple midline wiring, and the Gallie and Brooks procedures. **J Spinal Disord** **5**:306–310, 1992
22. Hanson PB, Montesano PX, Sharkey NA, Raushning W: Anatomic and biomechanical assessment of transarticular screw fixation for atlantoaxial instability. **Spine** **16**:1141–1145, 1991
23. Hurlbert RJ, Crawford NR, Choi WG, Dickman CA: A biomechanical evaluation of occipitocervical instrumentation: screw compared with wire fixation. **J Neurosurg (Spine)** **1** **90**:84–90, 1999
24. Lowry DW, Pollack IF, Clyde B, Albright AL, Adelson PD: Upper cervical spine fusion in the pediatric population. **J Neurosurg** **87**:671–676, 1997
25. Madawi AA, Casey AT, Solanki GA, Tuite G, Veres R, Crookard HA: Radiological and anatomical evaluation of the atlantoaxial transarticular screw fixation technique. **J Neurosurg** **86**:961–968, 1997
26. Magerl F, Seeman PS: Stable posterior fusion of the atlas and axis by transarticular screw fixation, in Kehr P, Weidner A (eds): **Cervical Spine**. Berlin: Springer-Verlag, 1986, pp 322–327
27. Paramore CG, Dickman CA, Sonntag VK: The anatomical suitability of the C1–2 complex for transarticular screw fixation. **J Neurosurg** **85**:221–224, 1996
28. Ranawat CS, O'Leary P, Pellicci P, Tsairis P, Marchisello P, Dorr L: Cervical spine fusion in rheumatoid arthritis. **J Bone Joint Surg Am** **61**:1003–1010, 1979
29. Singh SK, Rickards L, Apfelbaum RI, et al: Occipitocervical reconstruction with the Ohio Medical Instruments Loop: results of a multicenter evaluation in 30 cases. **J Neurosurg (Spine)** **3** **98**:239–246, 2003
30. Song GS, Theodore N, Dickman CA, Sonntag VK: Unilateral posterior atlantoaxial transarticular screw fixation. **J Neurosurg** **87**:851–855, 1997
31. Thompson RC Jr, Meyer TJ: Posterior surgical stabilization for atlantoaxial subluxation in rheumatoid arthritis. **Spine** **10**:597–601, 1985
32. Wang J, Vokshoor A, Kim S, Elton S, Kosnik E, Bartkowski H: Pediatric atlantoaxial instability: management with screw fixation. **Pediatr Neurosurg** **30**:70–78, 1999
33. Wright NM, Lauryssen C: Vertebral artery injury in C1–2 transarticular screw fixation: results of a survey of the AANS/CNS Section on Disorders of the Spine and Peripheral Nerves. **J Neurosurg** **88**:634–640, 1998

---

Manuscript received April 15, 2004.

Accepted in final form August 31, 2004.

Address reprint requests to: Ronald I. Apfelbaum, M.D., Department of Neurosurgery, University of Utah, 30 N. 1900 East, Suite 3B409, Salt Lake City, Utah 84132-2303, email: ronald.apfelbaum@hsc.utah.edu.