

MINIMALLY INVASIVE THORACOSCOPIC RESECTION OF PARASPINAL NEUROGENIC TUMORS: TECHNICAL CASE REPORT

Peter Kan, M.D.

Department of Neurosurgery,
University of Utah School of Medicine,
Salt Lake City, Utah

Meic H. Schmidt, M.D.

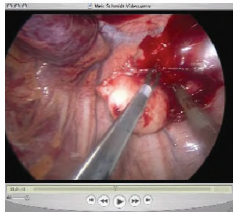
Spinal Oncology Service,
Huntsman Cancer Institute, and
Department of Neurosurgery,
University of Utah School of Medicine,
Salt Lake City, Utah

Reprint requests:

Meic H. Schmidt, M.D.,
Department of Neurosurgery,
University of Utah,
175 N. Medical Drive,
Salt Lake City, UT 84132.
Email: meic.schmidt@hsc.utah.edu

Received, September 28, 2007.

Accepted, February 8, 2008.



ONLINE
DIGITAL
VIDEO

OBJECTIVE: The posterior mediastinum is a common location for benign neurogenic tumors. They are frequently asymptomatic but can present with local compressive or neurological symptoms.

METHODS: Thoracoscopy is used increasingly over posterolateral thoracotomy for the removal of these lesions.

RESULTS: Complete resection of these tumors through a thoracoscopic approach is possible in most cases, but dumbbell tumors present as special challenges, which require a combined thoracoscopic and open posterior approach.

CONCLUSION: In this article, we outline the technique of thoracoscopic resection of paraspinal neurogenic tumors through an operative video and a review of the literature to summarize the surgical outcomes of patients with these lesions.

KEY WORDS: Minimally invasive approaches, Neurogenic tumors, Thoracoscopy

Neurosurgery 63/ONS Suppl 1:ONSE54, 2008

DOI: 10.1227/01.NEU.0000313118.73941.D7

Neurogenic tumors represent 75% of all posterior mediastinal tumors (16). Thoracoscopy is increasingly chosen over open thoracotomy for resection of these lesions because of reduced morbidity compared with thoracotomy (7). The aim of this article is to describe the technique of minimally invasive thoracoscopic resection of paraspinal neurogenic tumors in the posterior mediastinum (3, 5, 8) through an operative video and a review of the surgical outcomes that have been reported in the literature.

SURGICAL TECHNIQUE

(see video at web site)

Anesthesia and Positioning

The patient is intubated with a double-lumen endotracheal tube for single-lung ventilation. The patient is then secured in a lateral decubitus position on a radiolucent table with a three-point support system to the sacrum, pubic bone, and scapula. The patient's top arm is placed on a Krause armrest, and an inflatable cuff is placed under the axilla.

Localization and Placement of Chest Portals

After the patient has been positioned, the corresponding level of the lesion is identified

using lateral C-arm fluoroscopy and marked on the skin. Three access portals are outlined on and around the area of interest (Fig. 1). The working portal is centered immediately over the lesion. The portal for the endoscopic camera is placed two to three intercostal spaces (approximately 8 cm) caudal to the working portal along the anterior vertebral body line for lesions in the middle and upper thoracic spine. The final portal for the lung retractor is placed ventral to and slightly below the working portal in a radius that is also approximately 8 cm from the working portal. A linear incision along the rib overlying the lesion is prepared for the possibility of converting to an open thoracotomy if necessary. For optimal ease, the three ports can be used interchangeably.

Once single-lung ventilation has been initiated and verified, we start by placing the endoscopic camera port. The skin is incised and the intercostal muscles are dissected bluntly to identify the underlying rib. A curved clamp is then gently placed over the underlying rib, avoiding the neurovascular bundle running underneath, and the pleural space is entered bluntly. Finger palpation is used to detect any pleural adhesions, and the portal is placed. The 30-degree endoscope is then advanced through the portal

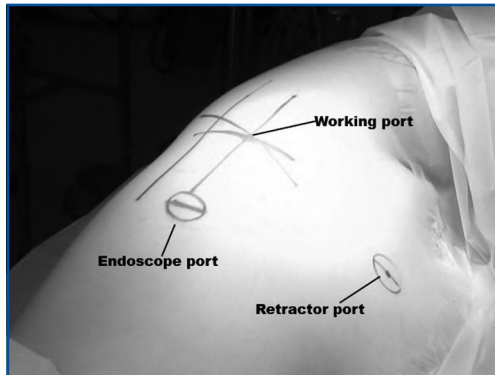


FIGURE 1. Patient positioned in a left lateral decubitus position. The working port is centered over the lesion with a ventral retractor port and a caudal endoscopic port.

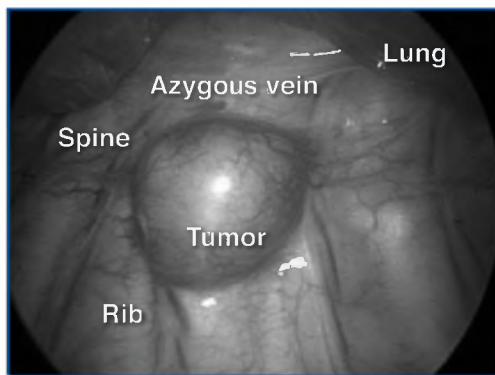


FIGURE 2. Endoscopic view showing a large exophytic mass with the azygous vein located anteriorly and the spine and ribs adjacent to the lesion.

to ensure that the lung is deflated. The remaining two portals are then placed under direct endoscopic visualization in a similar fashion. The tumor and adjacent vascular, visceral, and musculoskeletal structures are identified (Fig. 2).

Peripherally Located Tumors Involving an Intercostal Nerve

Once the tumor has been identified, its capsule is cauterized; specimens can be sent to be made into frozen samples for histological analysis. If the tumor has a significant cystic component, a long needle can be used to decompress the lesion internally. The parietal pleura is then incised circumferentially around the lesion by using electrocautery. The tumor capsule is mobilized with a blunt-tipped dissector to separate it from the intercostal vessels, and the vascular supply to the tumor is coagulated. When the tumor is located peripherally on the intercostal nerve and does not involve the foramen, the normal segments of the nerve are identified proximally and distally by mobilizing the neurovascular bundle from the rib. The intercostal nerve is then

sectioned proximally and distally. The tumor is extracted with the use of an endoscopic specimen pouch through one of the portal sites, which is usually enlarged with a speculum.

Nerve Sheath Tumors that Extend into the Neural Foramen

For tumors that extend partially into the neural foramen, the distal intrathoracic portion is first removed through a thoracoscopic approach, as described above. Care must be taken to avoid traction on the proximal tumor within the foramen to prevent proximal nerve root avulsion and spinal cord injury. The stalk of the proximal tumor remaining within the foramen is resected last. To resect the intraforaminal tumor portion, the epidural space, dura, and normal proximal nerve root sleeve must be identified and exposed by removing the rib head and pedicle of the vertebra caudal to the involved foramen. The posterior edge of the vertebral body at the affected level may also need to be removed to gain additional exposure to the foramen. The proximal tumor entering the foramen is then shrunk with endoscopic bipolar cauterization to facilitate access and mobilization. The root sleeve is ligated at its junction with the dura by using an endoscopic suture ligature or a hemoclip. The root is sectioned distal to the ligature, and the residual foraminal tumor is removed. The dura is then inspected, and a Valsalva maneuver is performed to confirm the absence of a cerebrospinal fluid leak.

Dumbbell Tumors with an Intradural Component

When the tumor demonstrates intradural extension on preoperative imaging, we recommend a combined thoracoscopic and open posterior approach. A posterior approach through a unilateral laminectomy, facetectomy, and fusion should be performed first to resect the intradural component of the tumor. This allows the spinal cord to be free of tumor so that traction on the spinal cord is avoided during the second stage of surgery. Once the intradural portion of the tumor is resected and the dura is closed in a watertight fashion (another advantage of the open posterior approach), we then proceed to resect the intrathoracic portion of the tumor through a thoracoscopic approach, as described above. The combined thoracoscopic and posterior approach can also be performed simultaneously during the same session (3).

Closure and Postoperative Care

At this point, the thoracic cavity is irrigated, and a small 20-French chest tube is placed in the chest cavity apex through the most inferior portal under direct endoscopic visualization. Lung reinflation is also visualized with the camera to ensure all lobes inflate properly. Portal sites are then closed in multiple layers and the chest tube is secured. A chest x-ray is obtained immediately to ensure proper lung inflation. Daily output from the chest tube is recorded, and the chest tube is removed when output falls below 100 ml per day.

Illustrative Case

A 19-year-old woman had a paraspinal mass found on computed tomographic (CT) scans of the chest that were obtained for workup of dyspnea and chest pain during pregnancy. Follow-up magnetic reso-

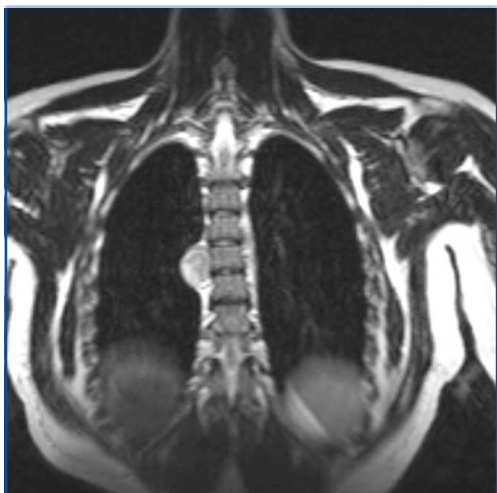


FIGURE 3. Coronal T2-weighted magnetic resonance imaging sequence showing a large right-sided paraspinal lesion at the T6 level.

nance imaging after an uneventful delivery confirmed a right-sided 3 × 2 × 3-cm paraspinal mass with significant interval growth, approximately at the level of the T6 vertebral body (Fig. 3). Given her symptoms, her young age, and the interval growth of the lesion, resection was offered to the patient. She underwent a right-sided thoracoscopic approach for tumor resection with no complications. Operative time was 90 minutes and estimated blood loss was 100 ml. The patient was discharged on postoperative Day 1 after her chest tube was removed. Final pathological analysis of the specimen revealed a benign schwannoma.

DISCUSSION

Neurogenic tumors are the most common lesions in the posterior mediastinum (4, 16). Most are found in the upper half or third of the chest and are benign in more than 90% of cases in adults but in only 50% of cases in children (16). They are grouped according to their origin: those that originate from peripheral nerves (schwannomas, neurofibromas, and malignant nerve sheath tumors), those that develop from the sympathetic chain (ganglioneuromas, ganglioneuroblastomas, and neuroblastomas), and those rare tumors that arise from the parasympathetic ganglia (2, 6, 13, 15). Nerve sheath tumors are more common in adults, whereas sympathetic tumors are more common in children. Overall, there is no sex predominance, and most patients are asymptomatic (11, 17). When symptoms arise, patients can present with chest symptoms (dyspnea, cough, and chest pain), neurological symptoms (Horner’s syndrome, radiculopathy, and myelopathy), swallowing difficulties, or scoliosis.

Chest CT scanning with contrast is the initial imaging modality of choice. Apart from giving information regarding tumor size, characteristics, and location, chest CT scanning also provides information regarding intraspinal extension, which occurs in up to 10% of cases (1) by demonstrating erosion of the pedicle or lamina, or enlargement of the neuro-

TABLE 1. Indications for surgical resection of paraspinal neurogenic tumors

Symptom type	Symptoms
Neurological	Radiculopathy, myelopathy, Horner’s syndrome
Chest	Dyspnea, dysphagia, chest pain, cough

foramen. Once intraspinal extension is suspected, chest magnetic resonance imaging with gadolinium enhancement should be obtained to assess the tumor’s relationship with the surrounding spinal cord.

Asymptomatic lesions can be followed conservatively with serial imaging. Symptomatic lesions and lesions that exhibit interval growth are the indications for surgery (Table 1). In the past, resection through a posterolateral thoracotomy was the standard treatment and offered excellent therapeutic outcome (14). The use of a thoracoscopic approach for resection of posterior mediastinal tumors was first reported by Landreneau et al. (10) in 1992, and use of this technique has since been growing in popularity because of its efficacy and reduced morbidity compared with posterolateral thoracotomy. Fewer postoperative complications, shorter postoperative stays, decreased hospital costs, less postoperative pain and disability, a better cosmetic appearance, and earlier return to work are some of the reported benefits associated with thoracoscopic resection of mediastinal neurogenic tumors (11, 12).

In a literature review of 231 cases of thoracoscopic posterior mediastinal tumor resection, Kumar et al. (9) found that the complication and the recurrence rates are comparable with those reported after open resection. The mean operating time was 103 minutes. Blood loss was minimal, and no transfusion was required. Conversion to an open thoracotomy was required in 9% of patients, and tumor size was the most important factor necessitating conversion (18). Mean hospital stay was 5.6 days. In the review, no mortality was found, and postoperative complications, half of which were transient paresthesia, occurred in 12% of patients. The remaining complications were ptosis, hoarseness, effusion, empyema, neuralgia, and postoperative hemorrhage requiring repeated thoracoscopy. The paresthesias, neuralgia, hoarseness, and ptosis all resolved over time, and the effusion and empyema were treated successfully with aspiration and antibiotics.

The ideal candidates for thoracoscopy are those patients whose tumors are located peripherally within the intercostal nerves. Patients whose tumors are adhered in the superior sulcus or those with intraspinal extension (dumbbell tumors) pose special challenges. When the tumor is adhered within the superior sulcus, mobilization is often difficult, and the risk of Horner’s syndrome is higher because of the proximity to the stellate ganglion. Complex dumbbell tumors with an intraspinal component require a staged approach. In these cases, the thoracic and intraspinal tumor are connected by a narrow foraminal component, and traction on the spinal cord

through the foraminal portion during thoracoscopic mobilization of the intrathoracic tumor could lead to proximal nerve root avulsion, cerebrospinal fluid leak, or spinal cord injury (5, 8). In approaching these dumbbell tumors, a posterior approach with complete clearance of the intracanalicular component of the tumor and decompression of the spinal cord followed by a watertight dural closure should be performed first. Thereafter, the intrathoracic tumor can be excised with the use of a thoracoscopic approach efficiently and safely.

CONCLUSION

Neurogenic tumors are common lesions in the posterior mediastinum. Most can be removed completely through a minimally invasive thoracoscopic approach. Patients with dumbbell tumors pose a special challenge. In these rare cases, a combined posterior thoracoscopic approach must be used.

REFERENCES

1. Akwari OE, Payne WS, Onofrio BM, Dines DE, Muhm JR: Dumbbell neurogenic tumors of the mediastinum: Diagnosis and management. *Mayo Clin Proc* 53:353–358, 1978.
2. Arapis C, Gossot D, Debrosse D, Arper L, Mazel C, Grunenwald D: Thoracoscopic removal of neurogenic mediastinal tumors: Technical aspects. *Surg Endosc* 18:1380–1383, 2004.
3. Barrenechea JJ, Fukumoto R, Lesser JB, Ewing DR, Connery CP, Perin NI: Endoscopic resection of thoracic paravertebral and dumbbell tumors. *Neurosurgery* 59:1195–1202, 2006.
4. Davidson KG, Walbaum PR, McCormack RJ: Intrathoracic neural tumours. *Thorax* 33:359–367, 1978.
5. Dickman CA, Apfelbaum RI: Thoracoscopic microsurgical excision of a thoracic schwannoma: Case report. *J Neurosurg* 88:898–902, 1998.
6. Grillo HC, Ojemann RG, Scannell JG, Zervas NT: Combined approach to “dumbbell” intrathoracic and intraspinal neurogenic tumors. *Ann Thorac Surg* 36:402–407, 1983.
7. Han PP, Dickman CA: Thoracoscopic resection of thoracic neurogenic tumors. *J Neurosurg* 96:304–308, 2002.
8. Konno S, Yabuki S, Kinoshita T, Kikuchi S: Combined laminectomy and thoracoscopic resection of dumbbell-type thoracic cord tumor. *Spine* 26:E130–E134, 2001.
9. Kumar A, Kumar S, Aggarwal S, Khilnani GC: Thoracoscopy: The preferred approach for the resection of selected posterior mediastinal tumors. *J Laparoendosc Adv Surg Tech A* 12:345–353, 2002.
10. Landreneau RJ, Dowling RD, Ferson PF: Thoracoscopic resection of a posterior mediastinal neurogenic tumor. *Chest* 102:1288–1290, 1992.
11. Liu HP, Yim AP, Wan J, Chen H, Wu YC, Liu YH, Lin PJ, Chang CH: Thoracoscopic removal of intrathoracic neurogenic tumors: A combined Chinese experience. *Ann Surg* 232:187–190, 2000.
12. Petty JK, Bensard DD, Partrick DA, Hendrickson RJ, Albano EA, Karrer FM: Resection of neurogenic tumors in children: Is thoracoscopy superior to thoracotomy? *J Am Coll Surg* 203:699–703, 2006.
13. Reed JC, Hallett KK, Feigin DS: Neural tumors of the thorax: Subject review from the AFIP. *Radiology* 126:9–17, 1978.
14. Ribet ME, Cardot GR: Neurogenic tumors of the thorax. *Ann Thorac Surg* 58:1091–1095, 1994.
15. Shields TW, Reynolds M: Neurogenic tumors of the thorax. *Surg Clin North Am* 68:645–668, 1988.
16. Silverman NA, Sabiston DC Jr: Mediastinal masses. *Surg Clin North Am* 60:757–777, 1980.
17. Yamaguchi M, Yoshino I, Fukuyama S, Osoegawa A, Kameyama T, Tagawa T, Maehara Y: Surgical treatment of neurogenic tumors of the chest. *Ann Thorac Cardiovasc Surg* 10:148–151, 2004.

18. Zierold D, Halow KD: Thoracoscopic resection as the preferred approach to posterior mediastinal neurogenic tumors. *Surg Laparosc Endosc Percutan Tech* 10:222–225, 2000.

Acknowledgments

The video that accompanies this article was presented at the 2007 Congress of Neurological Surgeons Annual Meeting, San Diego, California, September 15–20, 2007, as a video kiosk. We thank Kristin Kraus for editorial assistance in preparing the article and Kelly Johnson for preparation of the video.

COMMENTS

Kan and Schmidt have nicely presented the technique of thoracoscopic tumor resection. Although this technique has definite merit, more traditional alternatives retain merit as well. For example, a combined minimally invasive (for the thoracic paraspinal component) and open (for the intradural component) technique for dumbbell tumors could be readily addressed via a laminectomy and lateral extracavitary approach. This approach can be undertaken through the same incision at the same sitting. Such an open only approach is associated with only slightly greater morbidity than the open approach alone and does not expose the patient to the additional risks associated with the minimally invasive component. Nevertheless, Kan and Schmidt have provided a wonderful presentation on and insight into the technique.

Edward C. Benzel
Cleveland, Ohio

Kan and Schmidt highlight their technique for removal of paraspinal neurogenic tumors through a minimally invasive approach via a thoracoscope. The use of thoroscopes to treat numerous spinal pathological conditions including scoliosis, thoracic fractures, and tumors has increased over the past decade (1). It is important to note that thoracoscopy for spinal surgery is rarely associated with complications (such as aortic or vena caval injury) requiring conversion to an open procedure, and preparation at the start of such patients for quick conversion to open surgery is advisable.

Praveen V. Mummaneni
San Francisco, California

1. Mummaneni PV, Sasso RC: Minimally invasive, endoscopic, internal thoracoplasty for the treatment of scoliotic rib hump deformity: Technical note. *Neurosurgery* 56[Suppl 2]:E444, 2005.

Kan and Schmidt have provided an excellent description and video demonstration of the techniques that are used for thoracoscopic removal of intrathoracic paraspinal tumors. The indications for surgery to remove benign paraspinal nerve sheath tumors include relief of mass effect on the spinal cord, prevention of tumor growth within the spinal canal, relief of mass effect within the thorax if pulmonary function is impaired, obtaining a tissue diagnosis, and prevention of malignant transformation of the tumor.

The key to thoracoscopic tumor resection is to perform intralaminar resection of the tumor first, similar to the way in which intracranial meningiomas are resected. After the tumor is debulked internally, its edges are foiled away from the adjacent mediastinal vascular and visceral structures. Traction on the proximal nerve root must be avoided to prevent root avulsion and leakage of cerebrospinal fluid.

Tumors that extend from the chest cavity into the neural foramen can often be removed without performing a laminectomy. The widened foramen provides an excellent corridor for resection of the foraminal tumor, and the pedicle can be removed with Kerrison rongeurs to provide wider access. Soft tumors can be resected within the foramen and shrunk with bipolar coagulation. The nerve root sleeve is then ligated with hemoclips or suture ligatures. If the tumor extends intradurally or if the foraminal tumor is dense and rubbery, it is best to perform a unilateral hemilaminotomy to resect the intradural tumor or to amputate the proximal stump of the tumor.

In experienced hands thoracoscopy provides significantly less morbidity than open thoracotomy, while preserving surgical efficacy for benign paraspinal neurogenic tumors. It has become my method of choice for resecting these lesions. My experience with removing 24 benign paraspinal neurogenic tumors using thoracoscopy and more than 600 thoracoscopic spine surgery procedures has demonstrated major advantages of this operative approach. Thoracoscopy has significantly lower rates of pulmonary complications, postoperative pain, intercostal neuralgia, shoulder girdle dysfunction, and chronic pain syndromes than open thoracotomy (1–5).

Thoracoscopy should not be used for malignant paraspinal neurogenic tumors. Malignant tumors should be resected en bloc with a clean surgical margin. Thoracoscopy only permits piecemeal resection of tumors; therefore, it can potentially seed malignant lesions within the pleural space or chest wall. Malignant lesions can be differentiated from benign lesions on preoperative computed tomographic and magnetic resonance imaging scans. Compared with sharply marginated, well-circumscribed benign tumors, malignant lesions are invasive and poorly demarcated.

Curtis A. Dickman
Phoenix, Arizona

1. Ferson PF, Landreneau RJ, Dowling RD, Hazelrigg SR, Ritter P, Nunchuck S, Perrino MK, Bowers CM, Mack MJ, Magee MJ: Comparison of open versus thoracoscopic lung biopsy for diffuse infiltrative pulmonary disease. *J Thorac Cardiovasc Surg* 106:194–199, 1993.
2. Han PP, Dickman CA: Thoracoscopic resection of thoracic neurogenic tumors. *J Neurosurg* 96:304–308, 2002.

3. Han PP, Kenny K, Dickman CA: Thoracoscopic approaches to the thoracic spine: Experience with 241 surgical procedures. *Neurosurgery* 51[Suppl]:S88–S95, 2002.
4. Landreneau RJ, Hazelrigg SR, Mack MJ, Dowling RD, Burke D, Gavlick J, Perrino MK, Ritter PS, Bowers CM, DeFino J, Nunchuck SK, Freeman J, Keenan R, Ferson PF: Postoperative pain-related morbidity: Video-assisted thoracic surgery versus thoracotomy. *Ann Thorac Surg* 56:1285–1289, 1993.
5. Rosenthal D, Dickman CA: Thoracoscopic microsurgical excision of herniated thoracic discs. *J Neurosurg* 89:224–235, 1998.

Kan and Schmidt have nicely described their technique for thoracoscopic resection of benign spinal tumors. The methods are well described, outlining the nuances of their approach. One must remember that these approaches are challenging to surgeons inexperienced in their application, as endoscopic visualization can be disorienting and micromanipulation can be difficult, and Kan and Schmidt have produced their impressive results.

It is clear from the increasing number of reports such as this one on thoracoscopic surgery that one day this will become the optimal method for treating anterior spinal lesions in this region. With the relentless advancements in image guidance, robotics, and computer processing, thoracoscopic surgery will become safer and more accessible, allowing for the treatment of ever more complex pathological lesions.

Michael Y. Wang
Miami, Florida

Kan and Schmidt present a video and article for minimally invasive resection of posterior mediastinal tumors. Their innovative surgical technique adds to the armamentarium of methods available to treat these challenging tumors. In the case presented, it is difficult to understand the indication for the surgery. They state that dyspnea was the indication and that the tumor had radiographically enlarged. Multiple points are difficult to fully comprehend. How does such a small lesion in a teenager cause dyspnea? It is also difficult to ascertain how a tumor that could have an objective, rapid increase in size, as to be radiographically evident, could be a benign schwannoma. Nonetheless, the lesion was successfully treated through a thoracoscopic approach with an excellent clinical outcome.

Robert F. Heary
Newark, New Jersey