

## **Technique for Methyl Methacrylate Cranioplasty to Optimize Cosmetic Outcome**

Mohammad Sorour, MBBS,<sup>1</sup> William L. Caton, III, MD,<sup>2</sup> William T. Couldwell, MD, PhD<sup>1</sup>

<sup>1</sup>Department of Neurosurgery, Clinical Neurosciences Center, University of Utah, Salt Lake City, Utah; <sup>2</sup>Huntington Memorial Hospital, Pasadena, California

**Corresponding author:** William T. Couldwell, MD, PhD

Department of Neurosurgery

University of Utah

175 N. Medical Drive East

Salt Lake City, UT 84132

Phone: 801-581-6908

Fax: 801-581-4138

Email: neuropub@hsc.utah.edu

**Disclosure:** The authors have no conflicts of interest to disclose.

**Abstract**

*Background:* Cranioplasty aims to reconstruct skull defects from fractures, decompressive craniectomies, tumors, and congenital anomalies in a cosmetically acceptable manner. We present a technique in methyl methacrylate cranioplasty that gives excellent cosmetic results by maintaining patient's calvarial curvature.

*Method:* Cranioplasty material is placed into a plastic bag and packed inside the defect. Wire mesh cut larger than the defect is held in position to take the exact skull curvature. Once solid, the implant is fixed in position using titanium plates and mini-screws.

*Conclusion:* This is a simple, inexpensive method of achieving the most cosmetically desired cranioplasty results.

**Key Words:** Cranioplasty; methyl methacrylate; cosmesis

## Introduction

Cranioplasty is a widely practiced neurosurgical procedure that not only aims to protect underlying brain tissue from skull defects, but also attempts to restore normal calvarial contour in a cosmetically accepted manner [1,2,4,8,9]. Recent reports in the literature have documented increasing numbers of brain and skull tumors requiring cranioplasty [1,2], and cranioplasty is also required in patients undergoing decompressive craniectomies after traumatic brain injuries or strokes, as well as those with congenital skull anomalies and skull fractures [1,2].

Ideal materials to be used for cranioplasty should have low thermal and magnetic conductance and be biocompatible, inert, resistant to infections, lightweight, strong, easy to mold, radiolucent, readily available, and relatively cost-effective [1-4,9,10]. Methyl methacrylate cranioplasty is accepted in many centers as being superior to titanium mesh because it is radiolucent, less expensive, easier to shape, and light in weight, it conducts less heat, and it has lower rates of infection when compared with titanium implants [1,2,4-6,8-10]. Previous descriptions of methyl methacrylate cranioplasty have focused on adding strength to the cranioplasty by using titanium wires in the implant [2,7,10], but none has addressed the use of methyl methacrylate to improve cosmesis as well. We present our simple and inexpensive technique that allows the cranioplasty to take the exact curvature of the patient's calvaria.

Improving cosmetic outcomes after surgeries in the face, neck, and scalp can be a challenge to the surgeon as bad outcomes can be psychologically unacceptable for patients. Maintaining the patient's calvarial curvature is an important cosmetic outcome to avoid negative psychological effects if the cranioplasty flap has a grossly different curvature. Our technique is sufficiently

durable using titanium plates and microscrews yet is technically simple and inexpensive, yielding superior cosmesis through maintenance of the patient's calvarial curvature.

### **Relevant Surgical Anatomy**

The region of the defect for skull replacement is exposed in its entirety. A 1-cm margin of normal bone edge is required to facilitate curvature of the implant with a wire mesh template.

### **Description of Cranioplasty Technique**

Utilizing a Gelfoam template of the bony defect, we cut a wire mesh to the shape of skull defect but with wider dimensions (Fig. 1). Precise measurements are not necessary. The cranioplasty material is made by mixing 1 g of vancomycin powder (Hospira) with methyl methacrylate monomer liquid (Howmedica) in a sterile bowl until it achieves a semisolid consistency. The material is then placed into a plastic bag and carefully packed inside the skull defect, filling it completely (Fig. 2). The mesh is placed over the plastic bag and firmly held in position from all corners, allowing it to take the exact skull curvature (Fig. 3). Cool saline is irrigated over the cranioplasty until the methyl methacrylate polymerizes and takes the shape and curvature of the overlying wire mesh. Once solid, the methyl methacrylate implant is removed from the plastic bag, and the inner surface is thinned and smoothed with a diamond drill if necessary to mimic the contour of a normal calvaria. The custom cranioplasty flap is then fixed in position using titanium plates and mini-screws (Biomet Thin-Flap plating system) (Fig. 4).

### **Indications and Limitations**

Indications for cranioplasty include skull fractures, decompressive craniectomies for strokes or traumatic brain injuries, skull tumors, and congenital anomalies. This technique of methyl methacrylate cranioplasty can be used in most patients. Patients with known allergies to methyl methacrylate material are not candidates for this procedure. Active infection at the site of surgery is also a contraindication. If the surgery involves removal of parts of skull bone that have complex three-dimensional orientation or in patients with defects larger than approximately 12 cm, custom-made cranioplasty made be more appropriate.

### **How to Avoid Complications**

A piece of dried compressed Surgifoam (Ferrosan Medical Devices) is placed over the duraplasty for extra protection from the thermal effects of the setting cranioplasty material. Prior to its preparation, methyl methacrylate monomer liquid is mixed with vancomycin to minimize the risk of postoperative infection. The inner surface of the methyl methacrylate implant is thinned and smoothed with a diamond drill if necessary to avoid pressure and mass effect over the brain surface.

### **Specific Perioperative Considerations**

Preoperative workup includes identifying the abnormal skull lesion to be excised based on preoperative CT and MRI scans. Postoperatively, a CT scan is obtained to ensure that there are no complications like hematoma formation. Standard postoperative care including wound care should be followed to avoid infection.

### **Information for Patients**

If the patient notices any redness, swelling, hotness, or pain at the site of surgery, this might indicate hypersensitivity to methyl methacrylate or infection at the site of surgery, which can spread to the methyl methacrylate implant. This warrants seeking immediate medical consultation. Patients should avoid activities that put them at risk of direct head trauma to the implant.

### Key Points

1. Use complete aseptic techniques during surgery and mix the methyl methacrylate monomer with antibiotics to minimize risk of infection,
2. Cut the wire mesh in larger dimensions than the skull defect so that it can be held it from all corners against the normal surrounding calvaria.
3. The methyl methacrylate liquid monomer is placed in a plastic bag to avoid direct contact of the methyl methacrylate material with the brain surface, minimizing thermal effects of the setting.
4. Allow the methyl methacrylate to harden slightly inside the plastic bag to allow for easier and complete packing of the skull defect by the cranioplasty material.
5. The wire mesh must be held firmly from all corners against the surrounding calvaria to assure that the methyl methacrylate reaches solid consistency and the cranioplasty flap takes the exact curvature of patient's calvaria.
6. A piece of compressed Surgifoam applied over the dura protects it from thermal effects during the methyl methacrylate polymerization.
7. The inner surface of the cranioplasty flap can be thinned using a diamond burr to avoid applying pressure over the brain surface.

8. Standard postoperative wound care should be practiced to avoid postoperative infection, which warrants removal of the cranioplasty flap.
9. Avoid direct trauma to the cranioplasty flap as it is more fragile than normal skull bone and can fracture.
10. This method may be inadequate for reconstructing areas of skull that have complex three-dimensional configuration such as the orbital walls or defects larger than approximately 12 cm.


### **Acknowledgments**

We thank Kristin Kraus, MSc, and Ramin Eskandari, MD, for editorial assistance with this paper.

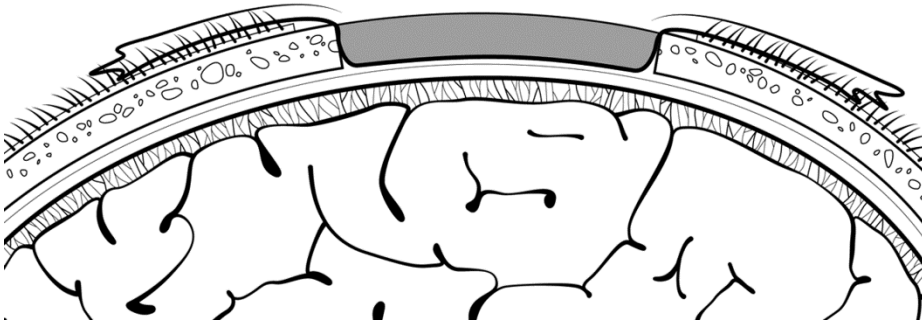
## References

1. Al-Tamimi YZ, Sinha P, Trivedi M, Robson C, Al-Musawi TA, Hossain N, Mumford C, Towns G (2012) Comparison of acrylic and titanium cranioplasty. *Br J Neurosurg* 26:510-513
2. Aydin S, Kucukyuruk B, Abuzayed B, Sanus GZ (2011) Cranioplasty: Review of materials and techniques. *J Neurosci Rural Pract* 2:162-167
3. Blake DP (1994) The use of synthetics in cranioplasty: a clinical review. *Mil Med* 159:466-469
4. Chiarini L, Figurelli S, Pollastri G, Torcia E, Ferrari F, Albanese M, Nocini PF (2004) Cranioplasty using acrylic material: a new technical procedure. *J Craniomaxillofac Surg* 32:5-9
5. Drosos GI, Babourda E, Magnissalis EA, Giatromanolaki A, Kazakos K, Verettas DA (2012) Mechanical characterization of bone graft substitute ceramic cements. *Injury* 43:266-271
6. Gladstone HB, McDermott MW, Cooke DD (1995) Implants for cranioplasty. *Otolaryngol Clin North Am* 28:381-400
7. Malis LI (1989) Titanium mesh and acrylic cranioplasty. *Neurosurgery* 25:351-355
8. Manson PN, Crawley WA, Hoopes JE (1986) Frontal cranioplasty: risk factors and choice of cranial vault reconstructive material. *Plast Reconstr Surg* 77:888-904
9. Marchac D, Greensmith A (2008) Long-term experience with methylmethacrylate cranioplasty in craniofacial surgery. *J Plast Reconstr Aesthet Surg* 61:744-752; discussion 753
10. Sanan A, Haines SJ (1997) Repairing holes in the head: a history of cranioplasty. *Neurosurgery* 40:588-603

**Fig. 1.** Video screen capture showing cutting of wire mesh to larger than the skull defect.




**Fig. 2.** Illustration from video showing how methyl methacrylate in a plastic bag is packed into skull defect.

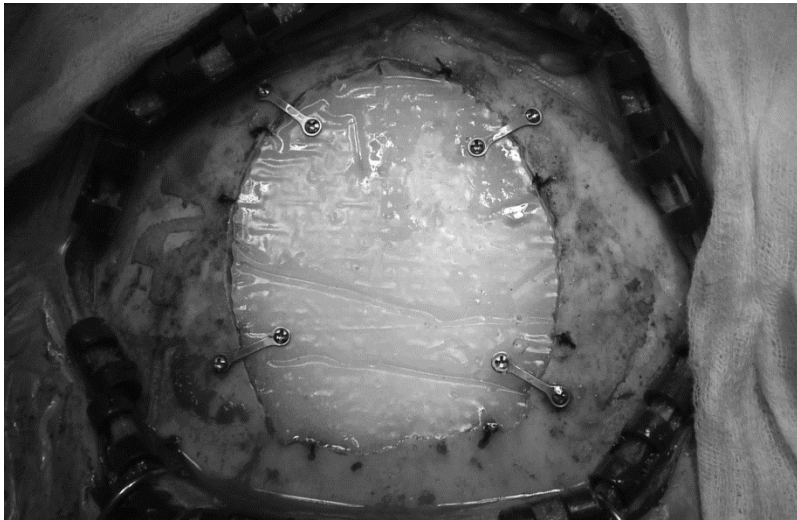


**Fig. 3.** Video screen capture showing wire mesh held in place over curing methyl methacrylate.

This ensures the implant will take the exact skull curvature.



**Fig. 4.** Video screen capture showing the custom flap held in position by titanium plates and mini-screws.



**Supplemental Video.** Video that demonstrates the cranioplasty technique that yields superior cosmesis through maintenance of the patient's calvarial curvature. 2 minutes, 50 seconds, 775 MB.

This video can be accessed under the supplementary material tab at the following link:

<http://link.springer.com/article/10.1007%2Fs00701-013-1800-3>