

Castleman disease of the spine mimicking a nerve sheath tumor

Case report

MICHAEL A. FINN, M.D., AND MEIC H. SCHMIDT, M.D.

Spinal Oncology Service, Department of Neurosurgery, Huntsman Cancer Institute, University of Utah, Salt Lake City, Utah

✓ Castleman disease is a rare lymphoproliferative disease of unknown cause. In most cases, afflicted patients present with a mediastinal mass although the disease may manifest in numerous other sites, including intracranially and rarely intraspinally. The authors report on the case of a 19-year-old woman who presented with a large paraspinal mass emanating from the T7–8 neural foramen. The morphological and signal characteristics revealed on magnetic resonance imaging were similar to those of nerve sheath tumors. The patient underwent open biopsy sampling of the lesion, and results of a pathological evaluation revealed hyaline-vascular type Castleman disease. She underwent radiotherapy and remains symptom-free with a radiographically stable lesion 1 year later. Although the disease has been reported to mimic a meningioma when encountered in intracranial locations, to the authors' knowledge, this is the first case of the disorder mimicking a nerve sheath tumor. When the diagnosis of Castleman disease is made, good results can be obtained with partial resection and radiotherapy.

KEY WORDS • Castleman disease • nerve sheath tumor • spine

CASTLEMAN disease is a rare lymphoproliferative condition of unknown cause that was first characterized by Castleman and colleagues in 1956;³ numerous cases have been described since. Although the disease is usually manifested as an isolated mass in the mediastinum, it can appear in diverse locations—most commonly the abdomen, neck, and axillae—or it may have a multifocal presentation with predominantly systemic symptoms.^{2,13,16,17,19,21,22} Along with its broad array of clinical presentations, the nomenclature for this abnormality has been wide ranging, with the condition being variably termed angiofollicular hyperplasia, localized nodal hyperplasia, giant lymph node hyperplasia, angiomatous lymphoid hamartoma, follicular lymphoreticuloma, and benign giant lymphoma.

The disease has two primary histological subtypes, the hyaline-vascular type and the plasma cell type. The hyaline-vascular type accounts for approximately 85 to 90% of all cases and is typically manifested by a localized lesion.^{17,20,22} The plasma cell type occurs in approximately 5 to 10% of cases and is most often a generalized or multifocal disease.^{17,22,26} There is also a mixed variant, with the histological characteristics of both primary subtypes, comprising the remaining cases.¹⁷

Central nervous system involvement in Castleman disease is exceedingly rare. To our knowledge, only 13 cases

of intracranial Castleman disease have been reported in the literature.^{4,5,11–13,18,21,27,31,33} When there is CNS involvement, the disease typically manifests as a dura mater–based lesion mimicking a meningioma. Patients often present with symptoms referable to the lesion location and are treated effectively with surgical excision. Castleman disease of the spine is a more rare entity, with only four previously reported cases.^{1,6,16,19} The patients with Castleman disease of the spine presented with myelopathic symptoms secondary to epidural disease in each case. All were treated effectively with surgical excision, which was complete in three of the four patients, and there were no signs of recurrence in the limited follow-up data provided.

We present a case of Castleman disease that manifested as a paraspinal mass extending through the neural foramen into the thoracic spine and mimicking a nerve sheath tumor. To our knowledge this is the first such case in the literature.

Case Report

History and Examination. This 19-year-old woman with no significant medical or surgical history was treated by her primary care provider for cough and intermittent nausea and vomiting of 3-weeks' duration. She received a diagnosis of bronchitis but presented to our institution when her symptoms did not resolve after a course of antibiotic medication. Chest radiographs were obtained and revealed a large right paraspinal mass (Fig. 1). On MR imaging a 6.2 × 6.8 × 6.1-cm heterogeneously enhancing mass was

Abbreviations used in this paper: CNS = central nervous system; MR = magnetic resonance.

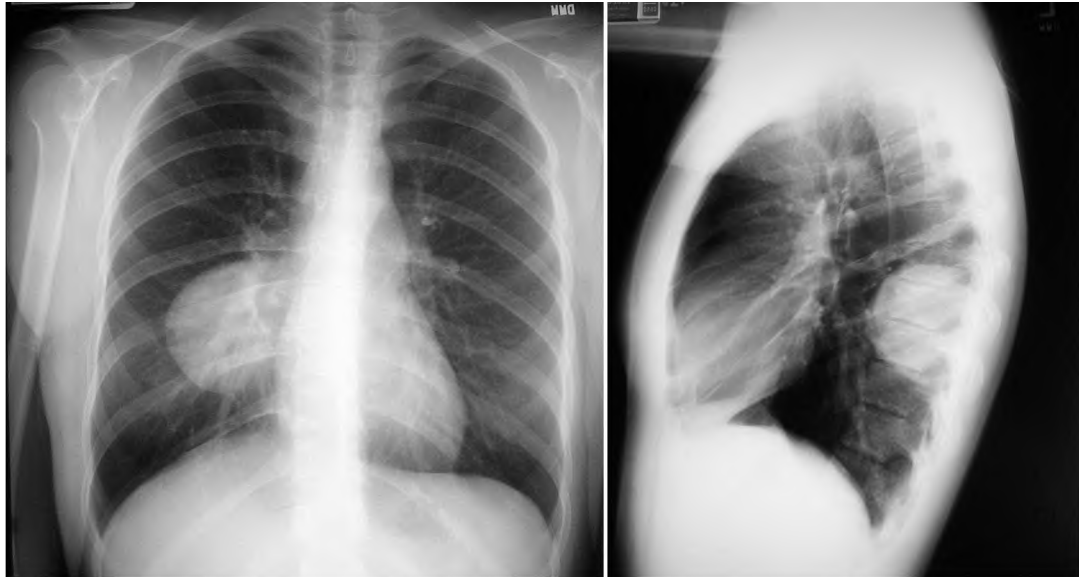


FIG. 1. Anteroposterior (left) and lateral (right) chest radiographs demonstrating a large paraspinal mass on the right.

noted in the right paraspinal region, extending into the right T7–8 neural foramen (Fig. 2). The mass was isointense relative to the spinal cord on T₁-weighted imaging and slightly hyperintense on T₂-weighted sequences. The neural foramen was not expanded. Schwannoma was considered the most likely diagnosis.

Operation and Pathological Findings. A right thoracotomy was performed in anticipation of complete resection. The tumor appeared fleshy and bled profusely when manipulated (Fig. 3). After a frozen section of a tissue sample obtained from the lesion revealed lymphoid tissue consistent with lymphoma, attempts at radical resection were aborted. Results of the final pathological examination revealed areas of focal sclerosis and dense lymphoid infiltrate with numerous lymphoid follicles (Fig. 4). Some of these follicles had small germinal centers and were surrounded by thickened mantle zones of small round lymphoid cells, some of which were arranged in onion bulb-shaped whorls. Occasional sclerotic blood vessels were noted to penetrate through the mantle zones. One follicle fragment was composed of small monomorphic round lymphocytes through which there ran numerous small hyalinized blood vessels and larger vascular structures with thick vessel walls. The results of flow cytometry revealed a mix of B and T cells with no evidence of monoclonality, leukemia, or non-Hodgkin lymphoma. The final diagnosis was hyaline-vascular type Castleman disease.

Postoperative Course. The patient recovered without complications and underwent radiotherapy (total dose 3960 cGy given in 22 fractions). She has tolerated this regime well and is currently asymptomatic with no evidence of lesion progression observed on radiographs obtained 1 year postoperatively.

Discussion

Castleman disease can present with either unicentric or

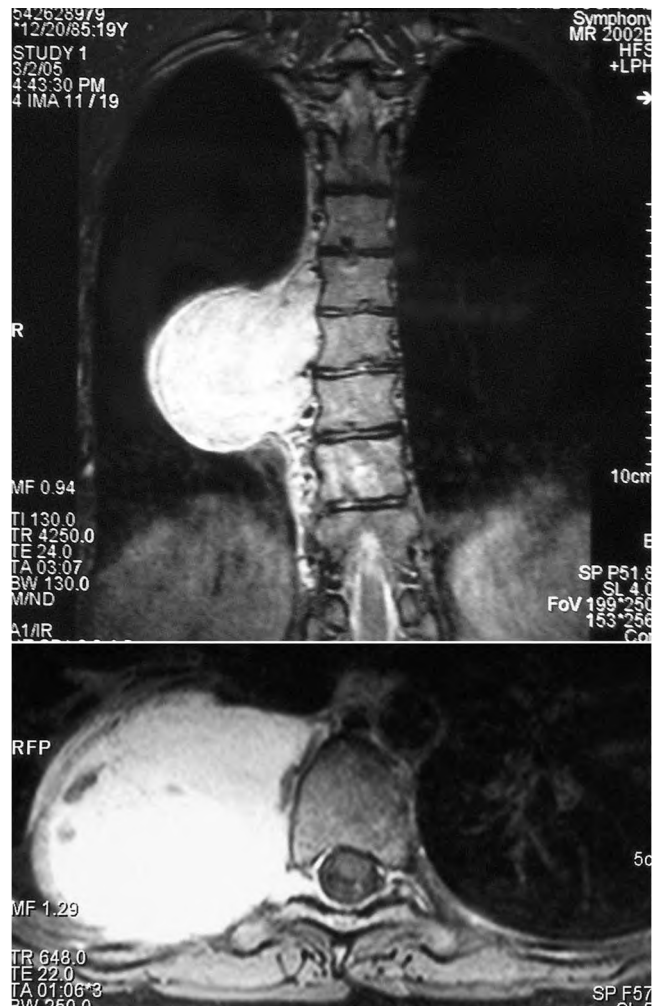


FIG. 2. Gadolinium-enhanced T₁-weighted coronal (upper) and axial (lower) MR images demonstrating a large heterogeneously enhancing mass extending from the neural foramen.

Castleman disease of the spine

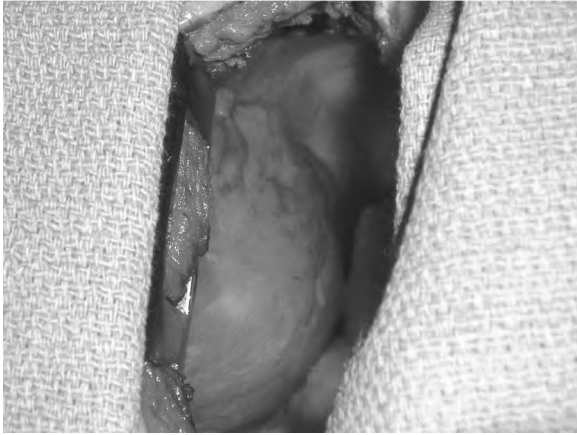

FIG. 3. Intraoperative photograph showing a large fleshy tumor in the thoracotomy defect.

multicentric type disease. Although the unicentric variety is most often of the hyaline-vascular subtype and the multicentric variety is mostly of the plasma cell variety, any combination may be present. The plasma cell variant is considered to be the most active and aggressive form of the illness; some authors have postulated that the hyaline-vascular subtype represents an end stage of the plasma cell type of disease.^{2,17}

The cause of Castleman disease is unknown, although numerous hypotheses have been put forth including infectious,¹⁷ hamartomatous,¹⁵ inflammatory,^{1,3} and autoimmune⁸ processes. Interestingly, an increased risk of non-Hodgkin lymphoma and Kaposi sarcoma has been reported in patients with Castleman disease and mandates vigilant surveillance.^{1,11} A thorough search for concurrent malignancies and attentive observation for future malignancies is thus warranted.

The most common form of Castleman disease is unicentric. Although it has a propensity to occur in the mediastinum it also commonly affects a variety of nodal and extranodal tissue in the abdomen, pelvis, neck, and axilla, and is most often asymptomatic and discovered incidentally.^{2,3,17,20} More rarely, and especially if the lesion has the histological characteristics of plasma cells, patients with unicentric Castleman disease may present with systemic symptoms and laboratory abnormalities including fever, weight loss, anemia, elevated erythrocyte sedimentation rate, and hypergammaglobulinemia.^{2,3,17,22} Treatment is largely centered on resection. Radical excision has been curative in most reports, although there have been reports of lesion recurrences up to 11 years postoperatively.^{2,17,24,32} The use of partial resection or observation only have also been reported, with only rare progression noted.^{2,17} Radiotherapy has been advocated but its use is controversial; some authors have reported a good or even complete response to treatment, and others have reported no response.^{2,17,30,34} Results of radiotherapy may be more favorable in patients with the plasma cell variant of the disease.²

Multicentric Castleman disease tends to affect an older population than does unilateral Castleman disease, and it is more often associated with systemic symptoms, abnormalities on laboratory tests, and abnormal examination findings including hepatosplenomegaly, adenopathy, and mo-

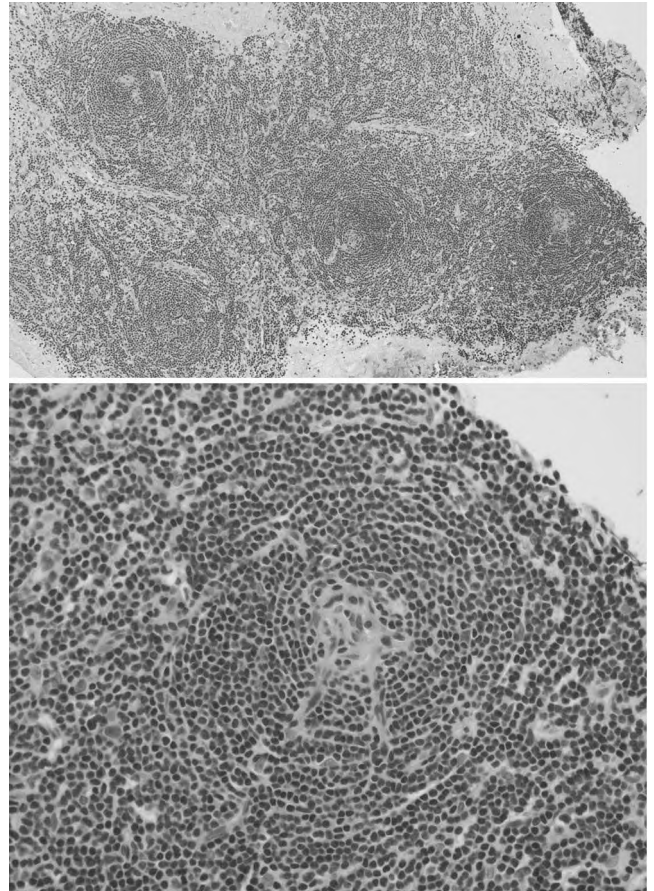


FIG. 4. Photomicrographs. *Upper:* Dense lymphoid infiltrate with lymphoid follicles, germinal centers, and onion bulb-shaped whorls are seen. *Lower:* Hyalinized blood vessel is demonstrated. H & E. Original magnifications $\times 10$ (*upper*) and $\times 40$ (*lower*).

tor-sensory neuropathy, with the latter portending a worse prognosis.^{2,7,17,23,26,28} Median survival durations as short as 26 months have been reported in the multicentric Castleman disease group, whereas patients with the hyaline-vascular variant may follow a more benign course and have better long-term survival rates.^{2,35} In either case, the clinical course may be variable. When the disease progresses rapidly, death usually results from sepsis.^{9,17,35} Surgical treatment for the multicentric disease is limited to biopsy sampling and debulking of a large mass only when symptoms are provoked.⁹ Definitive therapy for patients with Castleman disease relies on radiotherapy and chemotherapy, which have had mixed results.^{2,10,14,17,25,26}

Castleman disease is a diagnosis of exclusion, declared only after careful consideration of the more common causes of lymphadenopathy.²² Imaging is certainly a useful adjunct in the workup of the illness; however definitive preoperative diagnosis is not possible on imaging because the lesions display considerable variance in MR imaging signal characteristics.^{1,6,21} The diagnosis therefore depends on a combination of clinical, imaging, and histological data.

Castleman disease of the CNS is a rarely described entity. The 13 reported cases of intracranial Castleman disease have been summarized by Matsumura et al.²¹ Patients with the disease often present with seizures or focal neurologi-

cal signs, and on MR imaging an enhancing dura mater-based mass similar to a meningioma is revealed. A significant amount of perilesional edema out of proportion with what would normally be expected for the lesion's size is often present. Nine of the reported patients had the hyaline-vascular variant of the lesion, two had the plasma cell type, and two had a mixed type. All patients underwent surgery, which resulted in gross-total resection in all but two cases. The two patients who underwent partial resection and one of the patients who underwent gross-total resection received radiotherapy. There have been no reports of recurrence with follow-up monitoring reported for up to 8 years.

Spinal Castleman disease has been reported four times to occur as an extradural lesion in the cervical and thoracic region.^{1,6,16,19} All patients in these studies presented with signs of myelopathy. Three patients were treated with laminectomy and complete excision, and one patient underwent only partial excision. Three patients had hyaline-vascular type lesions and one had the plasma-cell variant. Follow up has been limited in these cases, but no lesion recurrence has been reported.

The case in the present study is unique in that the imaging characteristics of the mass were similar to those of a schwannoma. Schwannomas of the spine often originate in the spinal canal and can extend through the neural foramen into the paraspinal space. Most schwannomas enhance sharply on MR imaging after Gd administration, and frequently demonstrate iso- to hypointense signal characteristics on T₁-weighted images and hyperintense signal characteristics on T₂-weighted imaging sequences. The lesion in our patient enhanced on T₁- and T₂-weighted imaging with signal characteristics consistent with a spinal schwannoma. Spinal schwannomas may also cause bone abnormalities in the adjacent structures, including narrowing of the pedicle, enlargement of the intervertebral foramen, and scalloping of the vertebral body.²⁰ Our patient's bones remained normal, but osseous damage is not a universal finding in patients with schwannomas. The imaging characteristics in our patient were thus consistent with the more common diagnosis of schwannoma.

Our patient presented with symptoms suggestive of bronchitis, which were probably unrelated to the tumor's location. Although only partial resection was undertaken in our patient, her symptoms resolved postoperatively. She has tolerated radiotherapy well and has shown no sign of tumor progression or symptom recurrence in 1 year of follow-up monitoring. We plan further follow up with biannual imaging studies and will consider reexploration and surgical debulking if any evidence of progression is demonstrated.

In summary, Castleman disease is a rare lymphoproliferative disorder that rarely affects the CNS. We report on an unusual case in which the lesion mimicked a nerve sheath tumor. The lesion in this patient remains stable after an open excisional biopsy procedure and radiotherapy.

Acknowledgment

We thank Kristin Kraus for her editorial assistance in preparing this manuscript.

References

- Alper G, Crumrine PK, Hamilton RL, Albright AL, Wald ER:

- Unusual case of inflammatory spinal epidural mass (Castleman syndrome). *Pediatr Neurol* **15**:60–62, 1996
- Bowne WB, Lewis JJ, Filippa DA, Niesvizky R, Brooks AD, Burt ME, et al: The management of unicentric and multicentric Castleman's disease: a report of 16 cases and a review of the literature. *Cancer* **85**:706–717, 1999
- Castleman B, Iverson L, Menendez VP: Localized mediastinal lymphnode hyperplasia resembling thymoma. *Cancer* **9**:822–830, 1956
- Cummings TJ, Gong JZ, Friedman AH, McLendon RE: Castleman's disease confined to the leptomeninges. *Ann Clin Lab Sci* **30**:278–282, 2000
- Delmont E, Lonjon M, Michiels JF, Chanalet S, Bourg V, Xerri L, et al: [Castleman's disease located in the central nervous system.] *Rev Neurol (Paris)* **159**:581–585, 2003 (Fr)
- Eisenstat R, Price D, Rosenthal A, Schuss A, Katz D: Thoracic epidural Castleman's disease. *AJR Am J Roentgenol* **178**:208–210, 2002
- Feigert JM, Sweet DL, Coleman M, Variakojis D, Wisch N, Schulman J, et al: Multicentric angiofollicular lymph node hyperplasia with peripheral neuropathy, pseudotumor cerebri, IgA dysproteinemia, and thrombocytosis in women. A distinct syndrome. *Ann Intern Med* **113**:362–367, 1990
- Frizzera G: Castleman's disease: more questions than answers. *Hum Pathol* **16**:202–205, 1985
- Frizzera G, Peterson BA, Bayrd ED, Goldman A: A systemic lymphoproliferative disorder with morphologic features of Castleman's disease: clinical findings and clinicopathologic correlations in 15 patients. *J Clin Oncol* **3**:1202–1216, 1985
- Gaba AR, Stein RS, Sweet DL, Variakojis D: Multicentric giant lymph node hyperplasia. *Am J Clin Pathol* **69**:86–90, 1978
- Gianaris PG, Leestma JE, Cerullo LJ, Butler A: Castleman's disease manifesting in the central nervous system: case report with immunological studies. *Neurosurgery* **24**:608–613, 1989
- Gulati P, Sun NC, Herman BK, Said JW, Cornford ME: Isolated leptomeningeal Castleman's disease with viral particles in the follicular dendritic cells. *Arch Pathol Lab Med* **122**:1026–1029, 1998
- Hashimoto H, Iida J, Hironaka Y, Sakaki T: Intracranial Castleman's disease of solitary form. Case report. *J Neurosurg* **90**:563–566, 1999
- Herrada J, Cabanillas FF: Multicentric Castleman's disease. *Am J Clin Oncol* **18**:180–183, 1995
- Hsu SM, Waldron JA, Xie SS, Barlogie B: Expression of interleukin-6 in Castleman's disease. *Hum Pathol* **24**:833–839, 1993
- Kachur E, Ang LC, Megyesi JF: Castleman's disease and spinal cord compression: case report. *Neurosurgery* **50**:399–403, 2002
- Keller AR, Hochholzer L, Castleman B: Hyaline-vascular and plasma-cell types of giant lymph node hyperplasia of the mediastinum and other locations. *Cancer* **29**:670–683, 1972
- Lacombe MJ, Poirier J, Caron JP: Intracranial lesion resembling giant lymph node hyperplasia. *Am J Clin Pathol* **80**:721–723, 1983
- Lee HY, Lee SH, Kim SN: Castleman's disease: unusual case of inflammatory spinal dorsal epidural mass: case report. *Neurosurgery* **50**:396–398, 2002
- Martin JM, Bell B, Ruether BA: Giant lymph node hyperplasia (Castleman's disease) of hyaline vascular type. Clinical heterogeneity with immunohistologic uniformity. *Am J Clin Pathol* **84**:439–446, 1985
- Matsumura K, Nakasu S, Tanaka T, Nioka H, Matsuda M: Intracranial localized Castleman's disease. Case report. *Neuro Med Chir (Tokyo)* **45**:59–65, 2005
- McCarty MJ, Vukelja SJ, Banks PM, Weiss RB: Angiofollicular lymph node hyperplasia (Castleman's disease). *Cancer Treat Rev* **21**:291–310, 1995
- Menke DM, Camoriano JK, Banks PM: Angiofollicular lymph node hyperplasia: a comparison of unicentric, multicentric,

Castleman disease of the spine

- hyaline vascular, and plasma cell types of disease by morphometric and clinical analysis. **Mod Pathol** **5**:525–530, 1992
24. Olscamp G, Weisbrod G, Sanders D, Delarue N, Mustard R: Castleman disease: unusual manifestations of an unusual disorder. **Radiology** **135**:43–48, 1980
 25. Pavlidis NA, Skopouli FN, Bai MC, Bourantas CL: A successfully treated case of multicentric angiofollicular hyperplasia with oral chemotherapy (Castleman's disease). **Med Pediatr Oncol** **18**:333–335, 1990
 26. Peterson BA, Frizzera G: Multicentric Castleman's disease. **Semin Oncol** **20**:636–647, 1993
 27. Ropponen KM, Kankkunen JP, Ronkainen A, Vihavainen M, Alafuzoff I: Castleman's disease of the leptomeninges—immunohistochemical findings in 2 cases. **Clin Neuropathol** **21**:278–283, 2002
 28. Scherokman B, Vukelja SJ, May E: Angiofollicular lymph node hyperplasia and peripheral neuropathy. Case report and literature review. **Arch Intern Med** **151**:789–790, 1991
 29. Seppala MT, Haltia MJ, Sankila RJ, Jaaskelainen JE, Heiskanen O: Long-term outcome after removal of spinal schwannoma: a clinicopathological study of 187 cases. **J Neurosurg** **83**:621–626, 1995
 30. Sethi T, Joshi K, Sharma SC, Gupta BD: Radiation therapy in the management of giant lymph node hyperplasia. **Br J Radiol** **63**:648–650, 1990
 31. Severson GS, Harrington DS, Weisenburger DD, McComb RD, Casey JH, Gelber BR, et al: Castleman's disease of the leptomeninges. Report of three cases. **J Neurosurg** **69**:283–286, 1988
 32. Shahidi H, Myers JL, Kvale PA: Castleman's disease. **Mayo Clin Proc** **70**:969–977, 1995
 33. Sotrel A, Castellano-Sanchez AA, Prusmack C, Birchansky S, Brathwaite C, Ragheb J: Castleman's disease in a child presenting with a partly mineralized solitary meningeal mass. **Pediatr Neurosurg** **38**:232–237, 2003
 34. Weisenburger DD, DeGowin RL, Gibson P, Armitage JO: Remission of giant lymph node hyperplasia with anemia after radiotherapy. **Cancer** **44**:457–462, 1979
 35. Weisenburger DD, Nathwani BN, Winberg CD, Rappaport H: Multicentric angiofollicular lymph node hyperplasia: a clinicopathologic study of 16 cases. **Hum Pathol** **16**:162–172, 1985

Manuscript submitted November 1, 2006.

Accepted January 15, 2007.

Address reprint requests to: Meic H. Schmidt, M.D., Department of Neurosurgery, University of Utah Health Sciences Center, 175 North Medical Drive East, Salt Lake City, Utah 84132-2303. email: meic.schmidt@hsc.utah.edu.