

# The high incidence of tumor dissemination in myxopapillary ependymoma in pediatric patients

## Report of five cases and review of the literature

DANIEL R. FASSETT, M.D., JAMES PINGREE, M.D., AND JOHN R. W. KESTLE, M.D.

*Department of Neurosurgery, University of Utah School of Medicine; Division of Pediatric Neurosurgery, Primary Children's Medical Center, University of Utah; and Department of Neurosurgery, St. Mark's Hospital, Salt Lake City, Utah*

Myxopapillary ependymomas (MPEs) have historically been thought to be benign tumors occurring most frequently in adults. Only 8 to 20% of these tumors occur in the first two decades of life, making this tumor a rarity in pediatric neurosurgery. Five patients with intraspinal MPEs were treated by the authors between 1992 and 2003. Four (80%) of these five patients suffered from disseminated disease of the central nervous system (CNS) at the time of presentation; this incidence is much higher than that reported in the combined adult and pediatric literature.

Combining five pediatric case series reported in the literature with the present series, the authors review a total of 26 cases of pediatric patients with intraspinal MPEs. In nine cases (35%) CNS metastases occurred. In those cases in which patients underwent screening for CNS tumor dissemination, however, the incidence of disseminated disease was 58% (seven of 12 patients).

In pediatric patients MPEs may spread throughout the CNS via cerebrospinal fluid pathways; therefore, MR imaging of the entire CNS axis is recommended at both presentation and follow-up review to detect tumor dissemination.

**KEY WORDS** • myxopapillary • ependymoma • dissemination • pediatric neurosurgery

**M**YXOPAPILLARY ependymoma, a histological subtype of ependymoma, most commonly appears in the fourth decade of life; only 8 to 20% of these tumors occur in the pediatric population.<sup>2,11,12</sup> The vast majority of these lesions appear in the lumbar thecal sac in association with the conus medullaris, cauda equina, or filum terminal.<sup>1,12</sup> Less than 5% of MPEs occur as primary tumors in sites outside the lumbar thecal sac; however, primary tumors of the cervical cord, brain, and osseous sacrum have been reported.<sup>6,12</sup>

On MR images, these tumors typically appear as a homogeneously enhancing sausage-shaped mass in the lumbar thecal sac (Fig. 1), with hyperintensity on T<sub>1</sub>-weighted images resulting from the intracellular and perivascular accumulation of mucin.<sup>3</sup>

Historically, MPEs have been considered benign tumors characterized by slow growth and a low likelihood for tumor dissemination.<sup>11,13</sup> They are known to recur locally, but prior to the MR imaging era metastases were considered rare. Only six cases of metastases were reported in the liter-

ature before 1996.<sup>14</sup> Most reported cases of metastases have occurred within the CNS, but extraneural metastases have also been reported.<sup>10</sup>

During an 11-year period from 1992 to 2003, five cases of intradural MPE were treated at our institution. In four of the five patients metastatic disease was already apparent at the time of presentation. The patients included four boys and one girl who ranged in age from 7 to 14 years. All patients presented with back pain and four with radicular pain in the lower extremities. Resection was performed in each patient and histologically confirmed MPE was diagnosed in every case. All of the patients in our series underwent perioperative MR imaging, which included the entire cranial spinal axis in four patients and images of the entire spine in one. We have combined our series of patients with pediatric series in the literature that included three or more patients to investigate the incidence of tumor spread in pediatric patients with MPE.

### Case Reports

#### Case 1

This 13-year-old girl presented with a 7-month history of progressive low-back and leg pain. She reported no numb-

Abbreviations used in this paper: CNS = central nervous system; CSF = cerebrospinal fluid; MPE = myxopapillary ependymoma; MR = magnetic resonance.

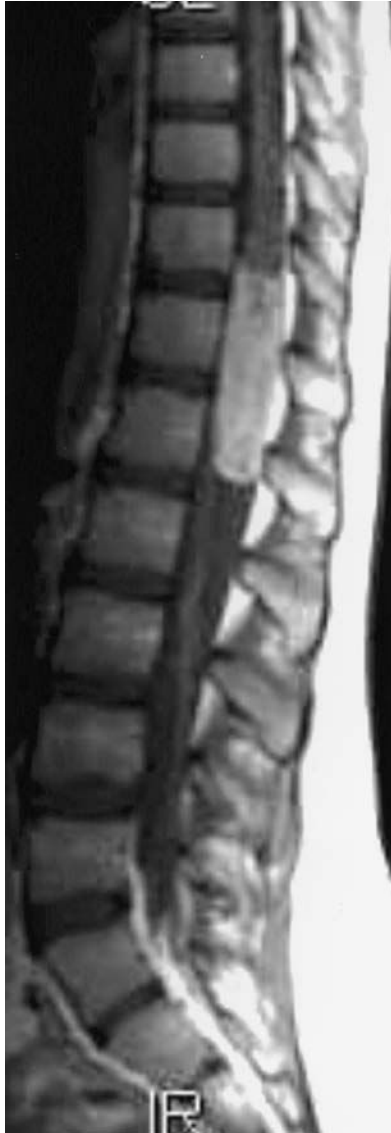

FIG. 1. Case 1. Preoperative MR image demonstrating a homogeneously enhancing primary tumor at the level of the conus medullaris (T11–L2) at the time of the initial presentation.

ness or weakness and had been treated with analgesic agents, which provided no relief. An MR image demonstrated a homogeneously enhancing sausage-shaped mass extending from T-11 to L-2 and enhancing sediment at the bottom of the thecal sac (Fig. 1). Preoperatively, MR images had been obtained in only the thoracic and lumbar spine. With the exception of an upgoing right toe the patient was neurologically intact. Resection of the primary tumor, including a T10–L2 laminoplasty and en bloc removal of the tumor for gross-total resection, was performed. The drop metastases in the distal thecal sac were not addressed surgically. Histopathological findings confirmed the diagnosis of MPE. Postoperative neurological examination revealed no change in her condition. On postoperative Day 1, an MR image of the entire CNS axis demonstrated gross-total tumor resection of the primary tumor mass, no evidence of cervical or intracranial disease, and residual drop

metastases in the distal thecal sac. The patient was treated with radiation therapy (4450 cGy) in the lower thoracic and lumbosacral spine, including an extra dose targeted at the sacral drop metastases; the total dosage was 5250 cGy. Follow-up MR imaging at 3 months after radiation therapy revealed no evidence of residual disease. The results of MR surveillance imaging remained nondiagnostic for 30 months, but 3 years after the initial surgery the patient began to experience headaches and MR imaging demonstrated enhancing lesions in the supracellar cistern and fourth ventricles (Fig. 2), with no evidence of spinal disease. Craniospinal radiation therapy (3960 cGy) was administered with an extra dose to the intracranial lesions (5420 cGy to each lesion by using stereotactic intensity-modulated radiation therapy). The intracranial lesions appeared slightly smaller at the 15-month follow-up examination.

#### Case 2

This 14-year-old boy presented with 1 year of progressive low-back pain that included no radiating pain, numbness, weakness, or sphincter dysfunction. An MR imaging examination revealed an enhancing mass from T-11 to L-3 as well as metastases in the cervicothoracic spinal cord and brainstem. Results of the patient's neurological examination were normal. A gross-total resection (T11–L3) of the primary lesion was performed, and histopathological findings confirmed the diagnosis of MPE. Postoperatively the patient remained neurologically intact. The disseminated disease was subsequently treated with craniospinal radiation therapy (5086 cGy), and at the 5-year follow-up examination no residual disease was demonstrated on MR imaging.

#### Case 3

This 14-year-old boy presented with a 6-year history of progressive back pain, including nocturnal back pain, and a 1-year history of pain radiating into both legs. He reported no motor, sensory, bowel, or bladder dysfunction. An MR imaging examination of the entire CNS revealed a 4-cm enhancing mass just below the conus medullaris and metastases on the thoracic cord, conus medullaris, and caudal thecal sac. The patient's neurological examination was normal with the exception of symmetric hyperreflexia in the lower extremities. He was treated with staged surgical procedures. The first was a laminectomy from L-2 to S-2, with subtotal resection of the large mass in the conus medullaris, which was performed in a piecemeal fashion. Small amounts of tumor that were adherent to multiple nerve roots were left intact. Two weeks after his initial surgery the patient underwent a second procedure to resect focal metastases at the level of T-5 to T-6. Histopathological studies from both surgeries confirmed the diagnosis of MPE. The boy was then treated with radiation therapy (4600 cGy) to the entire thoracic, lumbar, and sacral spine. At the last follow-up examination, conducted 3.5 years posttreatment, no residual disease was apparent.

#### Case 4

This 7-year-old boy presented with progressive back pain that worsened rapidly during a 2-week period. The pain became so severe that he was unable to walk, sit, or

## Myxopapillary ependymoma

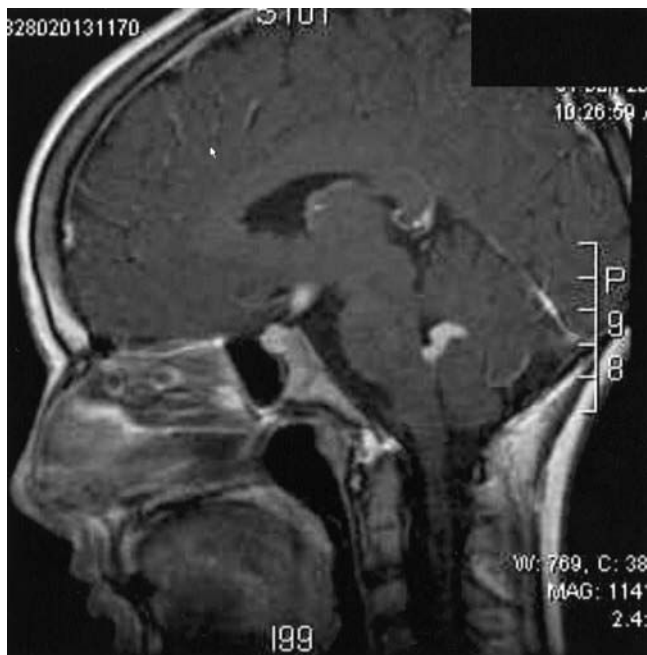


FIG. 2. Case 1. Magnetic resonance image demonstrating enhancing lesions in the third and fourth ventricles found 3 years postsurgery.

stand without discomfort. No bowel or bladder symptoms were reported. An MR image revealed an enhancing  $3 \times 2 \times 2$ -cm intradural hemorrhagic mass just below the conus. An MR imaging examination of other areas of the CNS was not performed preoperatively. Physical examination revealed mild proximal weakness in both legs and decreased sensation to pinprick below L-2. The patient underwent T12–L2 laminoplasty and en bloc resection of the mass. Histopathological findings confirmed the diagnosis of MPE. After surgery the boy's strength and sensation gradually returned to normal. An MR imaging examination of his entire spine 1 month after surgery demonstrated no evidence of disease. The patient did not undergo adjuvant therapy, and he was healthy and active with no apparent disease at the last follow-up examination conducted 7 years postoperatively.

### Case 5

This 8-year-old boy presented with a 2-month history of progressive low-back pain that radiated into his thighs. The pain increased significantly when he bent forward. During the 10 days prior to his admission the boy had difficulty walking, which resulted from pain, and he experienced urinary urgency with occasional episodes of incontinence. An MR imaging examination demonstrated an enhancing intradural mass distal to the conus from L-2 to L-3 and an enhancement of the distal conus distinct from the main mass, which was believed to be a sign of drop metastases. Physical examination revealed normal motor function, dysesthetic pain in the thighs as a response to light touch, and an absence of reflexes at the ankle and knee bilaterally. A subtotal resection was performed because of the dense adherence of tumor to nerve roots. Histopathological studies confirmed the diagnosis of MPE. Postoperatively, the pa-

tient suffered no new neurological deficits, and urinary function and sensation returned to normal. Lower-extremity reflexes returned with the exception of the left Achilles reflex. The boy underwent radiation therapy (4500 cGy) from T-11 to S-5, including an additional dose from L-1 to L-3, resulting in a total dosage of 5400 cGy. He remains neurologically stable 4.5 years after treatment. There is a small area of enhancement at the tip of the conus that has demonstrated no changes on MR imaging examinations.

### Combined Results From the Pediatric MPE Series

The five patients from our series were combined with 21 patients from five series from the literature to yield a total of 26 patients (Table 1).<sup>1,2,5,8,11</sup> Patient age ranged from 5 to 17 years (mean 11.1 years). Seventeen boys and nine girls are included, resulting in a male/female ratio of 1.89:1, a ratio similar to the mean ratio in adult series in the literature.<sup>10</sup> Twenty-two of the patients suffered from primary disease in the lumbar thecal sac, one from primary tumor in the cervical cord,<sup>5</sup> and three from primary tumors the locations of which were not reported.

Nine of the 26 patients experienced CNS tumor dissemination at some point in the history of their disease. Seven cases of CNS metastases occurred at the time of presentation and two during the follow-up period. Note that only 12 of the 26 patients were reported to have undergone perioperative screening for metastasis by using either MR imaging or CSF cytology. The authors of the three case series published before 1994, comprising 14 patients, did not report any screening measures used to identify dissemination in the perioperative period. In the three case series published after 1994 screening measures for tumor dissemination were reported. The incidence of tumor dissemination in the three series before 1994 (no screening for dissemination) was 14% and both of the cases in which dissemination was present were found in the late follow-up period—more than 3.5 years after surgery. The incidence of dissemination in the three series that included perioperative screening was 58%, and all cases of dissemination were found at the patient's initial presentation. One patient in our series who was at the time of presentation found to be suffering from disseminated disease in her spine was treated with radiation therapy and experienced an excellent response to therapy. Subsequently late intracranial metastases developed; these were treated with further radiation therapy.

The initial treatment for all patients was resection of the primary lesion. Whenever possible, the lesion was removed en bloc to minimize the chance of dissemination. Postsurgically, patients who underwent subtotal resection were treated using local radiotherapy; patients suffering from metastatic lesions were treated with involved-field radiotherapy.

There were 14 patients without metastatic disease at presentation who underwent gross-total resection of their lesions. Eleven of these patients did not undergo adjuvant radiotherapy. Two experienced local recurrence and two others late disseminated disease. Of the three patients who underwent gross-total resection and adjuvant radiation therapy, none experienced recurrence. There were five other patients without metastases at presentation who underwent subtotal resection. Four of them who were treat-

TABLE 1  
Summary of reported cases of MPEs in pediatric patients\*

Authors & Year	Age (yrs), Sex	Location	Periop Evaluation for Metastasis	Tumor Dissemination (time frame/location)	Recurrence	Treatment†	Disease Status at Last Follow Up
Chan, et al., 1984	9, M	CCF	unknown	late/cranial	dissemination	GTR/RT <sup>2</sup>	NAD
	9, M	CCF	unknown	late/cranial	dissemination	GTR/RT <sup>2</sup>	NAD
	13, M	CCF	unknown	none	local	GTR/reop	NAD
	11, M	CCF	unknown	none	none	STR/RT <sup>1</sup>	NAD
	8, F	CCF	unknown	none	none	GTR	NAD
	13, M	CCF	unknown	none	none	STR/RT <sup>1</sup>	NAD
	10, F	CCF	unknown	none	none	GTR	NAD
Gagliardi, et al., 1993	14, M	CCF	unknown	none	none	GTR	NAD
	13, F	CCF	unknown	none	local	STR/reop	NAD
	14, M	CCF	unknown	none	none	GTR	NAD
	13, M	CCF	unknown	none	none	STR/RT <sup>1</sup>	NAD
Ross, et al., 1993	11, F	not reported	unknown	none	none	GTR/RT <sup>1</sup>	NAD
	12, M	not reported	unknown	none	none	GTR/RT <sup>1</sup>	NAD
	9, M	not reported	unknown	none	none	GTR/RT <sup>1</sup>	NAD
Nagib & O'Fallon, 1997	5, F	CCF	postop MR imaging	none	none	GTR	NAD
	8, M	CCF	postop MR imaging	none	local	GTR/RT <sup>2</sup>	NAD
	13, F	CCF	postop MR imaging	none	none	GTR	NAD
Merchant, et al., 2000	12, M	CCF	MRI & CSF cytology	presentation/spinal	none	STR/chemo/RT <sup>1</sup>	DOC
	8, F	cervical	MRI & CSF cytology	presentation/spinal	none	STR/chemo/RT <sup>1</sup>	NAD
	17, M	CCF	MRI & CSF cytology	presentation/spinal	none	STR/RT <sup>1</sup>	st dis
	8, F	CCF	MRI & CSF cytology	none	none	STR/RT <sup>1</sup>	NAD
present series	14, M	CCF	preop MRI	presentation/spinal	none	STR/RT <sup>1</sup>	NAD
	14, M	CCF	preop MRI	presentation/cranial & spinal	none	GTR/RT <sup>1</sup>	NAD
	8, M	CCF	preop MRI	presentation/spinal	none	STR/RT <sup>1</sup>	NAD
	13, F	CCF	pre- & postop MRI	spinal at presentation & late cranial	none	GTR/RT <sup>1</sup> /RT <sup>2</sup>	st dis
	7, M	CCF	preop MRI (spine only)	none	none	GTR	NAD

\* CCF = lesion in the conus medullaris, cauda equina, or terminal filum; chemo = chemotherapy; DOC = died of other causes; GTR = gross-total resection; NAD = no apparent disease; RT<sup>1</sup> = radiation therapy given during the perioperative period as adjuvant therapy; RT<sup>2</sup> = radiation therapy used to treat late recurrence (local or disseminated disease); st dis = stable disease; STR = subtotal resection.

† The terms gross-total resection and subtotal resection apply only to the primary tumor mass; CNS metastases may still be present.

ed with adjuvant radiotherapy did not experience a recurrence; however, a recurrence developed in the one who was not treated with adjuvant radiotherapy.

Seven patients were suffering from known metastases at presentation; two underwent gross-total resection of the primary lesion and adjuvant radiotherapy to the metastatic sites. One of these two patients later experienced cranial metastases outside the radiotherapy field. The five patients with known metastases at presentation who underwent subtotal resection of the primary lesion were treated with radiotherapy, and two were also treated with chemotherapy. Recurrent disease did not develop in any of these patients.

A total of 11 patients were treated with radiotherapy for either subtotal resection or metastatic disease that was evident at presentation. Only the patient with a cranial metastasis outside the field (spinal) of radiotherapy experienced progressive disease. Twelve patients did not receive radiotherapy at the time of the initial treatment; 11 of these patients underwent gross-total resection and one a subtotal resection. The patient who underwent subtotal resection experienced a recurrence. Progressive disease developed in four of the 11 patients who underwent gross-total resection: two experienced localized recurrence and two suffered from disseminated disease.

The follow-up period ranged from 2 months to 21 years with a mean of 6.1 years. At the time of the last reported follow-up examination, 23 patients demonstrated no appar-

ent residual disease, two had stable disease, and one patient had died of other causes. No patient suffered uncontrolled tumors or died as a result of a tumor.

## Discussion

### Incidence of Dissemination

Myxopapillary ependymomas have historically been considered benign tumors with rare cases of tumor dissemination; only six cases of disseminated MPE were reported in the literature prior to 1996.<sup>14</sup> Since the advent of MR imaging, reported cases of tumor dissemination have increased significantly.

In 1984 Chan, et al.,<sup>1</sup> reviewed a series of seven pediatric patients younger than 13 years of age who were suffering from MPEs; two experienced tumor dissemination 3.5 and 4.5 years after resection, respectively. Note that no patient in the series underwent perioperative screening of the CNS axis or CSF cytology screening to detect tumor dissemination. It is unclear, therefore, whether the metastases were present at the time of the initial evaluation or whether they represent disease progression.

In 1996 Rezai, et al.,<sup>9</sup> reported a series of 140 adult and pediatric patients with ependymomas of the CNS. Included were at least eight patients with MPEs; investigations revealed a 33% incidence of tumor dissemination at the 5-

## Myxopapillary ependymoma

year follow up in the patients suffering from MPEs. Interestingly, in the patients with MPEs the investigators reported no case of dissemination evident at the time of initial presentation or during the first 3 years of the follow-up period. Whether these patients received perioperative screening for tumor dissemination and the means by which the disseminated disease was detected—as an incidental finding on follow-up MR imaging examinations or as a clinical finding—are unclear in the paper. In the case reported by Chan, et al.,<sup>1</sup> it is unclear whether these cases of late dissemination represent clinically latent disease that was present but undetected at the time of initial evaluation or instances of seeding at the time of surgery.

In 1999 Merchant, et al.,<sup>5</sup> reported 25 cases of spinal cord tumors in pediatric patients. Four of these cases involved MPEs, including one case of a cervical cord primary lesion. All patients underwent perioperative screening for subarachnoid metastasis and, based on the findings of MR imaging or CSF cytology, dissemination was noted in three of the four cases.

In our series of five patients, the tumor dissemination incidence of 80% at the time of the initial evaluation is consistent with the finding of Merchant and colleagues.<sup>5</sup> When all case series in which patients underwent perioperative screening for dissemination are combined, the incidence of dissemination is 58%. The lower incidence of dissemination reported in the papers published prior to 1994 probably reflects the difficulty in obtaining complete CNS images.

### *Treatment of Primary and Disseminated Disease*

Primary lesions in the lumbar thecal sac are almost always treated surgically, and the surgeon's goal is generally gross-total resection. When subtotal resection is performed, it is usually followed by radiotherapy; this combined approach had demonstrated very good disease control. Our results and an analysis of the literature support the use of radiotherapy in cases of subtotal resection. Of 10 patients who underwent subtotal resection, nine underwent postoperative radiotherapy and there were no tumor recurrences in this group. One patient did not undergo radiotherapy and was noted to have suffered disease progression. An analysis of the findings in adult series also indicates that radiation therapy improves outcomes in cases of subtotal resection or metastases.<sup>12</sup> The efficacy of radiation therapy in cases of gross-total resection is less clear. In this review, 11 patients underwent gross-total resection without adjuvant therapy. Four subsequently suffered progressive disease; two experienced a local recurrence and two metastatic disease. Were these patients to have been treated with radiotherapy, the treatment would most likely have been localized; therefore, it is questionable whether the disseminated disease could have been prevented. The two local recurrences that developed after gross-total resection had been performed might have been prevented by the administration of adjuvant radiotherapy; however, these lesions were controlled very well when radiotherapy was administered at the time of recurrence.

Because of the effectiveness of surgery and radiation therapy, chemotherapy has been used rarely in young children with ependymomas or for the treatment of tumors that are refractory to radiation therapy.<sup>4</sup>

### *Outcomes for Patients With MPEs*

Despite the relatively high rate of tumor dissemination, MPEs appear to be characterized by a benign course and good long-term survival. In the patients in our series surgery and radiation therapy as needed for cases of metastases effectively controlled dissemination. Effective tumor control was likewise evident in pediatric series in the literature; there are no deaths reported in the pediatric series as a result of tumor. The mean follow-up period is only 6.4 years in this combined case series, however, and this limits conclusions regarding long-term outcome. In all cases either residual disease or stable disease was reported.

Other series comprising adult and pediatric patients confirm good long-term survival rates. Mork and Loken<sup>7</sup> reported 100% survival in nine patients with MPE who were treated surgically; long-term follow up ranged from 5 to 22 years. Sonneland, et al.,<sup>12</sup> described 77 cases of patients with MPEs treated at the Mayo clinic during a 60-year period. A mortality rate of 6.5% was associated with the MPEs; all deaths occurred after a prolonged course of treatment and multiple recurrences. En bloc tumor removal was associated with a decreased risk for tumor recurrence in comparison with total resection accomplished in a piecemeal fashion (10% compared with 34%). Total removal of tumor, by either en bloc or piecemeal resection, was associated with longer survival in comparison with subtotal resection (19 years compared with 14 years).

## Conclusions

In view of the cases reported here and in the recent literature, the incidence of CNS dissemination of MPEs appears to be higher than previously thought; this is true at the time of diagnosis and during follow up. Screening of the entire CNS axis at the time of diagnosis and during follow up is therefore recommended. The limited data on treatment for this lesion indicate that radiotherapy is efficacious for residual tumor following subtotal resection and for metastatic disease. Long-term survival has been documented; however, continued follow up of patients with MPEs is warranted.

## References

1. Chan HS, Becker LE, Hoffman HJ, Humphreys RP, Hendrick EB, Fitz CR, et al: Myxopapillary ependymoma of the filum terminale and cauda equina in childhood: report of seven cases and review of the literature. *Neurosurgery* **14**:204–210, 1984
2. Gagliardi FM, Cervoni L, Domenicucci M, Celli P, Salvati M: Ependymomas of the filum terminale in childhood: report of four cases and review of literature. *Childs Nerv Syst* **9**:3–6, 1993
3. Kahan H, Sklar EM, Post MJ, Bruce JH: MR characteristics of histopathologic subtypes of spinal ependymoma. *AJNR Am J Neuroradiol* **17**:143–150, 1996
4. Madden JR, Fenton LZ, Weil M, Winston KR, Partington M, Foreman NK: Experience with tamoxifen/etoposide in the treatment of a child with myxopapillary ependymoma. *Med Pediatr Oncol* **37**:67–69, 2001
5. Merchant TE, Kiehna EN, Thompson SJ, Heideman R, Sanford RA, Kum LE: Pediatric low-grade and ependymal spinal cord tumors. *Pediatr Neurosurg* **32**:30–36, 2000
6. Miralbell R, Louis DN, O'Keefe D, Rosinberg AE, Suit HD:

- Metastatic ependymoma of the sacrum. **Cancer** **65**:2353–2355, 1990
7. Mork SJ, Loken AC: Ependymoma: a follow-up study of 101 cases. **Cancer** **40**:907–915, 1977
  8. Nagib MG, O’Fallon MT: Myxopapillary ependymoma of the conus medullaris and filum terminale in the pediatric age group. **Pediatr Neurosurg** **26**:2–7, 1997
  9. Rezai AR, Woo HH, Lee M, Cohen H, Zagzag D, Epstein FJ: Disseminated ependymomas of the central nervous system. **J Neurosurg** **85**:618–624, 1996
  10. Rickert CH, Kedziora O, Gullotta F: Ependymoma of the cauda equina. **Acta Neurochir** **141**:781–782, 1999
  11. Ross DA, McKeever PE, Sandler HM, Muraszko KM: Myxopapillary ependymoma. Results of nucleolar organizing region staining. **Cancer** **71**:3114–3118, 1993
  12. Sommeland PR, Scheithauer BW, Onofrio BM: Myxopapillary ependymoma. A clinicopathologic and immunocytochemical study of 77 cases. **Cancer** **56**:883–893, 1985
  13. Tomita T: Ependymomas, in McClone DG (ed): **Pediatric Neurosurgery: Surgery of the Developing Nervous System, ed 4**. Philadelphia: WB Saunders, 2001, pp 822–834
  14. Woesler B, Moskopp D, Kuchelmeister K, Schul C, Wassmann H: Intracranial metastasis of a spinal myxopapillary ependymoma. A case report. **Neurosurg Rev** **21**:62–65, 1998

---

Manuscript received December 22, 2003.

Accepted in final form June 15, 2004.

*Address reprint requests to:* John Kestle, M.D., Division of Pediatric Neurosurgery, University of Utah, Primary Children’s Medical Center, 100 North Medical Drive, Suite 2400, Salt Lake City, Utah 84113. email: john.kestle@hsc.utah.edu.