

## Surgical management of aneurysmal bone cysts of the spine

JAMES K. LIU, M.D., DOUGLAS L. BROCKMEYER, M.D., ANDREW T. DAILEY, M.D.,  
AND MEIC H. SCHMIDT, M.D.

*Department of Neurosurgery, University of Utah School of Medicine, Primary Children's Medical Center, Salt Lake City, Utah; and Department of Neurosurgery, Harborview Medical Center, University of Washington, Seattle, Washington*

**Object.** Aneurysmal bone cysts of the spine are benign, highly vascular osseous lesions of unknown origin that may present difficult diagnostic and therapeutic challenges. They are expansile lesions containing thin-walled, blood-filled cystic cavities that cause bone destruction and sometimes spinal deformity and neurological compromise. The treatment of aneurysmal bone cysts of the spine remains controversial according to the literature. In this review, the authors discuss the clinical manifestations, pathophysiological features, neuroimaging characteristics, and treatment strategies for these lesions.

**Methods.** Treatment options include simple curettage with bone grafting, complete excision, embolization, and radiation therapy. Reconstruction and stabilization of the spine may be warranted if deformity and instability are present. Special factors need to be considered in the management of these lesions.

**Conclusions.** Complete excision of aneurysmal bone cysts offers the best chance of cure and spinal decompression if neurological deficits are present.

**KEY WORDS** • aneurysmal bone cyst • spine tumor • spinal fusion • embolization

Aneurysmal bone cysts were initially described as a distinct clinicopathological entity by Jaffe and Lichtenstein<sup>27</sup> in 1942. Although these lesions are generally regarded as nonneoplastic in nature, they are expansile tumors containing thin-walled, blood-filled cystic cavities, and they frequently affect the pediatric population. Aneurysmal bone cysts comprise approximately 1.4% of all bone tumors and 15% of all primary spine tumors.<sup>1,13</sup> Although they can involve any bone in the skeleton, aneurysmal bone cysts most frequently affect the flat bones of the pelvis and the metaphysis of long bones. Approximately 10 to 30% of cases involve the spine, most commonly in the thoracic and lumbar regions.<sup>1,2,5,15,26,40,43</sup> In these cases, the lesions generally arise in the posterior elements of the spine and can expand and extend into the pedicles, VB, and spinal canal, resulting in pathological fracture and neurological compromise. A progressive neurological deficit with acute paraplegia can occur. On rare occasions, some of these bone cysts become quiescent or undergo spontaneous regression. The unique location of this lesion in the spine presents several challenges in its surgical management.<sup>56</sup>

---

*Abbreviations used in this paper:* CT = computerized tomography; MR = magnetic resonance; VB = vertebral body.

### OVERVIEW

#### *Clinical Features of Aneurysmal Bone Cysts*

Aneurysmal bone cysts primarily affect individuals who are between 10 and 20 years of age, with a slight preponderance of females.<sup>2,15,43</sup> The mean age at diagnosis varied from 14 to 16 years in several large studies.<sup>15,41,43,57</sup>

The thoracic (32%) and lumbar (34%) vertebrae are the most common sites for spinal aneurysmal bone cysts.<sup>1,2,5,15,26,40,43</sup> The posterior elements and the pedicles are usually affected first, and in 60 to 70% of cases the lesion extends into the VB. Continued expansion and bone destruction of the VB can ultimately lead to sudden collapse or angular deformity of the vertebral column and acute epidural compression of the spinal cord. In approximately 25 to 35% of cases, the lesion crosses over to an adjacent vertebra through surrounding soft tissues, but never through the intervertebral disc.<sup>2,41</sup> Associated scoliosis and kyphosis are also present in 10 to 15% of patients.<sup>43,56</sup>

The duration of symptoms prior to diagnosis is usually 4 to 8 months.<sup>41</sup> Local pain is the most common feature of this disease, and is often worse at night and with recumbency. This can be associated with swelling or a palpable mass that is often tender to the touch. Posterior masses are usually paravertebral, and anterior masses can sometimes mimic thyroid neoplasms. Neurological symptoms can be

the initial presentation in 60 to 70% of cases. Early nerve root compression can cause paresthesias and radicular pain that can be referred to the chest wall, abdomen, or extremities. Epidural spinal cord compression by a rapidly expanding lesion or by VB collapse and kyphotic deformity can result in myelopathy, or sometimes acute paraparesis.<sup>42,46,47</sup> Acute spinal cord compression can occur in the absence of VB collapse if there is a break in the posterior cortex of the body that results in epidural extension of the lesion.<sup>7</sup> Rapid deterioration to complete paraplegia may occur if lesions are left untreated. Varying degrees of scoliosis may be caused by painful muscular spasm or wedge destruction of one half of the VB.<sup>2</sup>

Although aneurysmal bone cysts are benign, nonneoplastic lesions with no propensity to metastasize, their potential for rapid growth, considerable destruction of bone, and neurological involvement has led to aggressive therapy, despite reports of spontaneous regression or regression following simple biopsy sampling of the lesion.<sup>49,51</sup> Such regression appears to be a rare phenomenon, perhaps related to thrombosis and fibrosis of the aneurysmal bone cyst.<sup>56</sup>

### Pathogenesis of Lesions

The exact pathogenesis of aneurysmal bone cysts remains unknown. Some authors have suggested that the lesion is preceded by traumatic fractures or subperiosteal hematoma.<sup>12,43</sup> Others have suggested that the formation of aneurysmal bone cysts is the result of a reparative process. Although several theories have been postulated, these cysts are generally thought of as a secondary vascular phenomenon superimposed on a preexisting lesion, which presumably initiates a periosteal or intraosseous arteriovenous malformation.<sup>1,3,20,27,31,32</sup> The resultant hemodynamic forces generated by high-pressure vascular channels rapidly erode the osseous trabeculae into a cystic cavity. The associated reactive changes within the endosteum and periosteum incite accelerated osteoblastic and osteoclastic activities, which then rapidly remodel the bone while conforming to the hemodynamic forces, giving the lesion a ballooned, thin-shelled, and multiseptated soap-bubble appearance.<sup>1,32,41</sup>

The concept of aneurysmal bone cysts as a secondary phenomena occurring in a preexisting lesion is based on the fact that in approximately 20 to 30% of cases, an aneurysmal bone cyst is associated with an underlying skeletal lesion.<sup>15,30,34</sup> Some refer to these as secondary aneurysmal bone cysts: preexisting lesions have included giant cell tumor, osteoblastoma, hemangioma, chondroblastoma, nonossifying fibroma, chondromyxoid fibroma, fibrous dysplasia, telangiectatic osteosarcoma, and brown tumor of primary hyperparathyroidism.<sup>4</sup> Nevertheless, in most aneurysmal bone cysts, an underlying lesion is not encountered. This might be the result of sampling error or it could mean that the aneurysmal bone cyst destroyed all evidence of the preexisting lesion. It appears that primary aneurysmal bone cyst is an entity in itself, with unique clinical, neuroimaging, and prognostic behavior. The diagnosis of primary aneurysmal bone cyst should therefore be made when all other underlying lesions can be excluded.<sup>4</sup>

Serial neuroimaging and histopathological correlative

studies have been used to identify four stages in the natural history of aneurysmal bone cysts that may explain their pathogenesis.<sup>23,26,41,57</sup> The initial stage is marked by varying degrees of expansion and thinning of the cortical bone, which results in cystic changes. The growth phase is characterized by the expansile, soap-bubble appearance surrounded by progressively thinning eggshell cortex. The third and most dangerous phase involves a sudden, explosive increase in the size of the blood-filled cysts, which causes bone collapse and soft-tissue invasion. This usually marks the beginning of rapid neurological deterioration. In the final healing phase, seen only in some aneurysmal bone cysts, spontaneous ossification and shrinkage of the lesion occur.

### Pathological Characteristics

On gross inspection, aneurysmal bone cysts have a multilocular, spongelike appearance consisting of blood-filled cavities separated by thin, fibrous septa.<sup>2,15</sup> They are expansile lesions that erode and destroy the surrounding bone, leaving an eggshell-thin rim of subperiosteal new bone that is continuous with the adjacent cortex. The core of the tumor consists of soft, fleshy, vascular tissue, in addition to a cystic trabeculation of the interior of the mass containing unclotted blood; the mass may invade adjacent soft tissue or surround the thecal sac. Bleeding appears to come from the soft tissue lining the cysts and may be profuse and difficult to control until all the lining has been removed.<sup>26</sup>

Histologically, the fibrous septa of aneurysmal bone cysts are made of fibroblasts, myofibroblasts, multinucleated osteoclast-like giant cells, hemosiderin deposits, blood vessels, and fields of osteoid and woven bone (Fig. 1).<sup>1,2,13</sup> The cavernous, blood-filled cysts are not true vascular channels because they lack an endothelial lining and the elastic tissue or smooth muscle that is found in the walls of normal blood vessels. Mitosis may be observed, which indicates proliferative activity. Aneurysmal bone cysts may expand by enlargement of the cavities or by proliferation of the basic tissue. The tumor has a well-dif-

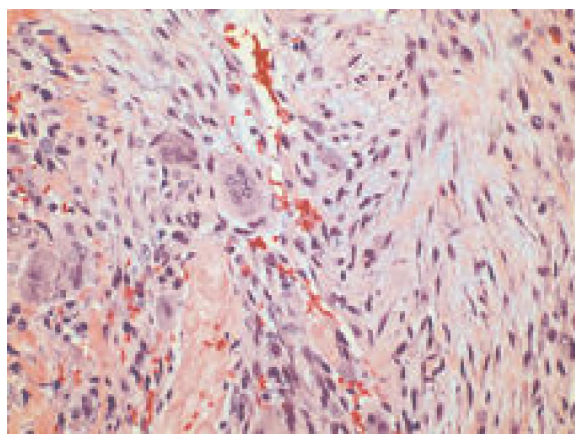


Fig. 1. Photomicrograph of tissue obtained at pathological examination showing fibroblasts and several multinucleated giant cells. There are variably sized, blood-filled cystic spaces in some areas of the lesion. H & E, original magnification  $\times 400$ .

## Aneurysmal bone cysts of the spine

differentiated, benign histological features, but can behave aggressively by invading into adjacent vertebrae and surrounding soft tissues, causing neurological compromise.<sup>26,56</sup>

### Neuroimaging Characteristics

Neuroimaging studies usually reveal a characteristic lytic lesion and “ballooning” or expansion of bone with erosion and destruction of the cortex. A blown-out, egg-shell-thin layer of cortical or periosteal bone formation is usually present.<sup>1,15,53</sup> Pathological fracture with partial collapse of the VB is common; this may occasionally progress to complete collapse (*vertebra plana*).<sup>42</sup>

Preoperative CT scans are better for defining the location and extent of bone destruction and the integrity of the cortical bone, and for detecting calcium deposits (Fig. 2 *left*).<sup>7</sup> Sometimes, communicating cavities with fluid–fluid interfaces can be demonstrated. The CT modality is also useful for evaluating the pedicles and VBs to aid surgical planning for an instrumented fusion.

The MR imaging modality provides the most optimal evaluation and delineation of the contents of and the full extent of bone and soft-tissue involvement by the aneurysmal bone cyst (Fig. 3A and B). The degree of compression of neural elements is also better visualized.<sup>7,43</sup> In cases in which the aneurysmal bone cyst extends through the paravertebral soft tissues to involve adjacent vertebrae, the intervertebral discs are intact and not involved by the lesion.<sup>15,41</sup>

Aneurysmal bone cysts have a heterogeneous appearance on both T<sub>1</sub>- and T<sub>2</sub>-weighted MR images. The presence of multifoculated cysts containing fluid–fluid interfaces on T<sub>2</sub>-weighted images is very characteristic and highly suggestive of the diagnosis of aneurysmal bone cyst (Fig. 3A and B). The hypointense component is on the dependent portion of the fluid level within the cyst and the hyperintense component is on the nondependent side.

Because these cysts contain blood from different stages of their evolution, the darker dependent portions of the cyst likely represent sediments of cellular and proteinaceous elements of unclotted blood.<sup>7</sup> Although the presence of fluid–fluid interfaces is highly suggestive of the diagnosis of aneurysmal bone cyst, they have also been described in telangiectatic osteosarcoma, unicameral bone cyst, chondroblastoma, giant cell tumor, and osteoblastoma. To differentiate aneurysmal bone cyst from other masses containing fluid–fluid interfaces, administration of intravenous Gd demonstrates smooth enhancement of the internal septations within aneurysmal bone cysts. Theoretically, the septations in aneurysmal bone cysts are thin and smooth, whereas those in other masses, most of them neoplastic in nature, would be nodular.<sup>6</sup> The hypervascularity of the complex septa network accounts for the soap-bubble appearance of the lesion on enhanced MR images.

Radioisotope bone scans can show increased uptake in some cases.<sup>15</sup> Selective angiography can sometimes delineate the blood supply to the hypervascular lesion, along with pathological circulation and occasional arteriovenous shunts.<sup>1</sup> Identification of arterial feeding vessels to the lesion may be useful for preoperative embolization. Visualization of the lesion can also be performed by direct percutaneous injection of a radiopaque substance into the aneurysmal bone cyst (Fig. 2 *center*). This is usually done in conjunction with percutaneous embolization procedures.

### Differential Diagnosis

Aneurysmal bone cysts of the spine must be differentiated from giant cell tumor, hemangioma, fibrous dysplasia, osteosarcoma, and metastatic lesions. Giant cell tumor is uncommon in patients younger than 20 years of age, and it occurs mostly in the sacrum. Unlike in aneurysmal bone cysts, there are no cavernous vascular spaces. On pathological examination, the giant cells are bigger and more numerous in giant cell tumor. Vertebral hemangioma

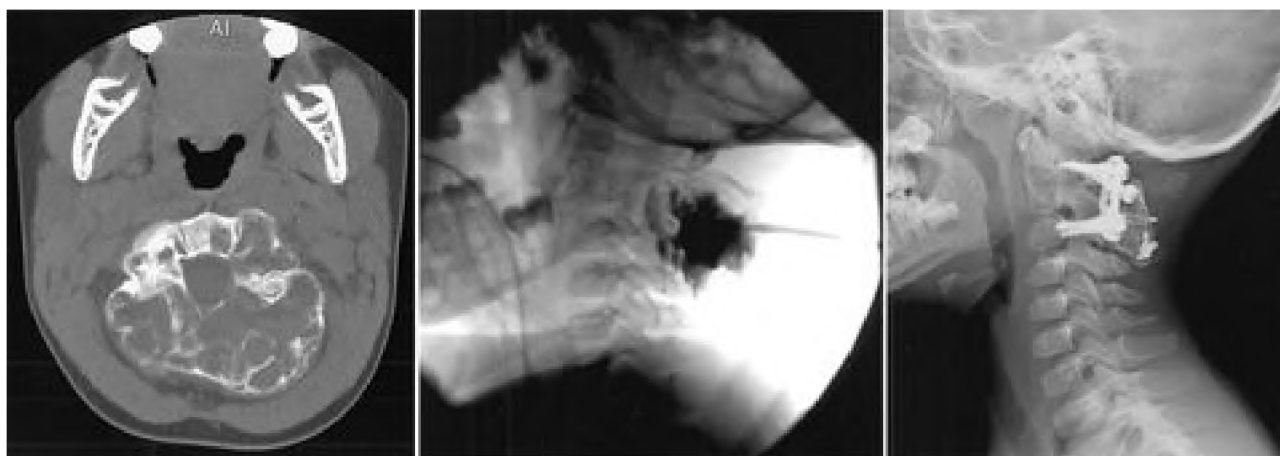


Fig. 2. Neuroimages obtained in a 3-year-old girl who presented with a posterior neck mass associated with neck pain from an aneurysmal bone cyst at C-2. *Left*: Axial CT scan demonstrating a large, multicystic and expansile lesion of C-2, which replaced the posterior elements including the pedicles and left aspect of the VB. The odontoid process was normal. *Center*: Preoperative percutaneous embolization was performed. This angiogram obtained after injection of contrast material demonstrates filling of the multicystic lesion. *Right*: Plain x-ray film obtained after a C-2 laminectomy with resection of the aneurysmal bone cyst was performed, followed by an instrumented C1–3 fusion with rib allograft.

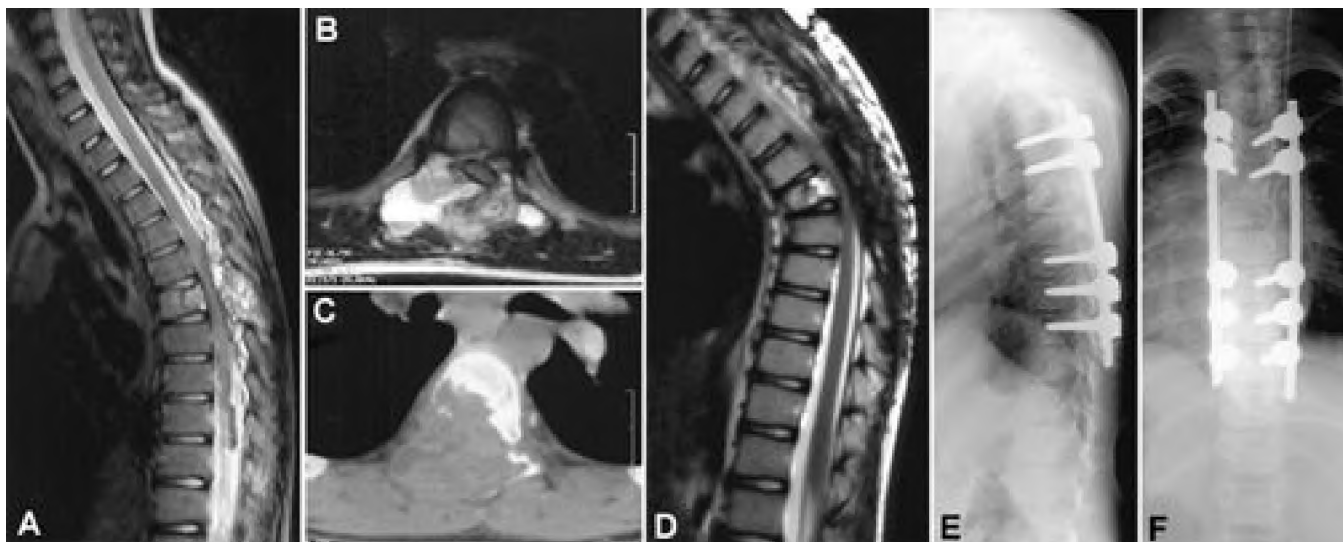


Fig. 3. Neuroimages obtained in a 7-year-old girl who presented with back pain, abdominal pain, and myelopathy from a T-6 aneurysmal bone cyst. A and B: Sagittal (A) and axial (B) T<sub>2</sub>-weighted MR images demonstrating the characteristic heterogeneous, soap-bubble appearance of aneurysmal bone cysts with multiple fluid–fluid levels. There is spinal cord compression from epidural expansion of the mass. C: Axial CT scan revealing extensive bone destruction of the posterior elements, the right pedicle, and VB. The patient underwent gross-total resection of the aneurysmal bone cyst via a posterior transpedicular approach. Postoperatively, the patient was placed in an external orthosis and followed closely with serial imaging. D: Sagittal T<sub>2</sub>-weighted MR image obtained 2 months postresection demonstrating marked kyphotic deformity with spinal cord compression. The patient experienced increased back pain and mild lower-extremity weakness, and therefore underwent spinal reconstruction and stabilization with thoracic pedicle screws and rods and an interbody rib allograft at T-6. E and F: Postoperative plain x-ray films of the spinal construct, lateral view (E) and anteroposterior view (F). The patient achieved a full recovery of motor function and was able to walk.

is differentiated by its characteristic trabeculated, honeycomb appearance on CT scans. It usually involves only one VB and does not expand and balloon out like an aneurysmal bone cyst. Fibrous dysplasia of the vertebra affects the same age group as aneurysmal bone cysts, usually includes more than one vertebra, grows slowly until the patient's skeletal growth ceases, and is often painless. Osteosarcoma and metastatic lesions, on the other hand, are painful tumors found in older patients, and do not produce bone expansion and ballooning.<sup>1</sup>

### TREATMENT STRATEGIES

Treatment options for aneurysmal bone cysts have included simple curettage with or without bone grafting, complete excision, embolization, radiation therapy, or a combination of these modalities.<sup>9,56,59</sup> The optimal treatment of aneurysmal bone cysts of the spine, however, remains a subject of controversy in the literature. Because of their unique anatomical structure and function, there are special considerations when managing aneurysmal bone cysts of the spine. One must take into account the age of the patient, the surgical accessibility of the lesion, necessity to minimize intraoperative blood loss, the presence of neurological compression, the presence of a pathological fracture and deformity, and potential postoperative instability after complete resection.<sup>2,41,43,56</sup>

The use of preoperative embolization has been reported to reduce intraoperative blood loss.<sup>16,18</sup> Adjuvant radiotherapy appears to have no significant advantage over sur-

gical treatment alone and may carry an increased risk of malignant transformation.<sup>5,26</sup> Excision, radiation therapy, and selective arterial embolization have been used successfully, alone or in combination. The clinical course of aneurysmal bone cysts is sometimes unpredictable and local recurrences have been described after various types of treatments.<sup>2</sup> Wide excision appears to yield the highest rate of cure; however, aggressive surgery may render the spine unstable. Complete resection followed by spinal stabilization appears to be the optimal method of acquiring a high degree of local control and preventing or correcting spinal deformity and instability (Figs. 2 *right* and 3E and F).<sup>40,43,56</sup> There appears to be little justification for needle biopsy sampling: the results are likely to be negative, and the procedure carries a potential risk of incurring an epidural hematoma.

### Surgical Management

**Curettage.** Although curettage and bone grafting have been reported to be successful in the management of aneurysmal bone cysts in the long bones of the extremities,<sup>9,50,59</sup> the same does not apply to lesions of the spine. In a study by Ozaki, et al.,<sup>40</sup> nine patients who underwent complete excision did not suffer a local recurrence, whereas two who underwent curettage alone experienced local recurrences. Curettage has approximately a 19% recurrence rate, usually within the first 2 years posttreatment.<sup>59</sup>

**Complete Excision.** Complete resection is the treatment of choice with aneurysmal bone cysts of the spine, especially in patients who present with a neurological deficit.

## Aneurysmal bone cysts of the spine

Total excision, en bloc if possible, provides the highest rate of cure, with an excellent prognosis.<sup>1,2,40,43,56</sup> Subtotal excision is associated with a high incidence of recurrence, which is seen within 6 to 12 months. Hay, et al.,<sup>26</sup> reported no recurrences after total excision and a 25% recurrence rate for partial excision. The growth of aneurysmal bone cysts is sometimes characterized by rapid enlargement and bone destruction, with occasional neurological compromise from spinal cord compression or instability.<sup>43</sup> Early surgical intervention with total excision of all affected bone is recommended for immediate decompression.<sup>46</sup> In cases of pathological and impending fractures, surgery followed by spinal reconstruction and stabilization provides correction of the deformity.

Total excision must include the entire cyst wall, all abnormal tissues that feel spongy, and bone surfaces that are lined with fragile and hypervascular membranes.<sup>1,5,11,15,25,35,38,41,43,44,56,57</sup> Excision must include the entire cyst wall because partial excision is related to a higher risk of recurrence.<sup>2</sup> Intraoperative bleeding generally subsides when this layer is removed. Aggressive curettage using a high-speed drill is often used to cut back to healthy, well-mineralized bone. For large and extensive lesions, complete resection will likely cause iatrogenic instability requiring instrumented fusion (Figs. 2 *right* and 3E and F).<sup>41</sup>

The surgical approach depends on the location and extent of the lesion. Because the posterior elements are almost always involved, a posterior approach should be considered initially. With a posterior exposure, any tumor involvement of the pedicles with extension into the anterolateral aspect of the VB is surgically accessible with a unilateral or bilateral transpedicular approach. If there is extensive anterior VB involvement and resection and decompression from a posterior approach is inadequate, then a separate anterior approach should be used, either in the same operation or at a later date.<sup>35,38,41</sup>

**Reconstruction and Stabilization.** Extensive bone destruction can involve multiple contiguous levels and result in loss of structural stability. Collapse of the VB can produce kyphotic deformity and resultant neurological compromise. Extensive tumor resection can also result in postoperative iatrogenic instability. If instability and/or deformity already exists, or if the amount of bone resection is expected to result in instability, then simultaneous reconstruction and instrumented stabilization should be planned (Fig. 2 *right*).<sup>5,11,35,38,40,41,44,56,57</sup> This strategy of preplanned spinal stabilization allows the surgeon to perform an aggressive resection that yields a high degree of local control.

Posterior instrumentation with lateral mass screws (cervical spine), pedicle screws (thoracic and lumbar spine), or hooks and rods can be effectively performed after posterior resection. If a combined anterior vertebrectomy is performed, the anterior column needs to be reconstructed with an interbody graft and plating (anterior cervical locking plate in the cervical spine; lateral interbody plate in the thoracolumbar spine).<sup>52,58</sup> We recommend bone grafting in the resection bed to promote fusion and to buttress the stability of the involved segments. Alternatively, interbody cages packed with bone can be used to reconstruct the anterior vertebral column.

Spinal stabilization should be considered after resection

of lesions involving the cervicothoracic or thoracolumbar junctions because of the tendency for postlaminectomy kyphosis, especially in children.<sup>43</sup> In cases in which postoperative instability is not obvious, we recommend a trial of external bracing with close radiographic follow up. This is a reasonable alternative to instrumented fusion for children who have not reached skeletal maturity. If postoperative deformity develops, however, surgical stabilization is indicated (Fig. 3E and F).

### Nonsurgical Management

**Embolization.** The main goal of selective arterial embolization in the management of aneurysmal bone cysts is to decrease vascularity and reduce intraoperative blood loss as a preoperative adjunct.<sup>8,14,16,19,23,29</sup> Although successful treatment with embolization alone has been reported for aneurysmal bone cysts of the pelvis and long bones,<sup>10,17,36,37,45,60</sup> its use as the sole mode of therapy has very limited applications in the spine, especially in the setting of pathological fracture and neurological involvement. In patients who present with spinal canal compromise and neurological deficit, immediate surgical decompression is warranted and the time required for embolization may delay surgery.<sup>43</sup>

Embolization may be considered as the primary therapy in patients with a recurrent lesion after previous surgeries or in patients who cannot tolerate surgery, but only if pathological fracture, spinal deformity, instability, and neurological compromise are absent. The long-term effect of embolization results in involution of the soft-tissue component, sclerosis, and ossification. This mineralization usually becomes apparent after 3 months to 2 years, and some authors have reported pain reduction and tumor shrinkage.<sup>14,16,29,60</sup> There are few reports of involution and diffuse ossification of the lesion, which would obviate any further surgery.<sup>29</sup> Presumably, the occlusion of feeding arteries dampens the hemodynamic forces that underlie the destructive bone remodeling and promotes spontaneous reossification. Reappearance of foci of bone rarefaction or cystic changes has been reported later than 2 years after embolization; thus, continued surveillance is recommended.

Medium-sized particles (250–350  $\mu\text{m}$ ) of polyvinyl alcohol are most often used as the embolic agent, because smaller particles might behave more like liquid agents and have a higher risk of causing ischemic complications to the spinal cord.<sup>29</sup> Once the feeding arteries are identified, a test occlusion is usually performed by injecting sodium amylal into the feeding vessels of the awake patient. If no neurological deficit is elicited, the embolic agent is injected into the feeding vessels with somatosensory evoked potential monitoring. After embolization, patients should be carefully monitored because of concerns for potential swelling that may result in spinal cord compression. Resection should be performed within 2 to 3 days after embolization, before collateralization of new blood vessels occurs.<sup>23</sup>

Occasionally, there are no identifiable arterial feeding vessels suitable for selective embolization. An alternative strategy is direct percutaneous embolization by entering the cyst with a needle under fluoroscopic or CT guidance (Fig. 2 *center*).<sup>22,24</sup> Injection of the cyst with a sclerosing

solution has been used to induce involution of the lesion. Guibaud, et al.,<sup>24</sup> used an alcohol solution of corn protein (alcoholic zein) that induces intravascular thrombosis, marked local inflammation, and an ensuing fibrogenic reaction that triggers the reparative process of mineralization and bone reconstruction. They reported complete improvement in 87% of cases and partial healing in 13%, with a 5% incidence of serious complications.

**Radiation Therapy.** There is controversy regarding the role of radiation therapy. Although some authors have reported favorable results with radiation as the primary treatment,<sup>28,39</sup> this modality should not be the first line of treatment for spinal aneurysmal bone cysts. Capanna, et al.,<sup>5</sup> suggested that there was no benefit from the addition of radiation to curettage or to partial resection and curettage. Patients who received radiation in their series had poor outcomes: a delayed pathological fracture and kyphotic deformity developed in one; complications of cystitis, septicemia, and endocarditis in another; and a third experienced progression of disease that extended to adjacent levels resulting in quadriplegia. Radiation therapy does not treat pathological fracture, spinal deformity, instability, and neurological compromise.

Some opponents of its use argue that the risks of radiation therapy are not justified, given the benign behavior of aneurysmal bone cysts and the high rate of cure with complete excision.<sup>2,40,54</sup> The complications of radiation therapy include postradiation myelopathy, radiation-induced sarcoma, and possible growth disturbance in children.<sup>21,32,33,43,48,54,55,57,59</sup> Papagelopoulos, et al.,<sup>43</sup> reported on one case of postradiation osteosarcoma that occurred at the same site 7 years later, which resulted in death.

Indications for radiation therapy are limited, and it remains an adjuvant therapy for patients with inoperable lesions, aggressive recurrent disease, or medical conditions that place them at high risk during surgery. Some authors believe that embolization therapy should be attempted before the use of radiation therapy.<sup>14,16</sup>

### Recurrences of Lesions

When referring to aneurysmal bone cysts, recurrence is better defined as continued progression of residual disease left behind by incomplete treatment rather than regrowth of lesions, as in the context of neoplasia.<sup>2,41</sup> The rate of local recurrence after resection is related to the complete or incomplete removal of the lesion, including the cyst wall. In general, incomplete excision is associated with a relatively high recurrence rate and complete excision of the lesion is associated with a high cure rate.<sup>5,26,59</sup> Incomplete excision of aneurysmal bone cysts entails a 50 to 60% rate of disease progression;<sup>41</sup> 90% of the recurrences appear within 6 to 12 months after incomplete excision.<sup>2,43</sup> Patients should be monitored closely with follow-up imaging. Radiographic evidence of cure is manifested by shrinking of the lesion and reossification of the cystic areas. Recurrence of an aneurysmal bone cyst is unusual after 2 years and rare after 4 years.<sup>55</sup>

### CONCLUSIONS

The surgical management of aneurysmal bone cysts of the spine remains a challenge. Complete excision of the

lesion offers the best chance of cure and neurological decompression, if deficits are present. Preoperative embolization may be useful for reducing intraoperative blood loss. Deformity and instability, whether preexisting or postoperative, need to be corrected with reconstruction and stabilization techniques.

### References

1. Ameli NO, Abbassioun K, Saleh H, et al: Aneurysmal bone cyst of the spine. Report of 17 cases. *J Neurosurg* **63**:685–690, 1985
2. Boriani S, De Iure F, Campanacci L, et al: Aneurysmal bone cyst of the mobile spine: report on 41 cases. *Spine* **26**:27–35, 2001
3. Buraczewski J, Dabska M: Pathogenesis of aneurysmal bone cyst. Relationship between the aneurysmal bone cyst and fibrous dysplasia of bone. *Cancer* **28**:597–604, 1971
4. Campanacci M, Capanna R, Picci P: Unicameral and aneurysmal bone cysts. *Clin Orthop* **204**:25–36, 1986
5. Capanna R, Albinini U, Picci P, et al: Aneurysmal bone cyst of the spine. *J Bone Joint Surg Am* **67**:527–531, 1985
6. Caro PA, Mandell GA, Stanton RP: Aneurysmal bone cyst of the spine in children. MRI imaging at 0.5 tesla. *Pediatr Radiol* **21**:114–116, 1991
7. Chan MS, Wong YC, Yuen MK, et al: Spinal aneurysmal bone cyst causing acute cord compression without vertebral collapse: CT and MRI findings. *Pediatr Radiol* **32**:601–604, 2002
8. Chuang VP, Soo CS, Wallace S, et al: Arterial occlusion: management of giant cell tumor and aneurysmal bone cyst. *AJR* **136**:1127–1130, 1981
9. Clough JR, Price CH: Aneurysmal bone cyst: pathogenesis and long term results of treatment. *Clin Orthop* **97**:52–63, 1973
10. Cory DA, Fritsch SA, Cohen MD, et al: Aneurysmal bone cysts: imaging findings and embolotherapy. *AJR* **153**:369–373, 1989
11. Cybulski GR, Anson J, Gleason T, et al: Aneurysmal bone cyst of the thoracic spine: treatment by excision and segmental stabilization with Luque rods. *Neurosurgery* **24**:273–276, 1989
12. Dabezies EJ, D'Ambrosia RD, Chuinard RG, et al: Aneurysmal bone cyst after fracture. A report of three cases. *J Bone Joint Surg Am* **64**:617–621, 1982
13. Dahlin DC, McLeod RA: Aneurysmal bone cyst and other non-neoplastic conditions. *Skeletal Radiol* **8**:243–250, 1982
14. De Cristofaro R, Biagini R, Boriani S, et al: Selective arterial embolization in the treatment of aneurysmal bone cyst and angioma of bone. *Skeletal Radiol* **21**:523–527, 1992
15. de Kleuver M, van der Heul RO, Veraart BE: Aneurysmal bone cyst of the spine: 31 cases and the importance of the surgical approach. *J Pediatr Orthop B* **7**:286–292, 1998
16. DeRosa GP, Graziano GP, Scott J: Arterial embolization of aneurysmal bone cyst of the lumbar spine. A report of two cases. *J Bone Joint Surg Am* **72**:777–780, 1990
17. DiCaprio MR, Murphy MJ, Camp RL: Aneurysmal bone cyst of the spine with familial incidence. *Spine* **25**:1589–1592, 2000
18. Dick HM, Bigliani LU, Michelsen WJ, et al: Adjuvant arterial embolization in the treatment of benign primary bone tumors in children. *Clin Orthop* **139**:133–141, 1979
19. Disch SP, Grubb RL Jr, Gado MH, et al: Aneurysmal bone cyst of the cervicothoracic spine: computed tomographic evaluation of the value of preoperative embolization. Case report. *Neurosurgery* **19**:290–293, 1986
20. Edling NP: Is the aneurysmal bone cyst a true pathologic entity? *Cancer* **18**:1127–1130, 1965
21. Frassica FJ, Frassica DA, Wold LE, et al: Postradiation sarcoma of bone. *Orthopedics* **16**:105–106, 1993
22. Gladden ML Jr, Gillingham BL, Hennrikus W, et al: Aneurysmal bone cyst of the first cervical vertebrae in a child

## Aneurysmal bone cysts of the spine

- treated with percutaneous intralesional injection of calcitonin and methylprednisolone. A case report. **Spine** **25**:527–531, 2000
23. Green JA, Bellemore MC, Marsden FW: Embolization in the treatment of aneurysmal bone cysts. **J Pediatr Orthop** **17**: 440–443, 1997
  24. Guibaud L, Herbreteau D, Dubois J, et al: Aneurysmal bone cysts: percutaneous embolization with an alcoholic solution of zein—series of 18 cases. **Radiology** **208**:369–373, 1998
  25. Gupta VK, Gupta SK, Khosla VK, et al: Aneurysmal bone cysts of the spine. **Surg Neurol** **42**:428–432, 1994
  26. Hay MC, Paterson D, Taylor TK: Aneurysmal bone cysts of the spine. **J Bone Joint Surg Br** **60**:406–411, 1978
  27. Jaffe HL, Lichtenstein L: Solitary unicameral bone cyst with emphasis on the roentgen picture, the pathologic appearance and the pathogenesis. **Arch Surg** **44**:1004–1025, 1942
  28. Kamikonya N, Hishikawa Y, Kurisu K, et al: Aneurysmal bone cyst treated by high-energy, low-dose radiation therapy: a case report. **Radiat Med** **9**:54–56, 1991
  29. Koci TM, Mehringer CM, Yamagata N, et al: Aneurysmal bone cyst of the thoracic spine: evolution after particulate embolization. **AJNR** **16** (Suppl 4):857–860, 1995
  30. Kransdorf MJ, Sweet DE: Aneurysmal bone cyst: concept, controversy, clinical presentation, and imaging. **AJR** **164**: 573–580, 1995
  31. Levy WM, Miller AS, Bonakdarpour A, et al: Aneurysmal bone cyst secondary to other osseous lesions. Report of 57 cases. **Am J Clin Pathol** **63**:1–8, 1975
  32. Lichtenstein L: Aneurysmal bone cyst: observations on fifty cases. **J Bone Joint Surg Am** **39**:873–882, 1957
  33. MacCarty CS, Dahlin DC, Doyle JB Jr, et al: Aneurysmal bone cysts of the neural axis. **J Neurosurg** **18**:671–677, 1961
  34. Martinez V, Sissons HA: Aneurysmal bone cyst. A review of 123 cases including primary lesions and those secondary to other bone pathology. **Cancer** **61**:2291–2304, 1988
  35. Mehdian H, Weatherley C: Combined anterior and posterior resection and spinal stabilization for aneurysmal bone cyst. **Eur Spine** **4**:123–125, 1995
  36. Misasi N, Sadile F: Selective arterial embolization in orthopaedic pathology. Analysis of long-term results. **Chir Organi Mov** **76**:311–316, 1991
  37. Murphy WA, Strecker WB, Schoenecker PL: Transcatheter embolization therapy of an ischial aneurysmal bone cyst. **J Bone Joint Surg Br** **64**:166–168, 1982
  38. Nicastro JF, Leatherman KD: Two-stage resection and spinal stabilization for aneurysmal bone cyst. A report of two cases. **Clin Orthop** **180**:173–178, 1983
  39. Nobler MP, Higinbotham NL, Phillips RF: The cure of aneurysmal bone cyst. Irradiation superior to surgery in an analysis of 33 cases. **Radiology** **90**:1185–1192, 1968
  40. Ozaki T, Halm H, Hillmann A, et al: Aneurysmal bone cysts of the spine. **Arch Orthop Trauma Surg** **119**:159–162, 1999
  41. Pang D, Tomita T, Byrd S, et al: A 14-year-old young woman with a five-week history of back pain. **Pediatr Neurosurg** **32**: 100–108, 2000
  42. Papagelopoulos PJ, Currier BL, Galanis EC, et al: Vertebra plana of the lumbar spine caused by an aneurysmal bone cyst: a case report. **Am J Orthop** **28**:119–124, 1999
  43. Papagelopoulos PJ, Currier BL, Shaughnessy WJ, et al: Aneurysmal bone cyst of the spine. Management and outcome. **Spine** **23**:621–628, 1998
  44. Parrish FF, Pevey JK: Surgical management of aneurysmal bone cyst of the vertebral column. **J Bone Joint Surg Am** **49**: 1597–1604, 1967
  45. Radanovic B, Simunic S, Stojanovic J, et al: Therapeutic embolization of aneurysmal bone cyst. **Cardiovasc Intervent Radiol** **12**:313–316, 1989
  46. Raftopoulos C, Hurrell A, Ticket L, et al: Total recuperation in a case of sudden total paraplegia due to aneurysmal bone cyst of the thoracic spine. **Childs Nerv Syst** **10**:464–467, 1994
  47. Rosman MA: Aneurysmal bone cyst of the vertebra with paraplegia. **Can J Surg** **21**:181–183, 1978
  48. Sabanas AO, Dahlin DC, Childs DS Jr, et al: Postradiation sarcoma of bone. **Cancer** **9**:528–542, 1956
  49. Saglik Y, Kapicioglu MI, Guzel B: Spontaneous regression of aneurysmal bone cyst. A case report. **Arch Orthop Trauma Surg** **112**:203–204, 1993
  50. Schreuder HW, Veth RP, Pruszczynski M, et al: Aneurysmal bone cysts treated by curettage, cryotherapy and bone grafting. **J Bone Joint Surg Br** **79**:20–25, 1997
  51. Scott I, Connell DG, Duncan CP: Regression of aneurysmal bone cyst following open biopsy. **Can Assoc Radiol J** **37**: 198–200, 1986
  52. Seifert V, Friedrich H, Oestern R, et al: [Radical surgery and vertebral body replacement of aneurysmal bone cysts of the spine.] **Z Orthop Ihre Grenzgeb** **125**:149–153, 1987 (Ger)
  53. Sherman RS, Soong KY: Aneurysmal bone cyst: its roentgen diagnosis. **Radiology** **68**:54–64, 1957
  54. Sim FH, Cupps RE, Dahlin DC, et al: Postradiation sarcoma of bone. **J Bone Joint Surg Am** **54**:1479–1489, 1972
  55. Tillman BP, Dahlin DC, Lipscomb PR, et al: Aneurysmal bone cyst: an analysis of ninety-five cases. **Mayo Clin Proc** **43**: 478–495, 1968
  56. Turker RJ, Mardjetko S, Lubicky J: Aneurysmal bone cysts of the spine: excision and stabilization. **J Pediatr Orthop** **18**: 209–213, 1998
  57. Vandertop WP, Pruijs JE, Snoeck IN, et al: Aneurysmal bone cyst of the thoracic spine: radical excision with the use of the cavitron. A case report. **J Bone Joint Surg Am** **76**:608–611, 1994
  58. Verbiest H: Giant-cell tumours and aneurysmal bone cysts of the spine. With special reference to the problems related to the removal of a vertebral body. **J Bone Joint Surg Br** **47**: 699–713, 1965
  59. Vergel De Dios AM, Bond JR, Shives TC, et al: Aneurysmal bone cyst. A clinicopathologic study of 238 cases. **Cancer** **69**: 2921–2931, 1992
  60. Wallace S, Granmayeh M, deSantos LA, et al: Arterial occlusion of pelvic bone tumors. **Cancer** **43**:322–328, 1979

Manuscript received September 16, 2003.

Accepted in final form October 10, 2003.

Address reprint requests to: Meic H. Schmidt, M.D., Department of Neurosurgery, University of Utah School of Medicine, 30 North 1900 East, Suite 3B409, Salt Lake City, Utah 84132. email: meic.schmidt@hsc.utah.edu.